

Pericardial Effusion in Langerhans Cell Histiocytosis: A Case Report

Narges Gholami^{1*}

¹Assistant Professor of Pediatrics, Loghman Hakim Hospital, Shahid Beheshti University of Medical Sciences, Tehran, IR Iran

*Corresponding author: Narges Gholami, Assistant Professor of Pediatrics, Loghman Hakim Hospital, Shahid Beheshti University of Medical Sciences, Tehran, IR Iran. Tel: +98-2155419005, Fax: +98-2155417547. E-mail: Nargesgholami724@yahoo.com

Received 2015 March 01; Revised 2015 November 15; Accepted 2016 January 02.

Abstract

Introduction: Langerhans cell histiocytosis (LCH) is a proliferative disorder of histiocytes in multiple organs. Langerhans cell histiocytosis involves bones, skin, lung and other organs.

Case Presentation: This study describes a seven-month-old Iranian girl who presented with skin rash and cervical lymphadenopathy. Langerhans cell histiocytosis was suspected when it was associated with anemia, splenomegaly and lytic bone lesions. A skin biopsy confirmed the diagnosis of Langerhans cell histiocytosis. During hospitalization, the patient looked ill with respiratory distress. A chest X-ray showed a ground glass view, and echocardiography showed moderate pericardial effusion.

Conclusions: Pericardial effusion was a rare finding in this case of Langerhans cell histiocytosis. Pericardial effusion in Langerhans cell histiocytosis, which is an unusual presentation, should be considered when the patient experiences respiratory distress.

Keywords: Histiocytosis, Langerhans Cell, Pericardial Effusion, Infant

1. Introduction

Langerhans cell histiocytosis (LCH) is a rare disorder that involves the clonal proliferation of the Langerhans cells. LCH is often diagnosed in childhood, but any age group can be affected, from infancy through adulthood. The cause of this disease is unknown, although many possibilities have been explored. LCH has a different clinical presentation, because it presents with the involvement of a multi-organ system (1). The initial evaluation consists of a complete physical examination and laboratory studies including complete blood cell (CBC) and skeletal radiographic survey and chest radiography. Biopsies of skin or bone marrow are necessary to diagnose Langerhans cell histiocytosis (2). LCH cells should stain positively with antibodies to CD1a, S100 and/or anti-langerin (CD207) to confirm a diagnosis of LCH. Some articles show that LCH is a diverse disease characterized by a clonal growth of immature Langerhans cells that appear to have mutations of BRAF in about 60% - 75% of cases (3, 4).

The prognosis of LCH depends on the symptoms and involvement of the multiple organ system, organ dysfunction and the patient's response to chemotherapy during the initial six weeks of treatment (4, 5). Complications appear in 30% - 50% of patients with LCH. The most common complications are orthopedic disabilities, hearing impairment, diabetes insipidus, skin scarring and neuropsychological defects. A patient with multisystem disease, craniofacial involvement, longstanding disease or re-

activation may have an increased risk of developing diabetes insipidus. Less common symptoms include chronic pulmonary dysfunction, liver cirrhosis, secondary malignancies such as acute lymphoblastic leukemia or solid tumors and growth retardation. High-risk patients with multiple organ involvement are treated with chemotherapy. Prednisolone and Vinblastine are usually used for them (6).

This study describes a seven-month-old Iranian girl with pericardial effusion as the initial presentation of Langerhans cell histiocytosis.

2. Case Presentation

The subject of this case is a seven-month-old Iranian girl from Kashan (a city in Iran) with a five-month history of skin rash who had been treated as an outpatient but whose symptoms had not disappeared. She was first admitted to Kashan hospital, and some laboratory tests had been done there. She received packed red blood cells, because she was anemic. She was referred to and hospitalized in the pediatric department of Loghman Hakim hospital, affiliated with the Shahid Beheshti University of Medical Sciences, Tehran, Iran, on October 8, 2013.

Her history was that she had a maculopapular skin rash and an intermittent fever of five months' duration. Upon physical examination, there was maculopapular skin rash on her scalp, neck, trunk and palmar and plantar surfaces (Figure 1). She also had multiple cervical lymphadenopathy and a palpable spleen. Her weight was

6,300 grams, and her height was 62 cm. Her growth was normal for her age. Her blood pressure was 80/63 mmHg, her heart rate was 120 beats per minute and her axillary temperature was 37.2°C. Several tests were performed during hospitalization. Necessary laboratory tests were done in the Loghman Hakim Hospital Laboratory, and all of the equipment was calibrated. The results are shown in (Tables 1 and 2).

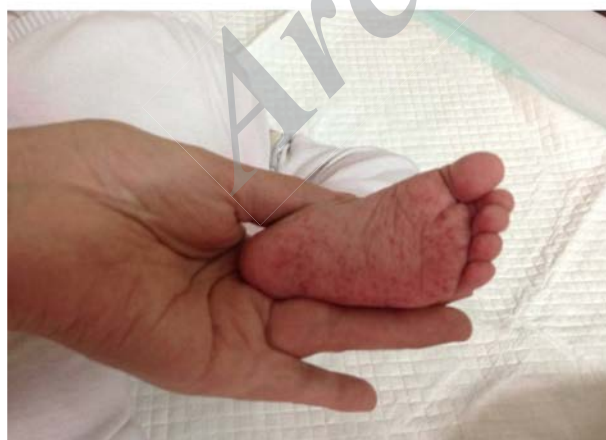
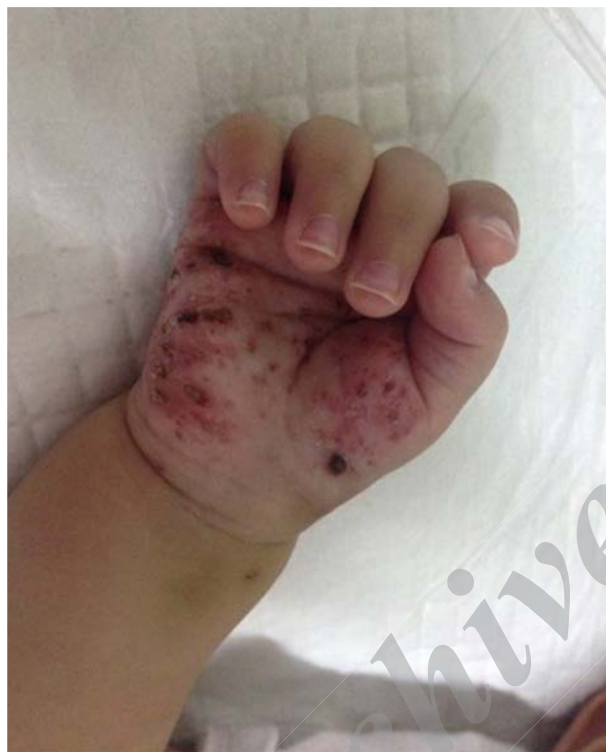
Figure 1. Skin Lesions in Palmar and Plantar Surfaces

A neck ultrasound showed multiple cervical lym-

Table 1. Results of Laboratory Tests

WBC	20,400/mL
Neutrophils, No. (%)	62
Lymphocytes, No. (%)	34
Monocytes, No. (%)	3
Eosinophils, gr/dL	1
HB, fl	7.1
MCV, No. (%)	74
Retic count	0.9
Fibrinogen, mg/dL	452
Triglyceride, mg/dL	148
Ferritin, mic gr/L	710, NI: 21 - 597

Table 2. Urine Analysis

Parameter	Value
SG	1010
PH	6
WBC	2-3
RBC	1-2
Bacteria	Negative

phadenopathy of 16.4 mm × 6.2 mm size. A skull X-ray showed osteolytic lesions with well-defined margins in the left temporal area (Figure 2). A skin biopsy was done to make certain of the diagnosis. In the skin biopsy, the infiltration of histiocytes and the reniform cell upper dermis were variably positive for S100, compatible with LCH.

During hospitalization, the patient suffered from respiratory symptoms and tachypnea. She also appeared hypoxic and needed a high level of oxygen supplementation (an inspired fraction of O₂ = 5 L/min) to get an O₂ saturation of 95%. Conventional chest radiography (CXR) showed a ground glass view in the upper lobe of the left lung with mediastinal widening; therefore, a chest computed tomography (CT) scan (Toshiba, Japan) was done. It showed a ground glass view and an anterosuperior mediastinal mass with homogeneous density (Figure 3).

According to the patient's symptoms and chest radiographic findings, echocardiography (Vivid 3.USA) was performed for her. Color Doppler echocardiography showed moderate pericardial effusion and poor ventricular function. Other reasons for pericardial effusion were ruled out in this patient. Due to the multiple organ involvement and respiratory distress, chemotherapy was started with Vinblastine, Mercaptopurine and prednisolone, and she toler-

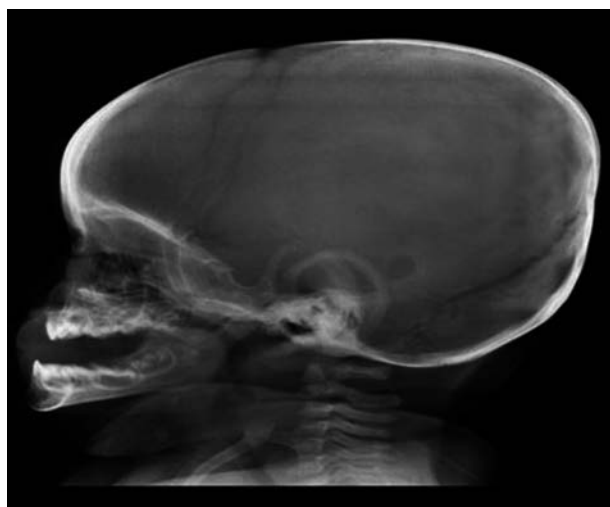


Figure 2. Skull X-Ray Image

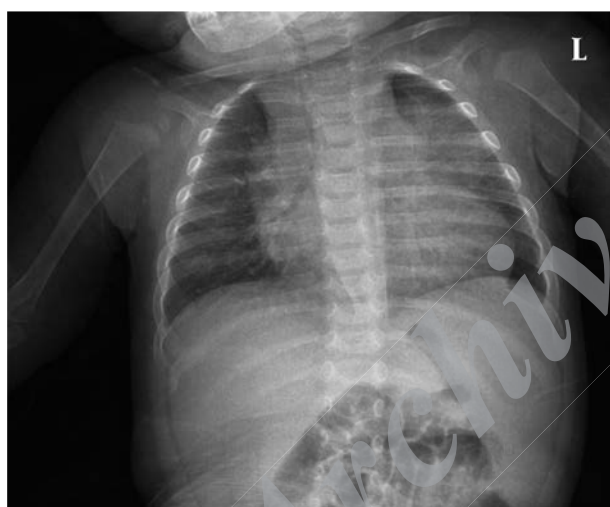

Figure 3. Chest X-Ray Image

ated them very well. Her condition improved, and she was discharged from the hospital after six days. Finally, follow-up showed that her problems were solved, and pericardial effusion was reduced after chemotherapy.

3. Discussion

LCH occurs in 0.70/million children per year and in adolescents from birth to 19 years of age (7). The rate peak is among children aged 5 to 15 (8). LCH is more common in males compared to females (9). LCH can involve a single lesion or multiple organs such as bone, skin, lung,

spleen and liver (5, 10). Bone involvement occurs in approximately 80% of patients with LCH and often occurs in the skull. About 50% of cases manifest cutaneous involvement, and 30% of patients have lymph node involvement (6).

Pericardial effusion is an abnormal accumulation of fluid in the pericardial cavity. Pericardial effusion is rare in children, and it usually does not appear in LCH. Pericardial effusion is an important finding, because it can cause high pressure that adversely affects the heart function, which is called cardiac tamponade. Symptoms in the patient depend on the amount of fluid (11).

Small pericardial effusion is often asymptomatic, and pericardial effusion has been found in 3.4% of the general autopsy population. Moderate to severe pericardial effusion symptoms include dyspnea, tachypnea, cough, a low-grade fever and an increased heart rate. Specific causes of pericardial effusion are viral and bacterial infections, autoimmune disorders, connective tissue disease, metabolic disorders, renal failure, hypothyroidism, malignancy, radiation and chemotherapy treatment. One previously conducted study in patients with pericardial effusion showed that in developed countries, idiopathic pericardial effusion is the most common etiology, but in some underdeveloped countries, tuberculous pericarditis is the leading cause of pericardial effusion (11, 12)

We know that the prognosis for a patient with pericardial effusion will depend on the underlying cause. Oxygen therapy will help to relieve symptoms in patients whose circulation is compromised, and treatment of the underlying condition will help to reduce the volume of fluid in the pericardial sac. Therefore, in this patient, CBC diff, a thyroid function test, a blood culture, a chest X-ray, an ECG and echocardiography were performed, because there was a need to rule out other important diseases that could induce pericardial effusion. Echocardiography is a useful, sensitive, bedside and noninvasive diagnostic tool for detecting pericardial effusion (12).

Another study in the pediatric department of Dr. Ram Manohar Lohia hospital, New Delhi, with significant pericardial effusion from January 2010 to March 2013, showed that tuberculosis (52%) was the most common etiological diagnosis of pericardial effusion, then bacterial (23%), viral (12%), recurrent idiopathic (8%) and malignant (13).

In the literature review, only two previous cases of LCH that reported pericardial effusion were found, and only one of those involved an infant. In 1981, Pickens and Rosen-shein (14) reported a case of a 60-year-old woman who was diagnosed with LCH and pericardial effusion. She had a nonpruritic maculopapular rash on her body and also sub-mandibular masses for several months. A skin biopsy specimen confirmed LCH. In addition, Pickens and Rosenshein detected a large pericardial effusion in their patient. Keelie

(15) described a 16-month-old girl with a cervical mass in the midline of her neck. Although she did not have any respiratory symptoms, a chest X-ray was done which showed a mediastinal mass with cardiomegaly. An echocardiogram showed a large pericardial effusion that confirmed LCH for her.

This case was interesting, because the patient was an infant and LCH and pericardial effusion is very rare in children, yet this study showed pericardial effusion presented in the LCH patient. In this case, pericardiocentesis was not performed, but chemotherapy reduced the pericardial fluid and resolved her symptoms, because the pericardial effusion was created due to LCH. If respiratory distress is observed in LCH patients, the physician should consider pericardial effusion, and a chest X-ray and echocardiography should be performed for them. Patients with LCH should have long-term follow-up care to detect late complications from the disease or the treatment.

Acknowledgments

This patient was admitted to the pediatrics department of the Loghman Hakim hospital of Shahid Beheshti University of Medical Sciences, Tehran, Iran. My thanks and best regards go to the pediatrics department of Loghman Hakim hospital, to Shahid Beheshti University of Medical Sciences, to the parents of my patient and to Dr. Nader Momtazmanesh and Dr. Bidari.

References

1. Agarwal P, Kaushal M. An unusual presentation of Langerhans cell histiocytosis. *J Cytol.* 2014;**31**(4):227-9. doi: [10.4103/0970-9371.151142](https://doi.org/10.4103/0970-9371.151142). [PubMed: [25745295](https://pubmed.ncbi.nlm.nih.gov/25745295/)].
2. Thomas H, Baig A. Multisystem presentation of langerhans cell histiocytosis with severe respiratory distress in child. *Am J Respir Crit Care Med.* 2015;**191**.
3. Mehes G, Irsai G, Bedekovics J, Beke L, Fazakas F, Rozsa T, et al. Activating BRAF V600E mutation in aggressive pediatric Langerhans cell histiocytosis: demonstration by allele-specific PCR/direct sequencing and immunohistochemistry. *Am J Surg Pathol.* 2014;**38**(12):1644-8. doi: [10.1097/PAS.0000000000000304](https://doi.org/10.1097/PAS.0000000000000304). [PubMed: [25118810](https://pubmed.ncbi.nlm.nih.gov/25118810/)].
4. Grana N. Langerhans cell histiocytosis. *Cancer Control.* 2014;**21**(4):328-34. [PubMed: [25310214](https://pubmed.ncbi.nlm.nih.gov/25310214/)].
5. Mehta B, Venkatramani R. Images in clinical medicine. Langerhans' cell histiocytosis. *N Engl J Med.* 2014;**371**(11):1050. doi: [10.1056/NEJMicm1312532](https://doi.org/10.1056/NEJMicm1312532). [PubMed: [25207768](https://pubmed.ncbi.nlm.nih.gov/25207768/)].
6. Haupt R, Minkov M, Astigarraga I, Schafer E, Nanduri V, Jubran R, et al. Langerhans cell histiocytosis (LCH): guidelines for diagnosis, clinical work-up, and treatment for patients till the age of 18 years. *Pediatr Blood Cancer.* 2013;**60**(2):175-84. doi: [10.1002/pbc.24367](https://doi.org/10.1002/pbc.24367). [PubMed: [23109216](https://pubmed.ncbi.nlm.nih.gov/23109216/)].
7. Ribeiro KB, Degar B, Antoneli CB, Rollins B, Rodriguez-Galindo C. Ethnicity, race, and socioeconomic status influence incidence of Langerhans cell histiocytosis. *Pediatr Blood Cancer.* 2015;**62**(6):982-7. doi: [10.1002/pbc.25404](https://doi.org/10.1002/pbc.25404). [PubMed: [25586293](https://pubmed.ncbi.nlm.nih.gov/25586293/)].
8. DiCaprio MR, Roberts TT. Diagnosis and management of langerhans cell histiocytosis. *J Am Acad Orthop Surg.* 2014;**22**(10):643-52. doi: [10.5435/JAAOS-22-10-643](https://doi.org/10.5435/JAAOS-22-10-643). [PubMed: [25281259](https://pubmed.ncbi.nlm.nih.gov/25281259/)].
9. Golai S, Nimbeni B, Patil SD, Kakanur M, Paul S. Langerhans histiocytosis in a child - diagnosed by oral manifestations. *J Clin Diagn Res.* 2015;**9**(4):ZD09-11. doi: [10.7860/JCDR/2015/12353.5786](https://doi.org/10.7860/JCDR/2015/12353.5786). [PubMed: [26023652](https://pubmed.ncbi.nlm.nih.gov/26023652/)].
10. Kamath S, Arkader A, Jubran RF. Outcomes of children younger than 24 months with langerhans cell histiocytosis and bone involvement: a report from a single institution. *J Pediatr Orthop.* 2014;**34**(8):825-30. doi: [10.1097/BPO.0000000000000218](https://doi.org/10.1097/BPO.0000000000000218). [PubMed: [25387157](https://pubmed.ncbi.nlm.nih.gov/25387157/)].
11. Ilan Y, Oren R, Ben-Chetrit E. Etiology, treatment, and prognosis of large pericardial effusions. A study of 34 patients. *Chest.* 1991;**100**(4):985-7. [PubMed: [1914616](https://pubmed.ncbi.nlm.nih.gov/1914616/)].
12. Sagrista-Sauleda J, Merce AS, Soler-Soler J. Diagnosis and management of pericardial effusion. *World J Cardiol.* 2011;**3**(5):135-43. doi: [10.4330/wjc.v3.i5.135](https://doi.org/10.4330/wjc.v3.i5.135). [PubMed: [21666814](https://pubmed.ncbi.nlm.nih.gov/21666814/)].
13. Bagri NK, Yadav DK, Agarwal S, Aier T, Gupta V. Pericardial effusion in children: experience from tertiary care center in northern India. *Indian Pediatr.* 2014;**51**(3):211-3. [PubMed: [24736909](https://pubmed.ncbi.nlm.nih.gov/24736909/)].
14. Pickens PV, Rosenshein M. Histiocytosis X with pericardial effusion. *JAMA.* 1981;**246**(16):1810-1. [PubMed: [6974251](https://pubmed.ncbi.nlm.nih.gov/6974251/)].
15. Keelie B. Pericardial effusion in a 16 month-old child with langerhans cell histiocytosis. UNT Health Science Center; 2013.