

Accelerated Burn Wound Closure in Mice with a New Formula Based on Traditional Medicine

Mehrnaz Mehrabani,¹ Seyyed Mohsen Seyyedkazemi,² Mohammad Hadi Nematollahi,³ Elham Jafari,⁴ Mitra Mehrabani,² Mohammad Mehdipour,⁵ Zahra Sheikhshoae,⁴ and Ali Mandegary^{2,5,*}

¹Department of Pharmacology, Iran University of Medical Sciences, Tehran, IR Iran

²Herbal and Traditional Medicines Research Center, Kerman University of Medical Sciences, Kerman, IR Iran

³Research Center for Hydatid Disease in Iran, Kerman University of Medical Sciences, Kerman, IR Iran

⁴Department of Pathology, Kerman University of Medical Sciences, Kerman, IR Iran

⁵Department of Pharmacology and Toxicology, School of Pharmacy, Kerman University of Medical Sciences, Kerman, IR Iran

*Corresponding author: Ali Mandegary, School of Pharmacy, Department of Pharmacology and Toxicology, Haft Bagh Blvd., P. O. Box: 76175493, Kerman, IR Iran. Tel: +98-3431325011, E-mail: alimandegary@kmu.ac.ir

Received 2015 January 17; Revised 2015 June 05; Accepted 2015 July 07.

Abstract

Background: A combination of the oils of sesame, hemp, wild pistachio, and walnut has been used for treatment of skin disorders, including wound burns, in some parts of Kerman, Iran. Evaluation of this remedy in the form of a pharmaceutical formulation in animal models can pave the way for its future application in wound burn healing in humans.

Objectives: This experimental study investigated the healing potential of a new formula (NF) based on folk medicine from Iran for the treatment of third degree burns in mice. The formula was a combination of the oils of four plants: sesame (*Sesamum indicum* L.), wild pistachio (*Pistacia atlantica* Desf.), hemp (*Cannabis sativa* L.), and walnut (*Juglans regia* L.)

Methods: Twenty-four mice were selected based on simple random sampling. Twenty-five percent of the total body surface area was burned by exposure to boiling water, according to the Walker-Mason method. NF and silver sulfadiazine (the positive control) were applied topically twice a day for 21 days. The burned area in the negative control group was left untreated. Epithelialization time and the percent of wound contraction were measured during the treatment period. The process of wound repairing was evaluated using histological (H and E and trichrome staining) and immunohistological (anti-pancytokeratin) methods.

Results: When compared to the controls, NF significantly improved wound contraction after day 10. Epithelialization time in the NF group was significantly faster than in the other groups (20 vs. 25.5 days) ($P < 0.001$). Histopathological and immunohistochemical findings confirmed the efficacy of the NF.

Conclusions: A new therapeutic remedy was introduced for the treatment of burn wounds. Further clinical and molecular studies are suggested to determine the exact mechanism(s) involved in the burn wound healing effect of NF.

Keywords: Burn, Folk Medicine, Healing

1. Background

Thermal burn injury is a major cause of death and disability in both developed and developing countries and results in high health care costs (1). Burn management comprises different stages, such as hospitalization for a significant duration, expensive medication, and multiple operative procedures (2, 3). Many therapeutics have been introduced, but healing of burn wounds remains a challenge in modern medicine.

The third-degree type of burn leads to severe damage to the epidermis, dermis, and deeper tissues, including muscles and connective tissues, and it heals with thick scars (4). Healing of any wound, including burn wounds, is a collaborative process involving extracellular and intra-

cellular signals that drive separate inflammatory, proliferative, and remodeling stages (4, 5). Hemostasis is an early event in the inflammatory stage. During this step, growth factors secreted from platelets attract macrophages and neutrophils. The neutrophil influx results in clearance of both cellular debris and bacteria at the damaged area. The macrophages, in turn, secrete factors that promote angiogenesis during wound healing (4, 6-9). Most of these cells that appear at this stage disappear in the proliferative stage, and the wound area becomes filled with new blood vessels (4). These processes of angiogenesis and neovascularization are critical determinants of the wound healing outcomes for deep burn injuries (10, 11). The final remodeling stage occurs when fibroblasts migrate into the

wound and induce collagen formation. Afterward, fibroblast differentiation into myofibroblasts causes tissue contraction (12).

The use of traditional and alternative medicine in wound therapy is reported in many folklore accounts, including those from Iran. Some recent clinical trials have confirmed the effectiveness of some of these traditional medicines (13). The use of traditional medicine is also viewed as a promising way to reduce the financial burden of wound treatments.

2. Objectives

The aim of this study was to evaluate a new formula (NF) as a topical remedy for the treatment of burn injury. The formulation for NF was based on the information derived from one of the most important Iranian traditional medicine sources: Avicenna's Canon of medicine (14). NF is a combination of the oils of four plants: sesame (*Sesamum indicum* L.), wild pistachio (*Pistacia atlantica* Desf.), hemp (*Cannabis sativa* L.), and walnut (*Juglans regia* L.). The criteria for selecting these plants for inclusion in NF were their use in folk medicine and their known beneficial attributes for wound healing, such as their antifungal (15), anti-inflammatory (16, 17), antioxidant (18-20), antimicrobial (15, 21, 22), and healing potential (23-26) properties.

3. Methods

3.1. Plant Material

The plant materials were collected from Jiroft province, Iran, in 2012 and were authenticated by a pharmacognosist (Dr. Mehrabani, herbal and traditional research center, Kerman University of Medical Sciences, Iran). The voucher specimens presented in Table 1 were preserved in the herbarium of the department of pharmacognosy of the School of pharmacy, Kerman University of Medical Science, Kerman, Iran.

3.2. Preparation and Formulation of the Traditional Remedy

NF is a combination of four plant oils at specific ratios: 60% sesame (*S. indicum*) oil, 20% wild pistachio (*P. atlantica*) oil, 12 % hemp (*C. sativa*) oil, and 8% walnut (*J. regia*) oil. The fixed oils of sesame, wild pistachio, hemp, and walnut were obtained by pressing 3 kilograms of seeds or fruits in a cold press machine (PR500, Germany). The resulting fixed oils were stored in universal dark bottles and refrigerated at 4°C until use. Our experimental study and formulation preparation were carried out under sterile conditions and fine particles were removed from the oil by filtration.

3.3. Animal Study

The male albino mice used in the experimental study weighed 22 to 25g and were 6 to 8 weeks old. The animals were allowed to adapt to their new housing for one week prior to the beginning of the experiment. Animals were housed in a 12:12 light-dark cycle, 25°C room temperature, and 45% humidity. Food and fresh water was provided *ad libitum*. The research was approved by the ethical committee of Kerman University of Medical Sciences and was conducted according to the international guidelines for laboratory animal use and care (EEC Directive of 1986; 86/609/EEC). Mice were randomly divided into 3 groups, with 8 mice per group, and treated with NF or silver sulfadiazine (SSD; 200 mg/kg/day, as a positive control) or left untreated (as a negative control). Mice were sacrificed at various intervals after thermal injury for histopathological examinations.

3.4. TBSA Calculating

Evaluation of the total body surface area (TBSA) in the experimental mice is essential for the modeling of burn injuries. The relationship between the two-dimensional surface area and three-dimensional body volume can be assessed from the body mass. The burn surface was calculated using the Meeh formula: $A = KW^{2/3}$, where A= body surface area, K = 10 and W = weight in grams (27). In this study, the burn area covered over 25% of the TBSA.

3.5. Burn Induction

The method was based on that described by Walker-Mason (28). Briefly, the mice were intraperitoneally (i.p.) anesthetized by injection of a cocktail of ketamine (80 mg/kg) and xylazine (1.2 mg/kg), and then the dorsal surface of animals was shaved. The mice were transferred into separated restrainers and 25% of the TBSA was exposed to boiling water (100°C) for 10 seconds (28). All animals were dried immediately and resuscitated via IP injection of 1.0 mL physiological saline. The NF (100 mg/mouse) was applied topically twice a day from wound induction until complete healing. The rate of wound healing was determined by measuring the size of the lesions once every three days. The wound area on day one was considered as 100% and the wound areas on subsequent days were compared with this initial wound area.

3.6. Wound Planimetry

Epithelialization time and wound contraction were measured to assess wound healing. Epithelialization time was monitored until the scars that covered the burn wound surface fell off. Wound contraction was calculated using the following formula:

Table 1. Plant Species Used in the Present Study

Plant Samples, Species	Voucher Number	Common Name	Plant Used
<i>Pistacia atlantica</i> Desf.	1824 - 1	Wild pistachio	Fruit
<i>Sesamum indicum</i> L.	1823 - 1	Sesame	Seed
<i>Cannabis sativa</i> L.	1369 - 4	Hemp	Fruit
<i>Juglans regia</i> L.	1844 - 1	Walnut	Seed

Concentration (%) = (wound area of day 0 - wound area of day x) / wound area of day 0 × 100

Where x = 0, 4, 7, 10, 14, 18, or 21 (29)

The wound area was measured in mm² by tracing the wound boundaries using image J software (<http://rsbweb.nih.gov/ij/>) once every three days.

3.7. Histopathology Study

Burned skin samples for histopathological examinations were collected from all groups on the 4th, 12th, and 21st days, after sacrificing the mice. These skin samples were fixed in 10% formaldehyde solution for 48 hours and each was embedded in a paraffin wax block for sectioning. The sections were stained with hematoxylin and eosin (H and E) and Masson trichrome (for detection of collagen fibers) (Olympus BX51). Inflammatory cell (neutrophil) numbers, re-epithelialization, angiogenesis, fibroblast numbers, necrosis, and collagen deposition were evaluated according to a semi-quantitative scoring system: - (absent), Trace ~ weak, + (minimal), ++ (mild), +++ (moderate), and ++++ (marked) (30).

3.8. Immunohistochemistry

Immunohistochemistry was performed on samples obtained at day 21 after burn injury induction. Briefly, sections were incubated overnight at 48°C with an anti-pancytokeratin monoclonal antibody (diluted 1:50 Dako).

3.9. Statistical Analysis

All data were expressed as means ± SD. One-way ANOVA with Scheffe's post hoc test was used to compare the areas of the wounds. A P value < 0.001 was considered significant.

4. Results

4.1. Wound Contraction

As shown in Table 2, the burned area on the first day did not differ among the three groups (P = 0.34). Wound contraction on different days is shown in Table 2, which indicates that the NF treatment significantly increased wound

contraction at days 10, 14, 18, and 21. Wound contraction was significantly lower in the SSD group than in the negative control (P < 0.001) beyond day 18 after burning (Table 2 and Figure 1).

4.2. Epithelialization Time

NF significantly (P < 0.001) decreased the epithelialization time when compared with the other groups (Table 3 and Figure 2).

4.3. Histopathological and Immunohistochemical Findings

4.3.1. Day 4 After Burning

The burn areas in the negative control mice showed skin tissue characterized by extensive epidermal and dermal necrosis, with inflammatory cells in the central area. Some neutrophilic infiltration was seen in the peripheral tissues of the necrotic dermis. The burn areas of the mice treated with SSD showed extensive necrosis, along with dense transmural neutrophilic infiltration, especially in the subcutaneous fat. The burn areas in the NF treated group showed skin tissue with extensive necrosis and dense neutrophilic infiltration, with abscess formation in the subcutaneous fat.

4.3.2. Day 12 After Burning

The burn areas in mice treated with NF contained skin tissue showed focal re-epithelialization and marked fibroblastic proliferation. Granulation tissue formation and abscess formation in subcutaneous fat tissues were greater in the NF group than in the SSD group.

4.3.3. Day 21 After Burning

The NF-treated mice showed marked skin tissue re-epithelialization, granulation tissue formation, scattered inflammatory cells infiltration, and collagenization in the dermis and skin appendages. The collagenization and reepithelialization effects were significantly greater in the NF group than in the SSD group. The histopathological results (H and E and Masson's trichrome staining) are shown in Table 4 and Figure 4. These findings were further confirmed by the immunohistological analysis with anti-pancytokeratin antibody (Figure 5).

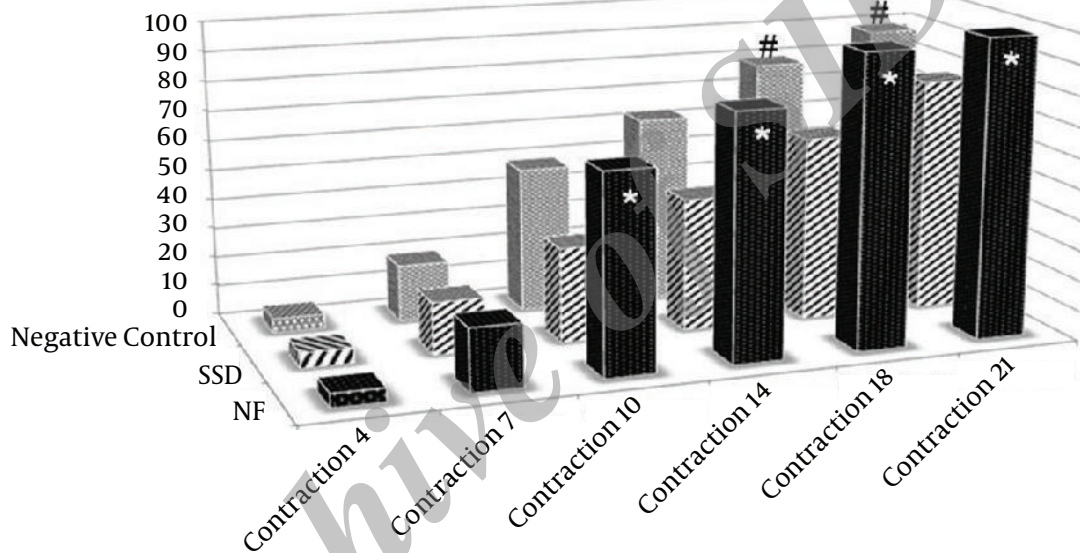
Table 2. Measurement of Wound Size at 4, 7, 10, 14, 18, and 21 Days After Burning, Presented as Wound Contraction

Groups	Percentage of Wound Contraction (%) (Mean \pm SD)					
	Day 4	Day 7	Day 10	Day 14	Day 18	Day 21
NF	4.6 \pm 1.8	20.7 \pm 5.2	65.9 \pm 3.8 ^a	79.9 \pm 4.2 ^a	97.3 \pm 1.5 ^a	99.5 \pm 0.8 ^a
SSD	5.1 \pm 2.8	17.5 \pm 2.9	31.5 \pm 4.6	44.3 \pm 3.9	61.4 \pm 3.3 ^b	78.0 \pm 4.0 ^b
Negative control	5.4 \pm 1.9	18.8 \pm 4.9	37.4 \pm .7	56.4 \pm 4.1	73.5 \pm 3.7	88.4 \pm 2.5

Abbreviations: NF, new formula; SSD, silver sulfadiazine.

^aSignificant healing occurred in the NF group when compared the other groups ($P = 0.000$). Data were analyzed by one way ANOVA.

^bSignificantly less healing was noted in the SSD compared with the negative control ($P = 0.000$). Data were analyzed by one way ANOVA.

Figure 1. Measurement of Wound Size at 4, 7, 10, 14, 18, and 21 Days After Burning, Presented as Wound Size Contraction


*Significant healing occurred in the NF group when compared to the other groups ($P < 0.001$), # Significantly lower healing occurred with SSD when compared with the negative control ($P < 0.001$). NF, new formula; SSD, Silver sulfadiazine.

Table 3. Effect of NF on Epithelialization Time of Third Degree Burns in Mice^{a,b}

Groups	Epithelialization Time, Mean \pm SD
NF	20.5 \pm 1.37 ^{c,d}
SSD	26.33 \pm 0.81
Negative control	25.5 \pm 0.83

Abbreviations: NF, new formula; SSD, silver sulfadiazine.

^aValues are expressed as mean \pm SD.

^bNo. of mice = 6.

^c $P < 0.001$ in comparison to the negative control ($P = 0.000$).

^d $P < 0.001$ in comparison to SSD treatment ($P = 0.000$).

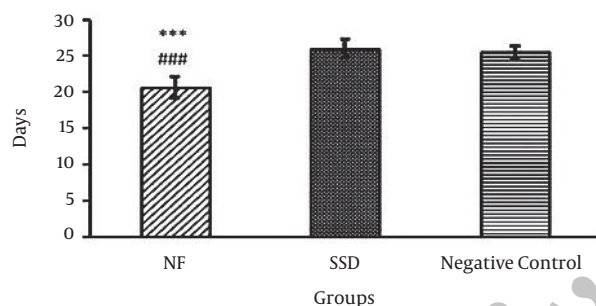
5. Discussion

This study demonstrated that NF increased the rate of healing of third degree burn wounds. We analyzed the progress in wound healing at different time points throughout the three weeks following treatment. Interestingly, a significantly greater wound healing effect was observed with NF than with SSD, a conventional therapy for burn injuries. Note that NF consists of a mixture of four structural components walnut, wild pistachio, hemp, and sesame oils that each play different roles in wound healing. The long history of the practice of traditional medicine has confirmed the greater effectiveness of a combination of several herbs in a single formula than a single constituent for the management of disease (31, 32).

Table 4. Effect of NF Treatment on Burn Healing in Mice^a

Groups	Day 4			Day 12			Day 21		
	Untreated	SSD	NF	Untreated	SSD	NF	Untreated	SSD	NF
Inflammatory	++	+++	++	++	++	++	+	++	Trace
Angiogenesis	Trace	+	+	+	++	+++	++	++	+
Fibroblasts count	Trace	+	+	+	++	+++	++	++	+
Re-epithelialization	-	-	-	+	+	++	+++	++	++++
Necrosis	+++	+++	+++	+++	++	++	+	+	-

^aAccording to the pathological findings, the grading of injuries was as follows: - (absent), Trace ~ weak, + (minimal), ++ (mild), +++ (moderate), and ++++ (marked).

Figure 2. Effect of NF on epithelialization time of third degree burns in mice


Values are expressed as mean \pm SD, n=6 mice. ***P < 0.001 in comparison to the negative control, ### P < 0.001 in comparison to the SSD treatment. NF, new formula; SSD, Silver sulfadiazine.

Beneficial effects in wound healing have been reported for each of the components of NF. For example, sesame seeds contain two unique phenolic substances sesamin and sesamol that have antioxidant properties and may prevent the spoilage of oils (17, 18). The use of antioxidants has been shown to promote wound healing (33) through the scavenging of free radicals from the site of injury. Free radicals are believed to impair the healing process by damaging cellular membranes, nucleotides, proteins, and lipids (34). Sesame oil also has antibacterial activities against common skin pathogens, such as *Staphylococcus* and *Streptococcus* spp. and against common skin fungi such as athlete's foot fungus. It also shows anti-viral and anti-inflammatory effects (15, 17, 24).

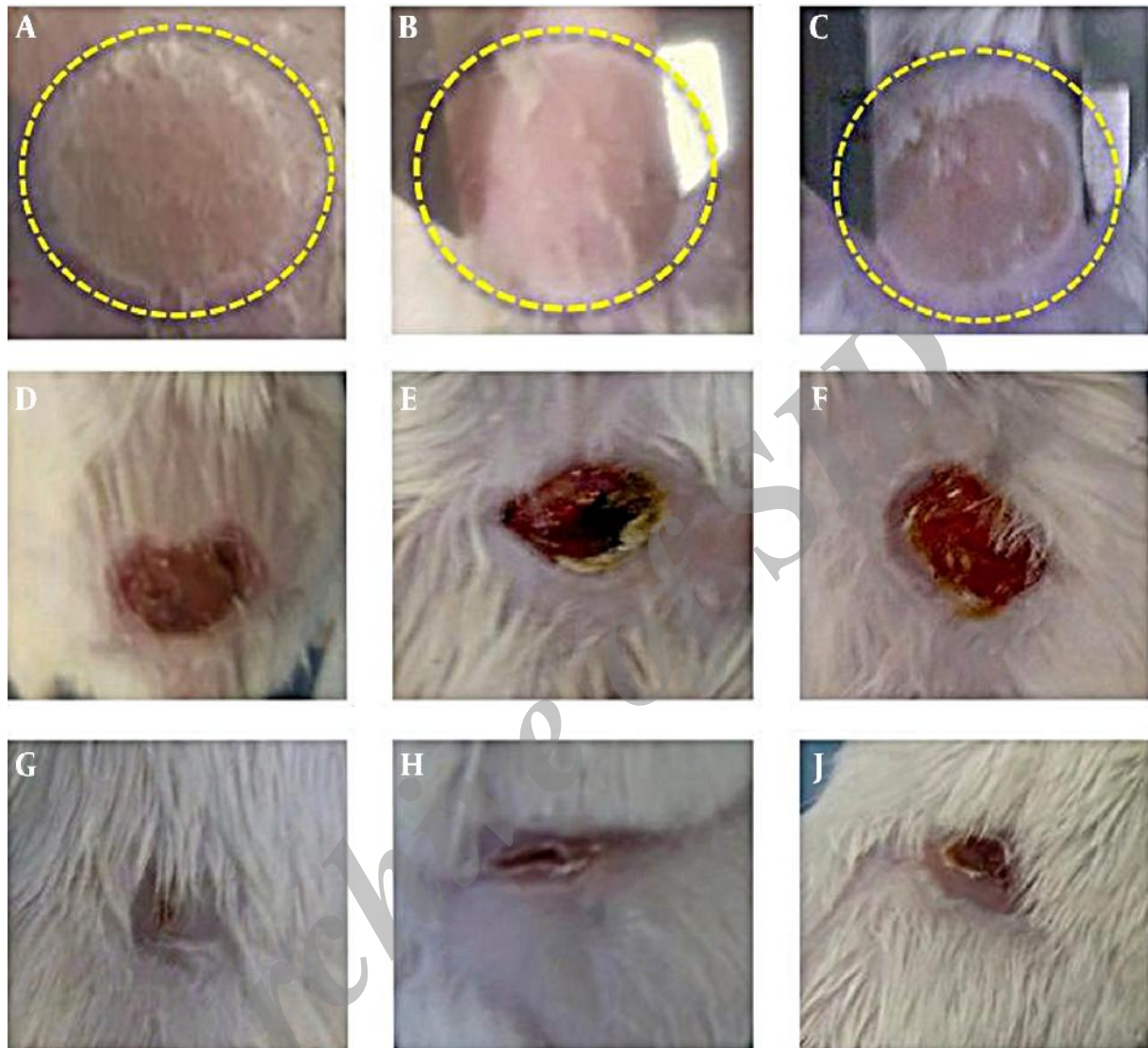
Wild pistachio is used in traditional medicine to treat swelling, inflammation, and ulcers (24). Studies on the chemical composition of oil from wild pistachio reported that the main fatty acids were oleic and linoleic acids. The oil also showed antioxidant properties due to its total phe-

nol content (35). Pheophytin, which is the major pigment in wild pistachio oil, also shows potent anti-inflammatory activity (35-37). Djerrou and his colleagues (38) showed that Mastic (*Pistacia lentiscus* L.) fatty oil significantly promoted wound contraction and reduced epithelialization time in a rabbit model.

Walnut oil has long been recognized for its valuable effects on skin and is a common additive in cosmetics. Its moisturizing and free radical scavenging properties have led to its use as a component of moisturizing skin creams, anti-wrinkle treatments, and anticaking products (39). The benefits of walnut oil in cosmetic products may be partly due to the presence of essential fatty acids, including linoleic acid and linolenic acid (40, 41). These acids play a central role in the regulation of trans-epidermal water loss, which is one of the most important functions of the skin (42). The omega-3 and omega-6 fatty acids are also reported to have the potential to change the production rates of eicosanoids, especially prostaglandins, to improve and enhance wound healing (23).

Cannabis has been used in traditional medicine to treat swelling and inflammation (24). Hemp seed oil contains linoleic acid and linolenic acid and is valued primarily for its nutritional properties, as well as for the health benefits (43). Although Δ 9-tetrahydrocannabinol (Δ 9-THC) is commonly accepted as the main factor responsible for the effects of cannabis, other components of this herb influence its pharmacological activity. One of these components is cannabidiol (CBD). Analgesic and anti-inflammatory effects have been reported in animal studies on the CBD present in hemp seed oil (16, 44, 45).

One of the contradictory results of this study was that SSD was less effective in burn wound healing when compared to the negative control group. A deleterious effect of SSD on burn wound healing has been reported in other studies (46). This effect may be related in part to the cyto-

Figure 3. Comparison of Wound Closure Among the NF, Negative Control, and SSD Groups.

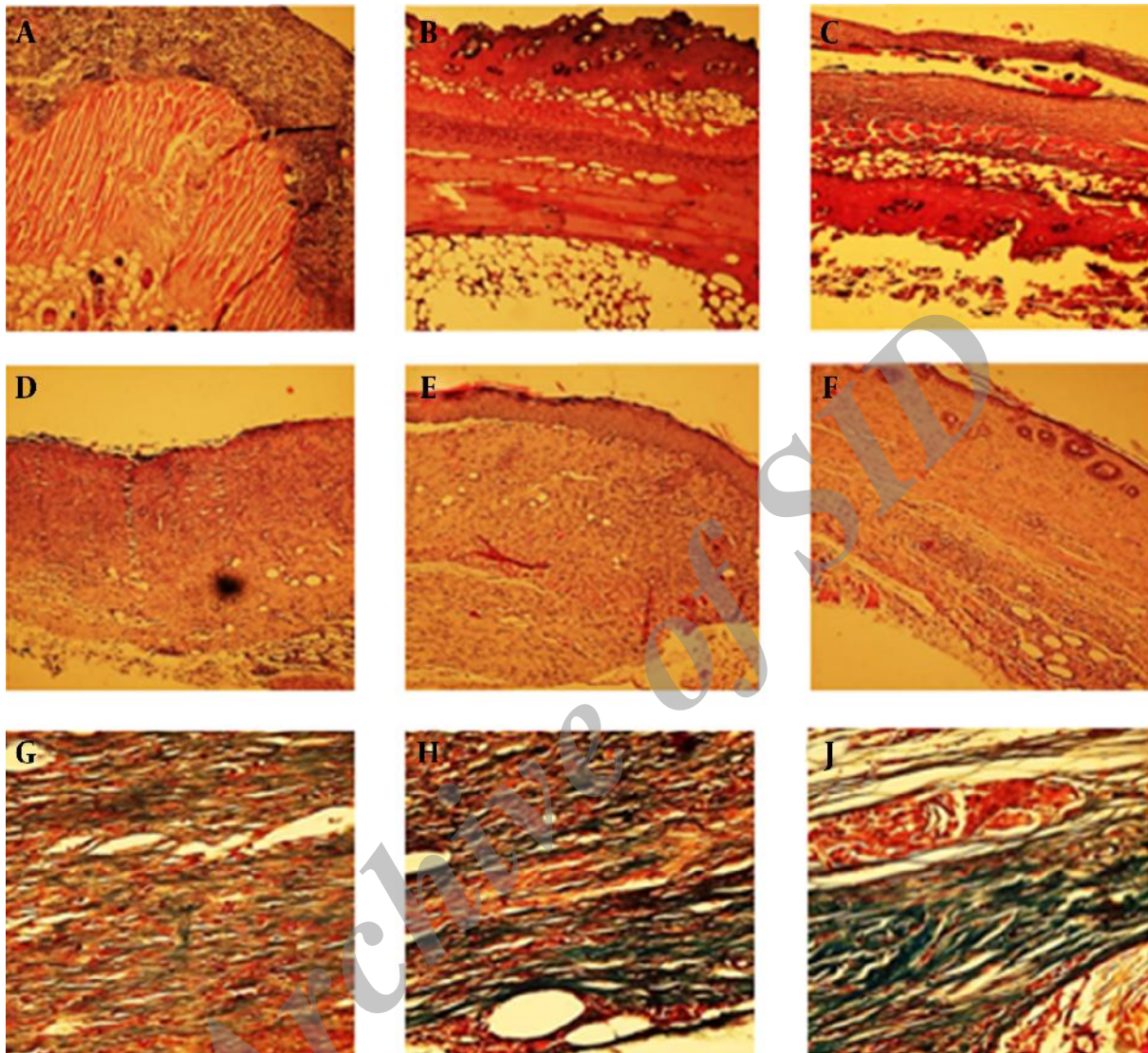
Representative photographs of the burn wounds at days 1, 12, and 21 after burning in a mouse model. A, NF; B, Negative control; and C, SSD at Day 1. D, NF; E, Negative control; and F, SSD at Day 12. G, NF; H, Negative control; I, SSD at day 21. NF: new formula, SSD: Silver sulfadiazine.

toxic effects of SSD on skin keratinocytes (47).

Wound healing involves a cascade of events and is characterized by completion of specific biological processes in a certain order and within a certain time frame (48). It is a spontaneous and self-initiated process. However, numerous risk factors can delay the wound healing rate, including infection by organisms of endogenous and exogenous origin (49). For example, *Pseudomonas aeruginosa* is an important opportunistic pathogen that can seriously affect burn wounds, particularly in immunocompromised patients (50). Under these conditions, acceleration of the

wound healing process is vital (51). The aim of burn therapy is to promote the wound healing time in order to reduce post-burn complications such as infection and scarring (52). In line with this fact, burns that heal in less than 21 days typically exhibit minimal scar formation (53).

Many previous articles have reported side effects of silver sulfadiazine treatment, including retardation of wound healing, allergic reactions to its sulfadiazine moiety, and silver staining of the treated burn wound. Our NF avoids all these complications. It gave complete contraction and re-epithelialization times of less than 21 days af-

Figure 4. Effect of NF on Skin Repair in Mice

A, SSD; B, Negative control; and C, NF at Day 4 (H and E). D, SSD; E, Negative control; and F, NF at Day 21 (H and E). G, SSD; H, Negative control; I, NF at day 21 (Trichrome staining). Skin repair after burning was evaluated using histological analysis with H and E (100 \times) and Masson's trichrome staining (400 \times). The NF group showed marked tissue re-epithelialization, granulation tissue formation, scattered inflammatory cell infiltration, and collagenization in the dermis and skin appendages. NF, new formula; SSD, silver sulfadiazine (as positive control).

ter burning, without leaving any scarring or other post-healing disfigurement. The results of the present study support the introduction of NF as a new therapeutic remedy for the treatment of burn wounds and confirm the usefulness of traditional and folklore information. The limitations of our study include the lack of a scientific survey on a human model of burn wound healing, which could have different wound healing mechanisms when compared to mice. An additional limitation is the small sample size; fu-

ture work involving a larger sample size is warranted. The advantages of our study include our identification of a traditional formula for burn wound healing with significant results that would be a cost-effective and clinically effective therapy. However, further clinical and molecular studies are needed to determine the exact mechanism(s) involved in the burn wound healing effects of NF.

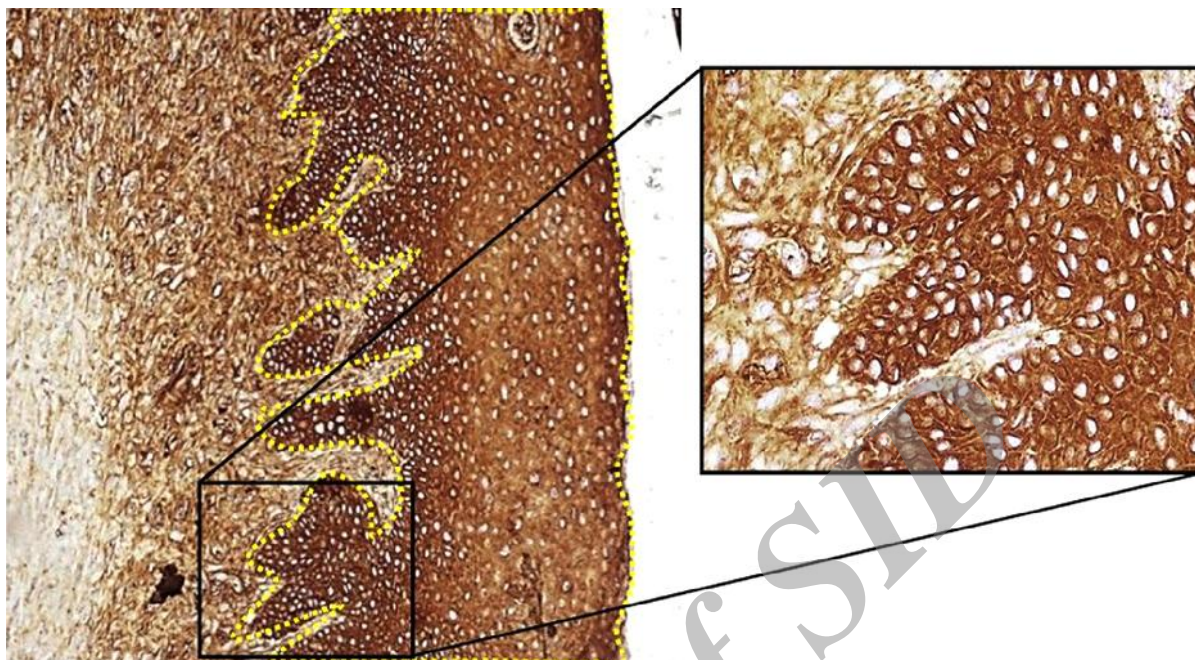


Figure 5. Pancytokeratin antibody-labeled section of tissue 21 days after burning from the NF group, showing complete epithelialization, 100 × and 400 ×. NF, new formula.

Footnotes

Authors' Contribution: MM and MHN designed the study, conducted the statistical analysis, analysis and interpretation of data, and drafted the manuscript. E] performed the histopathological analysis. AM and MM supervised and designed the study and participated in drafting the manuscript. MM conducted the experiment. SMS participated in introducing the plants and preparation of the NF formulation. ZSH Prepared the histopathological samples.

Funding/Support: This study was funded and supported by a Kerman University of Medical Sciences (KUMS) grant [grant number 92/31].

References

- IMF. The Tenth Plan (Poverty Reduction Strategy Paper) 2002-2007. Washington: International Monetary Fund; 2003. pp. 46-7.
- Gore MA, Akolekar D. Evaluation of banana leaf dressing for partial thickness burn wounds. *Burns*. 2003;**29**(5):487-92. [PubMed: [12880731](#)].
- Ghosh A, Bharat R. Domestic burns prevention and first aid awareness in and around Jamshedpur, India: strategies and impact. *Burns*. 2000;**26**(7):605-8. [PubMed: [10925182](#)].
- Gurtner GC, Werner S, Barrandon Y, Longaker MT. Wound repair and regeneration. *Nature*. 2008;**453**(7193):314-21. doi: [10.1038/nature07039](#). [PubMed: [18480812](#)].
- Kirker KR, Luo Y, Nielson JH, Shelby J, Prestwich GD. Glycosaminoglycan hydrogel films as bio-interactive dressings for wound healing. *Biomaterials*. 2002;**23**(17):3661-71. [PubMed: [12109692](#)].
- Haroon ZA, Hettasch JM, Lai TS, Dewhirst MW, Greenberg CS. Tissue transglutaminase is expressed, active, and directly involved in rat dermal wound healing and angiogenesis. *FASEB J*. 1999;**13**(13):1787-95. [PubMed: [10506581](#)].
- Steed DL. The role of growth factors in wound healing. *Surg Clin North Am*. 1997;**77**(3):575-86. [PubMed: [9194881](#)].
- Kim MH, Liu W, Borjesson DL, Curry FR, Miller LS, Cheung AL, et al. Dynamics of neutrophil infiltration during cutaneous wound healing and infection using fluorescence imaging. *J Invest Dermatol*. 2008;**128**(7):1812-20. doi: [10.1038/sj.jid.5701223](#). [PubMed: [18185533](#)].
- Greenhalgh DG. The role of apoptosis in wound healing. *Int J Biochem Cell Biol*. 1998;**30**(9):1019-30. [PubMed: [9785465](#)].
- Tredget EE. The basis of fibrosis and wound healing disorders following thermal injury. *J Trauma*. 2007;**62**(6 Suppl):S69. doi: [10.1097/TA.0b013e318065ae84](#). [PubMed: [17556985](#)].
- Li J, Zhang YP, Kirsner RS. Angiogenesis in wound repair: angiogenic growth factors and the extracellular matrix. *Microsc Res Tech*. 2003;**60**(1):107-14. doi: [10.1002/jemt.10249](#). [PubMed: [12500267](#)].
- Singer AJ, Clark RA. Cutaneous wound healing. *N Engl J Med*. 1999;**341**(10):738-46. doi: [10.1056/NEJM199909023411006](#). [PubMed: [10471461](#)].
- Dorai AA. Wound care with traditional, complementary and alternative medicine. *Indian J Plast Surg*. 2012;**45**(2):418-24. doi: [10.4103/0970-0358.101331](#). [PubMed: [23162243](#)].
- Gruner OC, Bakhtiar L, Shah MH, Crook JR. The Canon of Medicine (al-Qanun Fl-Tibb). India: Abjad Book Designers and Builders; 1999.
- Shittu LAJ, Bankole M, Ahmed T, Bankole MN, Shittu RK, Saalu CL, et al. Antibacterial and antifungal activities of essential oils of crude extracts of Sesame radiatum against some common pathogenic microorganisms. *Iranian J Pharmacol Ther*. 2008;**6**(2):165-70.
- Formukong EA, Evans AT, Evans FJ. Analgesic and antiinflammatory activity of constituents of Cannabis sativa L. *Inflammation*. 1988;**12**(4):361-71. [PubMed: [3169967](#)].

17. Anilakumar KR, Pal A, Khanum F, Bawa AS. Nutritional, medicinal and industrial uses of sesame (*Sesamum indicum* L.) seeds-an overview. *Agric Conspec Sci*. 2010;**75**(4):159-68.
18. Kim JY, Choi DS, Jung MY. Antiphot-oxidative activity of sesamol in methylene blue- and chlorophyll-sensitized photo-oxidation of oil. *J Agric Food Chem*. 2003;**51**(11):3460-5. doi: [10.1021/jf026056p](https://doi.org/10.1021/jf026056p). [PubMed: [12744684](https://pubmed.ncbi.nlm.nih.gov/12744684/)].
19. Arranz S, Pérez-Jiménez J, Saura-Calixto F. Antioxidant capacity of walnut (*Juglans regia* L.): contribution of oil and defatted matter. *Eur Food Res Technol*. 2007;**227**(2):425-31. doi: [10.1007/s00217-007-0737-2](https://doi.org/10.1007/s00217-007-0737-2).
20. Benhammou N, Bekkara FA, Panovska TK. Antioxidant and antimicrobial activities of the *Pistacia lentiscus* and *Pistacia atlantica* extracts. *Afr J Pharm Pharmacol*. 2008;**2**(2):22-8.
21. Oliveira I, Sousa A, Ferreira IC, Bento A, Estevinho L, Pereira JA. Total phenols, antioxidant potential and antimicrobial activity of walnut (*Juglans regia* L.) green husks. *Food Chem Toxicol*. 2008;**46**(7):2326-31. doi: [10.1016/j.fct.2008.03.017](https://doi.org/10.1016/j.fct.2008.03.017). [PubMed: [18448225](https://pubmed.ncbi.nlm.nih.gov/18448225/)].
22. Nissen L, Zatta A, Stefanini I, Grandi S, Sgorbati B, Biavati B, et al. Characterization and antimicrobial activity of essential oils of industrial hemp varieties (*Cannabis sativa* L.). *Fitoterapia*. 2010;**81**(5):413-9. doi: [10.1016/j.fitote.2009.11.010](https://doi.org/10.1016/j.fitote.2009.11.010). [PubMed: [19969046](https://pubmed.ncbi.nlm.nih.gov/19969046/)].
23. Ruthig DJ, Meckling-Gill KA. Both (n-3) and (n-6) fatty acids stimulate wound healing in the rat intestinal epithelial cell line, IEC-6. *J Nutr*. 1999;**129**(10):1791-8. [PubMed: [10498749](https://pubmed.ncbi.nlm.nih.gov/10498749/)].
24. Sina AA. The Canon of Medicine. Tehran: Soroush Press; 2010.
25. Boulebdia N, Belkhiri A, Belfadel F, Bensegueni A, Bahri L. Dermal Wound Healing Effect of *Pistacia lentiscus* Fruit's Fatty Oil. *Pharmacognosy Research*. 2009;**1**(2):66.
26. Al-Habbal MJ, Al-Habbal Z, Huwez FU. A double-blind controlled clinical trial of mastic and placebo in the treatment of duodenal ulcer. *Clin Exp Pharmacol Physiol*. 1984;**11**(5):541-4. [PubMed: [6395994](https://pubmed.ncbi.nlm.nih.gov/6395994/)].
27. Meeh KV. Oberflächenmessungen des menschlichen Körpers. *Z. biol*. 1879;**15**:425-58.
28. Walker HC, Mason AD. A standard animal burn. *J Trauma*. 1968;**8**:1049. doi: [10.1097/00005373-196811000-00000](https://doi.org/10.1097/00005373-196811000-00000).
29. Lundberg TC, Eriksson SV, Malm M. Electrical nerve stimulation improves healing of diabetic ulcers. *Ann Plast Surg*. 1992;**29**(4):328-31. [PubMed: [1466529](https://pubmed.ncbi.nlm.nih.gov/1466529/)].
30. Gal P, Kilik R, Mokry M, Vidinsky B, Vasilenko T, Mozes S, et al. Simple method of open skin wound healing model in corticosteroid-treated and diabetic rats: standardization of semi-quantitative and quantitative histological assessments. *Vet Med*. 2008;**53**(12):652-9.
31. WHO. International standard terminologies on traditional medicine in the western pacific region. Geneva: World Health Organization; 2007.
32. Jia W, Gao WY, Yan YQ, Wang J, Xu ZH, Zheng WJ, et al. The rediscovery of ancient Chinese herbal formulas. *Phytother Res*. 2004;**18**(8):681-6. doi: [10.1002/ptr.1506](https://doi.org/10.1002/ptr.1506). [PubMed: [15476313](https://pubmed.ncbi.nlm.nih.gov/15476313/)].
33. Sen CK, Khanna S, Gordillo G, Bagchi D, Bagchi M, Roy S. Oxygen, oxidants, and antioxidants in wound healing: an emerging paradigm. *Ann NY Acad Sci*. 2002;**957**:239-49. [PubMed: [12074976](https://pubmed.ncbi.nlm.nih.gov/12074976/)].
34. Khanna S, Venojarvi M, Roy S, Sharma N, Trikha P, Bagchi D, et al. Dermal wound healing properties of redox-active grape seed proanthocyanidins. *Free Radic Biol Med*. 2002;**33**(8):1089-96. [PubMed: [12374620](https://pubmed.ncbi.nlm.nih.gov/12374620/)].
35. Givianrad MH, Saber-Tehrani M, Jafari Mohammadi SA. Chemical composition of oils from wild almond (<i>Prunus scoparia</i>) and wild pistachio (<i>Pistacia atlantica</i>). *Grasas y Aceites*. 2013;**64**(1):77-84. doi: [10.3989/gya.070312](https://doi.org/10.3989/gya.070312).
36. Islam MN, Ishita IJ, Jin SE, Choi RJ, Lee CM, Kim YS, et al. Anti-inflammatory activity of edible brown alga *Saccharina japonica* and its constituents pheophorbide a and pheophytin a in LPS-stimulated RAW 264.7 macrophage cells. *Food Chem Toxicol*. 2013;**55**:541-8. doi: [10.1016/j.fct.2013.01.054](https://doi.org/10.1016/j.fct.2013.01.054). [PubMed: [23402855](https://pubmed.ncbi.nlm.nih.gov/23402855/)].
37. Okai Y, Higashi-Okai K. Potent anti-inflammatory activity of pheophytin a derived from edible green alga, *Enteromorpha prolifera* (Suji-ao-nori). *Int J Immunopharmacol*. 1997;**19**(6):355-8. [PubMed: [9467755](https://pubmed.ncbi.nlm.nih.gov/9467755/)].
38. Djerrou Z, Maameri Z, Hamdi-Pacha Y, Serakta M, Riachi F, Djaalab H, et al. Effect of virgin fatty oil of *Pistacia lentiscus* on experimental burn wound's healing in rabbits. *Afr J Tradit Complement Altern Med*. 2010;**7**(3):258-63. [PubMed: [21461154](https://pubmed.ncbi.nlm.nih.gov/21461154/)].
39. Espin JC, Soler-Rivas C, Wichers HJ. Characterization of the total free radical scavenger capacity of vegetable oils and oil fractions using 2,2-diphenyl-1-picrylhydrazyl radical. *J Agric Food Chem*. 2000;**48**(3):648-56. [PubMed: [10725129](https://pubmed.ncbi.nlm.nih.gov/10725129/)].
40. Karleskind A. Oils and fats manual: a comprehensive treatise: properties, production, applications. 1. Paris: Lavoisier Publishing; 1996.
41. Sajjadi M. Effects of dietary fish oil on wound healing in diabetic rats. *J Physiol Pharmacol*. 1999;**3**(2):181-91.
42. Mao-Qiang M, Elias PM, Feingold KR. Fatty acids are required for epidermal permeability barrier function. *J Clin Invest*. 1993;**92**(2):791-8. doi: [10.1172/JCI116652](https://doi.org/10.1172/JCI116652). [PubMed: [8102380](https://pubmed.ncbi.nlm.nih.gov/8102380/)].
43. Deferne JL, Pate DW. Hemp seed oil: A source of valuable essential fatty acids. *J Int Hemp Assoc*. 1996;**3**(1):4-7.
44. Grlie L. A comparative study on some chemical and biological characteristics of various samples of cannabis resin. *B Narcotics*. 1976;**14**:37-46.
45. Leizer C, Ribnicky D, Poulev A, Dushenkov S, Raskin I. The Composition of Hemp Seed Oil and Its Potential as an Important Source of Nutrition. *J Diet Suppl*. 2015;**2**(4):35-53. doi: [10.1300/J133v02n04_04](https://doi.org/10.1300/J133v02n04_04).
46. Cho Lee AR, Leem H, Lee J, Park KC. Reversal of silver sulfadiazine-impaired wound healing by epidermal growth factor. *Biomaterials*. 2005;**26**(22):4670-6. doi: [10.1016/j.biomaterials.2004.11.041](https://doi.org/10.1016/j.biomaterials.2004.11.041). [PubMed: [15722137](https://pubmed.ncbi.nlm.nih.gov/15722137/)].
47. Fraser JF, Cuttle L, Kempf M, Kimble RM. Cytotoxicity of topical antimicrobial agents used in burn wounds in Australasia. *ANZ J Surg*. 2004;**74**(3):139-42. [PubMed: [14996161](https://pubmed.ncbi.nlm.nih.gov/14996161/)].
48. Nayak S, Nalabothu P, Sandiford S, Bhogadi V, Adogwa A. Evaluation of wound healing activity of *Allamanda cathartica* L. and *Laurus nobilis* L. extracts on rats. *BMC Complement Altern Med*. 2006;**6**:12. doi: [10.1186/1472-6882-6-12](https://doi.org/10.1186/1472-6882-6-12). [PubMed: [16597335](https://pubmed.ncbi.nlm.nih.gov/16597335/)].
49. Albayrak A, Demiryilmaz I, Albayrak Y, Ayulu B, Ozogul B, Cerrah S, et al. The role of diminishing appetite and serum nesfatin-1 level in patients with burn wound infection. *Iran Red Crescent Med J*. 2013;**15**(5):389-92. doi: [10.5812/ircmj.4198](https://doi.org/10.5812/ircmj.4198). [PubMed: [24349725](https://pubmed.ncbi.nlm.nih.gov/24349725/)].
50. Moazami-Goudarzi S, Eftekhari F. Assessment of Carbapenem Susceptibility and Multidrug-Resistance in *Pseudomonas aeruginosa* Burn Isolates in Tehran. *Jundishapur J Microbiol*. 2013;**6**(2) doi: [10.5812/jjm.5036](https://doi.org/10.5812/jjm.5036).
51. Priya KS, Gnanamani A, Radhakrishnan N, Babu M. Healing potential of *Datura alba* on burn wounds in albino rats. *J Ethnopharmacol*. 2002;**83**(3):193-9. doi: [10.1016/s0378-8741\(02\)00195-2](https://doi.org/10.1016/s0378-8741(02)00195-2).
52. Salas Campos L, Fernandes Mansilla M, Martinez de la Chica AM. [Topical chemotherapy for the treatment of burns]. *Rev Enferm*. 2005;**28**(5):67-70. [PubMed: [15981974](https://pubmed.ncbi.nlm.nih.gov/15981974/)].
53. Cubison TC, Pape SA, Parkhouse N. Evidence for the link between healing time and the development of hypertrophic scars (HTS) in paediatric burns due to scald injury. *Burns*. 2006;**32**(8):992-9. doi: [10.1016/j.burns.2006.02.007](https://doi.org/10.1016/j.burns.2006.02.007). [PubMed: [16901651](https://pubmed.ncbi.nlm.nih.gov/16901651/)].