

The Protective Effect of the Methanolic Extract of *Ferula persica* in Rat Tongue Neoplasm (Oral Squamous Cell Carcinoma) induced by 4-Nitroquinoline-1-Oxide (4-NQO)

Amirala Aghbali,¹ Samira Mostafazadeh,² Mehran Mesgari Abbasi,³ Soheila Fotoohi,³ Bita Abdollahi,³

Mehnoush Janani,⁴ and Monir Moradzadeh Khiavi^{5*}

¹Department of Oral and Maxillofacial Pathology, Faculty of Dentistry, Tabriz University of Medical Sciences, Tabriz, IR Iran

²Department of Oral and Maxillofacial Pathology, Faculty of Dentistry, Urmia University of Medical Sciences, Urmia, Iran

³Drug Applied Research Center, Tabriz University of Medical Sciences, Tabriz, IR Iran

⁴Department of Plant Biology, University of Mohaghegh Ardabili, Ardabil, IR Iran

⁵Department of Oral and Maxillofacial Pathology, Faculty of Dentistry, Tehran University of Medical Sciences, International Campus, Tehran, IR Iran

*Corresponding author: Monir Moradzadeh Khiavi, Department of Oral and Maxillofacial Pathology, Faculty of Dentistry, Tehran University of Medical Sciences, International Campus, Tehran, IR Iran. Tel: +98-2155851131, E-mail: m-moradzadeh@sina.tums.ac.ir

Received 2014 November 30; Revised 2015 March 14; Accepted 2015 April 11.

Abstract

Background: Cancer is one of the most significant causes of death around the world, and oral squamous cell carcinoma (OSCC) represents 90% of oral malignancies. *Ferula persica* has been used for treatment of different diseases in Iranian traditional medicine. Previous studies reveal some evidence relating to the value of preventing malignancies through *F. persica*.

Objectives: The aim of the present study was to evaluate the protective effect of methanolic extract of *Ferula persica* in rat tongue neoplasm induced by 4-Nitroquinoline-1-Oxide (4-NQO).

Materials and Methods: This experimental study was carried out in the pharmaceutical research center in Tabriz, Iran. According to ethical considerations, the results of the pilot study (five rats in each group) and pathologic changes in 30% of cases with considering $\alpha = 5\%$, $P = 80\%$, and $d = 5\%$, 15 samples for each group were determined. In this study, the OSCC was induced by 4-NQO in 60 SD rats (in four groups). At the same time, three groups of rats received *Ferula persica* methanolic extract (FPME) intraperitoneally (IP) in the doses 50, 250, and 500 mg per kilogram of body weight twice each week for 14 weeks.

Results: The obtained weight differences between groups were not significant ($P = 0.18$). Pathological changes in the treated and non-treated groups were significantly different ($P < 0.001$). After treatment, pathologic changes were seen in groups A, B, C, and D (the cancer control group) respectively as follows: mild dysplasia - 13.3%, 26.7%, 20%, and 0.0%; moderate dysplasia - 33.3%, 13.3%, 40%, and 0.0%; severe dysplasia - 33.3%, 40%, 26.7%, and 0.0%; carcinoma in situ - 6.7%, 13.3%, 6.7%, and 20%; and squamous cell carcinoma - 13.3%, 6.7%, 6.7%, and 80%.

Conclusions: The results showed that the FPME prevented the progress of the malignancy in the OSCC model in rats. However, further investigations are necessary to clarify effective fractions, mode of action of the FPME, and its potential therapeutic application in different types of cancer.

Keywords: *Ferula*, *Persica*, Squamous Cell Carcinoma, 4-Nitroquinoline-1-Oxide

1. Background

Cancer is one of the most significant causes of death around the world. There are 14.1 million new cancer cases, 8.2 million cancer-related deaths, and 32.6 million people living with cancer (within five years of diagnosis) worldwide in 2012 (1), and at the current rate, an estimated 15 million people will be diagnosed annually by 2020 (2). Incidence, mortality, and five-year prevalence of lip and oral cavity cancers are 2.1%, 1.8%, and 2.2% of all cancers, respectively (1). The estimated numbers of new tongue cancer cases and deaths in the United States in 2013 are 13,590 and 2,070, respectively (3). Oral squamous cell carcinoma

(OSCC) represents 90% of all oral malignancies (4).

Despite recent advances in surgical procedures, radiotherapy, and chemotherapy, oral cancer remains a major problem (5). Cancer chemoprevention has been regarded as one of the most efficient strategies to prevent cancer. In recent years, the development of more effective and safer agents has been intensively pursued for the chemoprevention of human cancer, and natural products from plants and their synthetic derivatives are expected to play an important role in creating new and better chemopreventive agents (6). In addition, several chemotherapeutic, cytotoxic, and immunomodulating agents are available in Western medicine to treat cancer. Besides being

enormously expensive, these drugs are associated with serious side effects and morbidity (2).

Nonetheless, the continuing search for an ideal treatment has minimal side effects and is cost-effective. Today, only a limited number of natural products are used to treat cancer. However, some of the widely used anticancer drugs are obtained from medicinal plants (2). Some preclinical studies have suggested that components of plants like garlic and shallot possess anticancer properties including an inhibition of cell proliferation, invasion and metastasis, hormonal stimulation, and stimulatory effects on expression of metabolizing enzymes (7). Furthermore, recent studies have shown that ginger extract owns antioxidant activity (8).

It is worth noting that the exclusively Old World genus *Ferula* belongs to the family Umbelliferae with about 130 species distributed throughout the Mediterranean area and central Asia, especially in Iran (9-12). Many *Ferula* species including *F. assa-foetida* synthesize terpenyloxy coumarins. One of these coumarins is umbelliprenin that has a structure close to that of auraptene (13). The umbelliprenin is a naturally occurring prenylated coumarin that is synthesized by various *Ferula* species (5).

The roots of the *F. persica* are used for the treatment of diabetes, carminative, diuretic, laxative, alexipharmic, digestive, emmenagogue, antispasmodic, hot and dry effects, anti-flatulence, renal calculus, arthralgia, gout, stomach worms, diuretic, and antihysteriain folk medicine (10, 14). In this respect, the *F. assa-foetida* species shows anticarcinogenic properties and affords protection against free-radical-mediated diseases (15). In addition, the umbelliprenin inhibits the red pigment production in *Serratia marcescens* (16) and decreases the MMP activity (13).

The administration of 4-NQO in drinking water can induce tumors in the oral cavities of rats. OSCC, which is induced by 4-NQO in rats' tongues, shows morphological and histopathological similarities to those of human tumors; they are extensively used to investigate and test a wide variety of synthetic and natural agents for their chemopreventive potential (16). The 4-NQO can cause DNA adduct formation and also undergoes redox cycling to produce reactive oxygen species that result in mutations and DNA strand breaks (17, 18). The animal model is considered as the most representative model to examine OSSC. This model is based on the multi-step process of the carcinogenesis that is characterized by initiation, promotion, and tumor progression (19, 20).

2. Objectives

Considering the importance of preventing tongue cancers and evidence about the chemoprotective property of

the *Ferula* species, the aim of the present study was to evaluate the formalin were protective effect of methanolic extract of *Ferula persica* in rat tongue neoplasm induced by 4-NQO.

3. Materials and Methods

This experimental study was carried out in the pharmaceutical research center of the Tabriz University of Medical Sciences, Tabriz, Iran.

3.1. Chemicals

Methanol and formalin were purchased from Merck (Darmstadt, Germany). 4-NQO was purchased from Sigma (Poole, UK).

3.2. Plant Material and Extraction

The roots (500g) of the *F. persica* were obtained from the Khalkhal mountains (Ardabil, Iran). The roots were washed and air-dried and protected from direct sunlight. Afterward, the air-dried roots were ground into a coarse powder, and 300 grams of the powder was extracted by the methanol at $25 \pm 2^\circ\text{C}$. The mixture was also filtered and the solvent completely removed by the rotary vacuum evaporator. Finally, the desired concentration of the extract was prepared. Thus 500 mg of dry matter was resolved in 50 mL of distilled water. Then, 5ml of the prepared solution per kilogram of body weight (50 mg/kg dose) was injected into the rats. Doses of 250 mg and 500 mg were prepared by dilution with distilled water.

3.3. Animals

In this experimental study, pathologic changes between study groups were considered as the primary outcome. According to ethical considerations, the results of the pilot study (five rats in each group) and pathologic changes in 30% of cases with considering $\alpha = 5\%$, $P = 80\%$, and $d = 5\%$, 15 samples for each group were determined.

Sixty male Sprague-Dawley rats weighing 180 ± 20 grams were used for the present study. The animals were housed in polycarbonate standard cages in a temperature-controlled room ($22 \pm 2^\circ\text{C}$) with a 12-hours light/12-hours dark cycle during the experiments. The animals were provided a standard rat pellet diet ad libitum. Drinking water containing the 4-NQO was prepared by dissolving the carcinogen in distilled water three times per week. It was given in light-opaque bottles because the 4-NQO is a synthetic carcinogen derivative of quinoline, soluble in water and sensitive to high temperature and light (21).

3.4. Experimental Design

The animals were randomly divided into four groups (15 animals in each group) as follows:

Group A, B, and C served as the treatment groups and received the 4-NQO at the concentration of 30ppm in their drinking water for 14 weeks. They also intraperitoneally received the FPME at the doses of 50, 250, and 500mg per kilogram of body weight three times per week for 14 weeks respectively.

Group D served as the carcinoma control group and received the 4-NQO at the concentration of 30ppm in drinking water for 14 weeks without any treatment.

All the animals were weighed before and after the experiment; weight changes was calculated for each one of the animals. After ulceration of rats' tongues, which took 14 weeks, the animals were euthanized under anesthetic condition (Pentobarbital, 150 mg/kg IP) (22) for histopathologic evaluation.

3.5. Histological Evaluations

At the end of the interventional period, tongue tissue samples were taken from each animal and were immediately fixed in 10% phosphate-buffered formalin. Then, the samples were embedded in paraffin and 5 μ m thick microscopic sections were prepared. Afterward, the sections were stained by the hematoxylin-eosin staining method. Histological evaluations were performed with light microscopy (Olympus CH30).

Specimens were qualified blindly by two independent observers with an agreement of 92%. Histological slides were evaluated by using a light microscope. In the stained slides, morphological study of epithelium including hyperplasia, hyperkeratosis, drop-shaped rete processes, basal cell hyperplasia, irregular epithelial stratification, nuclear hyperchromatism, increased nuclear-cytoplasmic ratio, increased normal and abnormal mitosis in the basal and suprabasal layer of epithelium, enlarged nucleoli, individual cell keratinization, loss or reduction of cellular cohesion, cellular pleomorphism, and loss of basal cell polarity were determined in the epithelium. Then the samples were scaled as normal, mild dysplasia, moderate dysplasia, severe dysplasia, carcinoma in situ, and squamous cell carcinoma according to Table 2.

3.6. Ethics

All the ethical and humanity considerations were considered and performed according to the Declaration of Helsinki during the experiments and euthanasia of the animals.

This article is the result of research project no. 441 approved by the research committee, Tabriz University of

Medical Sciences, and the ethical considerations have been approved by the ethics committee.

3.7. Data Analyses

Statistical analysis was performed using SPSS 20.0 software.

The weight changes results were expressed as mean \pm SD. The data was analyzed by One-Way Analysis of variance (ANOVA) and repeated measurement of ANOVA was used to compare them. A P value < 0.05 was considered significant. A Fischer's exact test was also used for analyzing the pathological changes, and a P value < 0.001 was considered significant.

4. Results

weight changes in study groups was higher than the non-treated (cancer control) group; however, the differences were not significant $P = 0.18$ (Table 1).

After 14 weeks, ulcers that varied in size were detected in the dorsal of the rats' tongues. Microscopically, morphological alterations on the tongue epithelium were seen. These changes included macroscopic lesions, changes in cell size, and pathological changes. The changes were varied in the tongue tissue samples from mild dysplasia to squamous cell carcinoma; they were significantly different between groups ($P < 0.001$). Table 2 shows frequency and percent of the pathologic changes in different groups.

The histological evaluations of the tissue samples of the cancer control group (i.e., without any treatment) showed severe pathological changes. The squamous cell carcinoma (Figure 1) and the carcinoma in situ (Figure 2) were the changes seen most frequently in this group (80% and 20%, respectively). In the tissue samples of the FPME-treated rats, mild (Figure 3), moderate (Figure 4), and severe dysplasia (Figure 5) were the dominant pathological changes (Table 2).

5. Discussion

Tumorigenesis is a multistep process that involves three phases: tumor initiation, promotion, and progression (2, 23). The oral cancer usually develops in the tongue epithelium during the carcinogenesis pass from hyperplasia through mild to moderate and severe dysplasia before the onset of the OSSC (24, 25).

Similar to previous studies (1), in the present study, the histopathological evaluation of the tongue tissue samples of the cancer control group showed that the OSSC model

Table 1. Weight Changes in Study Groups^aS

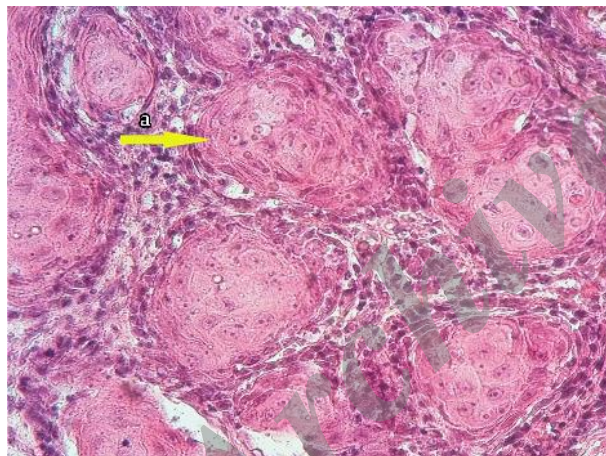
Groups	A	B	C	D	P-Value
Weight Changes After 14 Weeks, grams	27.0 (12.7)	24.7 (10.8)	36.0 (14.5)	17.0 (8.2)	0.18

^aValues are expressed as mean \pm SD.

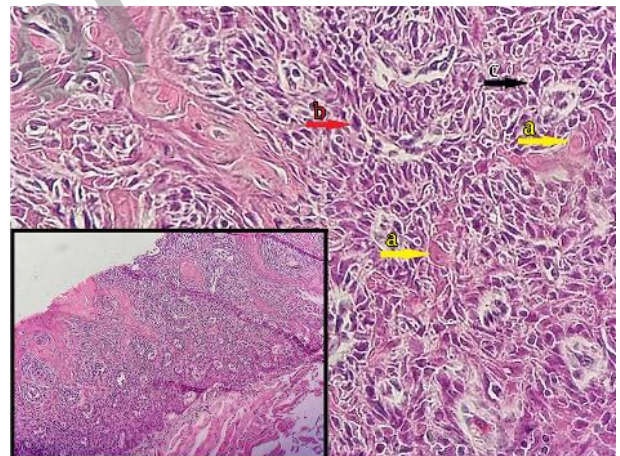
Table 2. Frequency of Pathologic Changes in Tongue Tissues of Study Groups (P < 0.001)^a

Group	Type of Lesion				
	Mild Dysplasia	Moderate Dysplasia	Severe Dysplasia	Carcinoma in situ	OSCC
A	2 (13.3)	5 (33.3)	5 (33.3)	1 (6.7)	2 (13.3)
B	4 (26.7)	2 (13.3)	6 (40.0)	2 (13.3)	1 (6.7)
C	3 (20.0)	6 (40.0)	4 (26.7)	1 (6.7)	1 (6.7)
D	0 (0.0)	0 (0.0)	0 (0.0)	3 (20.0)	12 (80.0)
Total	9 (15.0)	13 (21.7)	15 (25.0)	7 (11.7)	16 (26.7)

^aValues are expressed as No. (%).

Figure 1. Well Differentiated Squamous Cell Carcinoma

Nests of markedly atypical squamous cells invading into the connective tissue (a) (H and E staining, \times 400).

Figure 2. Carcinoma in situ shows full-thickness dysplastic changes in epithelium

Basement membrane is intact (H and E staining, \times 200, lower left figure). The same illustration with high magnification shows dyskeratotic cells (a), mitosis (b), pleomorphism and hyperchromatism (c) (H and E staining, \times 400).

was successfully induced by the 4-NQO in the rats. The 4-NQO-induced OSCC is used to examine various stages of the oral carcinogenesis because of its capability of inducing sequentially the phases of the carcinogenesis (hyperplasia, dysplasia, severe dysplasia, carcinoma in situ, and OSCC) (22). The carcinogenic action of the 4-NQO is initiated by the enzymatic reduction of its nitro group (26). The four-electron reduction product 4-hydroxy-aminoquinoline 1-oxide (4HAQO) is believed to be the proximate carcinogenic metabolite of the 4-NQO. After metabolizing an electrophilic reactant, selyl-4HAQO reacts with DNA and forms

stable quinoline mono adducts such as 3-(deoxyadenosin-N6-yl)-4AQO and N4-(guanosin-7-yl-4AQO) that are responsible for its mutagenicity (17, 25, 26).

The described damage is similar to that caused by the carcinogens that exist in tobacco and that are an important risk factor for oral cancer. On the other hand, the chronic administration of the 4-NQO produces molecular and cellular changes that lead to histopathological changes similar to those seen in human OSCC (27, 28). Therefore, the model of the carcinogenesis in rats is more appropriate to

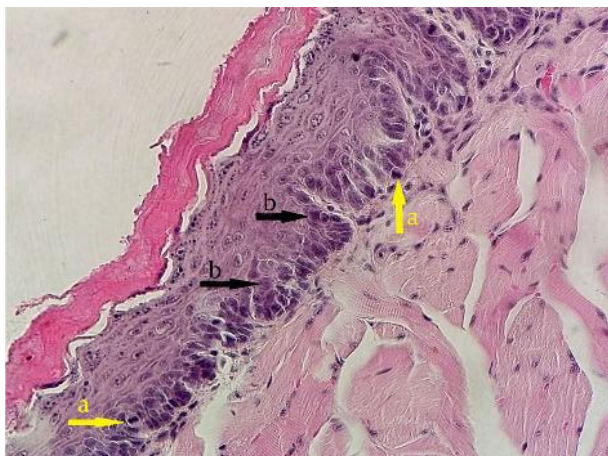


Figure 3. Mild Dysplasia and a Large Amount of Mitosis (a), Nuclear Hyperchromatism and Pleomorphism (b) in Basal and Parabasal Cell Layers (H and E staining, $\times 400$).

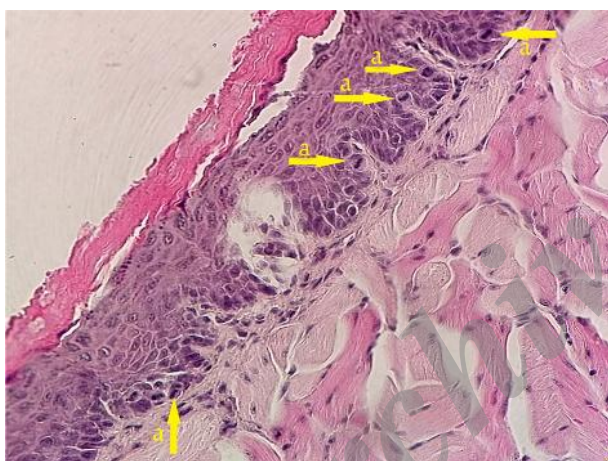


Figure 4. Moderate Dysplasia Shows Architectural Changes Extend Well Into the Middle Third of the Epithelium With Cellular Crowding, Nuclear Hyperchromatism and a Large Amount of Mitosis (a) (H and E staining, $\times 400$).

examine OSSC.

Based on the obtained results, the FPME prevented the progress of the malignancy in the OSSC model in rats. The findings are based on some previous studies: *assa-foetida* (the oleogumresin obtained from some *Ferula* species) could inhibit early events of the carcinogenesis (15). Iran-shahi et al. (6) showed the activity of the diversin from *Ferula diversivittata* in inhibiting the tumor promotion stage in the in-vitro EBV inhibition test. In addition, they indicated that the diversin was also active in an in-vivo two-stage mouse skin carcinogenesis test and concluded that the compound could be valuable as an anti-tumor pro-

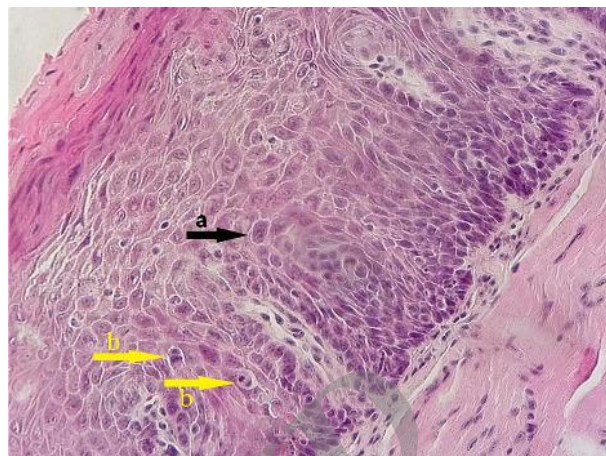


Figure 5. Severe Dysplasia Shows Near Full Thickness Architectural Disorder With Nuclear Pleomorphism (a) and Mitosis (b) (H and E staining, $\times 400$).

motor or as a lead compound for new anti-cancer drug development. They also stated that different *Ferula* species might be good sources of cancer chemopreventive agents (6).

Umbelliprenin is synthesized by various *Ferula* species (6, 12, 13). However, overall, the parent structure of the auraptene and the umbelliprenin, the preferential toxicity of the umbelliprenin for M4Beu cells, and its capacity to decrease the MMP activity and the expression in cancer cells (13) support the hypothesis that the umbelliprenin is orally administered, and foods or folk medicines containing this coumarin may afford protection against the development and recurrence of malignant melanoma in humans with minimal side effects (29).

In addition, the umbelliprenin induces apoptosis in Jurkat cells through caspase-mediated programmed cell death. The umbelliprenin activates intrinsic and extrinsic pathways of the apoptosis through activation of caspase 9 and caspase 8 proteins, respectively (5). In this regard, some evidence also supports that umbelliprenin might afford protection against the development and recurrence of malignant melanoma in humans with minimal side effects (29). Previous studies suggested that umbelliprenin and auraptene compounds of *Ferula* species might be more valuable tumor promoting agents in cases of chemical carcinogenesis, and presence of prenyl moiety on the structure of the umbelliferone nucleus plays an important role in anti-tumor promoting activity (30, 31).

Moreover, the pattern of tumor promotion was slower in mice treated with umbelliprenin compared with the curcumin. Therefore, umbelliprenin might be valuable as a cancer chemopreventive agent (32). This study sug-

gested that umbelliprenin from *Ferula* species acts as an anticancer factor like garlic, shallot, and ginger extracts (7, 8). Because this study was an animal study, we had some limitation on the number of rats. One strong point of the study was the availability of the *F. persica* plant, which is one of the endemic plants in Iran.

5.1. Conclusion

The results of the present study indicate that all doses of the FPME used in the present study caused significant decreases in the severity of the histopathological changes in rat 4-NQO-induced OSCC. However, further investigations are necessary to clarify effective fractions, mode of action of the FPME, and its potential therapeutic application in different types of cancer.

Acknowledgments

The authors thank the members of the drug applied research center for their technical support.

Footnotes

Authors' Contribution: Study concept and design, Amirala Aghbali and Samira Mostafazadeh; histopathological evaluation, Amirala Aghbali, Monir Moradzadeh, and Samira Mostafazadeh; animal study, Mehran Mesgari, Bita Abdollahi, and Soheila Fotoohi; preparation of the herbal extract, Mehrnoosh Janani; writing the manuscript draft, Samira Mostafazadeh; revising of the manuscript, Monir Moradzadeh.

Funding/Support: This study was supported by Tabriz University of Medical Sciences, Tabriz, Iran.

References

- World Health Organization. . Estimated cancer incidence, mortality and prevalence worldwide in 2012. 2012
- Aggarwal BB, Ichikawa H, Garodia P, Weerasinghe P, Sethi G, Bhatt ID, et al. From traditional Ayurvedic medicine to modern medicine: identification of therapeutic targets for suppression of inflammation and cancer. *Expert Opin Ther Targets*. 2006;**10**(1):87-118. doi: [10.1517/14728222.10.1.87](https://doi.org/10.1517/14728222.10.1.87). [PubMed: [16441231](https://pubmed.ncbi.nlm.nih.gov/16441231/)].
- American Cancer Society. Cancer facts and figures. 2013
- Silverman SJ. Demographics and occurrence of oral and pharyngeal cancers. The outcomes, the trends, the challenge. *J Am Dent Assoc*. 2001;**132** Suppl:7S-11S. [PubMed: [11803655](https://pubmed.ncbi.nlm.nih.gov/11803655/)].
- Gholami O, Jeddi-Tehrani M, Iranshahi M, Zarnani AH, Ziai SA. Umbelliprenin from *Ferula szowitsiana* Activates both Intrinsic and Extrinsic Pathways of Apoptosis in Jurkat T-CLL cell line. *Iran J Pharm Res*. 2013;**12**(3):371-6. [PubMed: [24250644](https://pubmed.ncbi.nlm.nih.gov/24250644/)].
- Iranshahi M, Sahebkar A, Hosseini ST, Takasaki M, Konoshima T, Tokuda H. Cancer chemopreventive activity of diversin from *Ferula diversivittata* in vitro and in vivo. *Phytomedicine*. 2010;**17**(3-4):269-73. doi: [10.1016/j.phymed.2009.05.020](https://doi.org/10.1016/j.phymed.2009.05.020). [PubMed: [19577457](https://pubmed.ncbi.nlm.nih.gov/19577457/)].
- Mikaili P, Maadirad S, Moloudizargari M, Aghajanshakeri S, Sarahroodi S. Therapeutic uses and pharmacological properties of garlic, shallot, and their biologically active compounds. *Iran J Basic Med Sci*. 2013;**16**(10):1031-48. [PubMed: [24379960](https://pubmed.ncbi.nlm.nih.gov/24379960/)].
- Mohammadirad A, Aghamohammadali-Sarrafi F, Badii S, Faraji Z, Ha-jiahaee R, Baeeri M, et al. Anti-aging effects of some selected Iranian folk medicinal herbs-biochemical evidences. *Iran J Basic Med Sci*. 2013;**16**(11):1170-80. [PubMed: [24494070](https://pubmed.ncbi.nlm.nih.gov/24494070/)].
- Mandegari A, Sayyah M, Heidari MR. Antinociceptive and anti-inflammatory activity of the seed and root extracts of *ferula gummosa* boiss in mice and rats. 2004 ;**12**:58-62.
- Afifi FU, Abu-Irmaileh B. Herbal medicine in Jordan with special emphasis on less commonly used medicinal herbs. *J Ethnopharmacol*. 2000;**72**(1-2):101-10. [PubMed: [10967460](https://pubmed.ncbi.nlm.nih.gov/10967460/)].
- Abd El-Razek MH, Ohta S, Ahmed AA, Hirata T. Sesquiterpene coumarins from the roots of *Ferula assa-foetida*. *Phytochemistry*. 2001;**58**(8):1289-95. [PubMed: [11738424](https://pubmed.ncbi.nlm.nih.gov/11738424/)].
- Iranshahi M, Arfa P, Ramezani M, Jaafari MR, Sadeghian H, Basarello C, et al. Sesquiterpene coumarins from *Ferula szowitsiana* and in vitro antileishmanial activity of 7-prenyloxycoumarins against promastigotes. *Phytochemistry*. 2007;**68**(4):554-61. doi: [10.1016/j.phytochem.2006.11.002](https://doi.org/10.1016/j.phytochem.2006.11.002). [PubMed: [17196626](https://pubmed.ncbi.nlm.nih.gov/17196626/)].
- Shahverdi AR, Saadat F, Khorramzadeh MR, Iranshahi M, Khoshayand MR. Two matrix metalloproteinases inhibitors from *Ferula persica* var. *persica*. *Phytomedicine*. 2006;**13**(9-10):712-7. doi: [10.1016/j.phymed.2006.01.003](https://doi.org/10.1016/j.phymed.2006.01.003). [PubMed: [16487689](https://pubmed.ncbi.nlm.nih.gov/16487689/)].
- Ahvazi M, Khalighi-Sigaroodi F, Charkhchiyan MM, Mojab F, Mozafarian VA, Zakeri H. Introduction of medicinal plants species with the most traditional usage in alamut region. *Iran J Pharm Res*. 2012;**11**(1):185-94. [PubMed: [24250441](https://pubmed.ncbi.nlm.nih.gov/24250441/)].
- Saleem M, Alam A, Sultana S. Asafoetida inhibits early events of carcinogenesis: a chemopreventive study. *Life Sci*. 2001;**68**(16):1913-21. [PubMed: [11292069](https://pubmed.ncbi.nlm.nih.gov/11292069/)].
- Sohrabi M, Soleimani J, Roshangar L, Vatansever S, Arbabi F, Khaki AA, et al. The effect of dietary and topical celecoxib on 4-nitroquinoline-1-oxide-induced lingual epithelium alternations in rat. *J Pak Med Assoc*. 2009;**59**(11):769-74. [PubMed: [20361677](https://pubmed.ncbi.nlm.nih.gov/20361677/)].
- Phillips DH. Smoking-related DNA and protein adducts in human tissues. *Carcinogenesis*. 2002;**23**(12):1979-2004. [PubMed: [12507921](https://pubmed.ncbi.nlm.nih.gov/12507921/)].
- El-Rouby DH. Histological and immunohistochemical evaluation of the chemopreventive role of lycopene in tongue carcinogenesis induced by 4-nitroquinoline-1-oxide. *Arch Oral Biol*. 2011;**56**(7):664-71. doi: [10.1016/j.archoralbio.2010.12.007](https://doi.org/10.1016/j.archoralbio.2010.12.007). [PubMed: [21216390](https://pubmed.ncbi.nlm.nih.gov/21216390/)].
- Fracalossi AC, Comparini L, Funabashi K, Godoy C, Iwamura ES, Nascimento FD, et al. Ras gene mutation is not related to tumour invasion during rat tongue carcinogenesis induced by 4-nitroquinoline 1-oxide. *J Oral Pathol Med*. 2011;**40**(4):325-33. doi: [10.1111/j.1600-0714.2010.00987.x](https://doi.org/10.1111/j.1600-0714.2010.00987.x). [PubMed: [21226888](https://pubmed.ncbi.nlm.nih.gov/21226888/)].
- Minicucci EM, Ribeiro DA, da Silva GN, Pardini MI, Montovani JC, Salvadori DM. The role of the TP53 gene during rat tongue carcinogenesis induced by 4-nitroquinoline 1-oxide. *Exp Toxicol Pathol*. 2011;**63**(5):483-9. doi: [10.1016/j.etp.2010.03.009](https://doi.org/10.1016/j.etp.2010.03.009). [PubMed: [20385474](https://pubmed.ncbi.nlm.nih.gov/20385474/)].
- Wilkey JF, Buchberger G, Saucier K, Patel SM, Eisenberg E, Nakagawa H, et al. Cyclin D1 overexpression increases susceptibility to 4-nitroquinoline-1-oxide-induced dysplasia and neoplasia in murine squamous oral epithelium. *Mol Carcinog*. 2009;**48**(9):853-61. doi: [10.1002/mc.20531](https://doi.org/10.1002/mc.20531). [PubMed: [19263437](https://pubmed.ncbi.nlm.nih.gov/19263437/)].
- Steffey EP. In: Euthanizing agents. Adams HR, editor. Iowa State University Press; 2001.
- Hahn WC, Weinberg RA. Rules for making human tumor cells. *N Engl J Med*. 2002;**347**(20):1593-603. doi: [10.1056/NEJMra021902](https://doi.org/10.1056/NEJMra021902). [PubMed: [12432047](https://pubmed.ncbi.nlm.nih.gov/12432047/)].
- Sudbo J, Ristimaki A, Sondresen JE, Kildal W, Boysen M, Koppang HS, et al. Cyclooxygenase-2 (COX-2) expression in high-risk premalignant oral lesions. *Oral Oncol*. 2003;**39**(5):497-505. [PubMed: [12747975](https://pubmed.ncbi.nlm.nih.gov/12747975/)].

25. Martinez CAR. 4NQO carcinogenesis: A model of oral squamous cell carcinoma. *Int J Morphol*. 2012;**30**(1):309-14.
26. Arima Y, Nishigori C, Takeuchi T, Oka S, Morimoto K, Utani A, et al. 4-Nitroquinoline 1-oxide forms 8-hydroxydeoxyguanosine in human fibroblasts through reactive oxygen species. *Toxicol Sci*. 2006;**91**(2):382-92. doi: [10.1093/toxsci/kfj161](https://doi.org/10.1093/toxsci/kfj161). [PubMed: [16547075](https://pubmed.ncbi.nlm.nih.gov/16547075/)].
27. Kanojia D, Vaidya MM. 4-nitroquinoline-1-oxide induced experimental oral carcinogenesis. *Oral Oncol*. 2006;**42**(7):655-67. doi: [10.1016/j.oraloncology.2005.10.013](https://doi.org/10.1016/j.oraloncology.2005.10.013). [PubMed: [16448841](https://pubmed.ncbi.nlm.nih.gov/16448841/)].
28. Minicucci EM, da Silva GN, Ribeiro DA, Favero Salvadori DM. No mutations found in exon 2 of gene p16CDKN2A during rat tongue carcinogenesis induced by 4-nitroquinoline-1-oxide. *J Mol Histol*. 2009;**40**(1):71-6. doi: [10.1007/s10735-009-9215-4](https://doi.org/10.1007/s10735-009-9215-4). [PubMed: [19255859](https://pubmed.ncbi.nlm.nih.gov/19255859/)].
29. Barthomeuf C, Lim S, Iranshahi M, Chollet P. Umbelliprenin from *Ferula szowitsiana* inhibits the growth of human M4Beu metastatic pigmented malignant melanoma cells through cell-cycle arrest in G1 and induction of caspase-dependent apoptosis. *Phytomedicine*. 2008;**15**(1-2):103-11. doi: [10.1016/j.phymed.2007.04.001](https://doi.org/10.1016/j.phymed.2007.04.001). [PubMed: [17689942](https://pubmed.ncbi.nlm.nih.gov/17689942/)].
30. Iranshahi M, Kalategi F, Rezaee R, Shahverdi AR, Ito C, Furukawa H, et al. Cancer chemopreventive activity of terpenoid coumarins from *Ferula* species. *Planta Med*. 2008;**74**(2):147-50. doi: [10.1055/s-2008-1034293](https://doi.org/10.1055/s-2008-1034293). [PubMed: [18240102](https://pubmed.ncbi.nlm.nih.gov/18240102/)].
31. Iranshahi M, Askari A, Sahebkar A, Adjipavlou-Litina D. Evaluation of antioxidant, anti-inflammatory and lipoxygenase inhibitory activities of the prenylated coumarin umbelliprenin. *Daru J Pharm Sci*. 2009;**17**:99-103.
32. Iranshahi M, Sahebkar A, Takasaki M, Konoshima T, Tokuda H. Cancer chemopreventive activity of the prenylated coumarin, umbelliprenin, in vivo. *Eur J Cancer Prev*. 2009;**18**(5):412-5. doi: [10.1097/CEJ.0b013e32832c389e](https://doi.org/10.1097/CEJ.0b013e32832c389e). [PubMed: [19531956](https://pubmed.ncbi.nlm.nih.gov/19531956/)].

Archive of SID