

Primary Ovarian Carcinoma Associated with Ovulation Induction: A Case Report

Zahra Asgari,¹ Safoura Rouholamin,^{2,*} Reihaneh Hosseini,¹ and Afsaneh Tehranian¹

¹Department of Obstetrics and Gynecology, School of Medicine, Tehran University of Medical Sciences, Tehran, IR Iran

²Department of Obstetrics and Gynecology, School of Medicine, Isfahan University of Medical Sciences, Isfahan, IR Iran

*Corresponding author: Safoura Rouholamin, Department of Obstetrics and Gynecology, School of Medicine, Isfahan University of Medical Sciences, Isfahan, IR Iran. Tel: +98-9131132616, Fax: +98-2177736647, E-mail: s_rouholamin@med.mui.ac.ir

Received 2015 January 25; Accepted 2015 February 16.

Abstract

Introduction: The relationship between ovulation induction and ovarian cancer is an important issue in gynecology.

Case Presentation: The studied patient was a 32-year-old G1P1 woman with abdominal pain who was diagnosed with a large ovarian cyst during ovulation induction, which could possibly raise the risk of ovarian torsion. She had a 2-year secondary infertility and had received three cycles of ovulation induction with letrozole 6 months earlier. An emergency laparoscopy showed large complex ovarian cysts without torsion. We then performed a cystectomy. Based on the pathology report revealing a primary ovarian cystadenocarcinoma, the patient underwent a total abdominal hysterectomy, bilateral salpingo-oophorectomy, omentectomy, and retroperitoneal lymphadenectomy.

Conclusions: The emergence of a suspected ovarian cyst during letrozole-induced ovulation is of great importance and needs to be investigated.

Keywords: Infertility, Ovulation Induction, Letrozole, Ovarian Cancer

1. Introduction

Ovarian cancers are associated with several risk factors including nulliparity, infertility, early age at menarche, and late menopause (1). Repeated ovulation inductions result in minor trauma to the ovarian epithelium and possibly lead to a malignant transformation (2). There is usually a coexistence of multiple risk factors in patients with infertility. Some studies have suggested that the causes of different types of infertility could increase the risk of ovarian cancer (3). There has been controversy among gynecologists regarding the relationship between the use of fertility drugs and the risk of ovarian cancer. The use of fertility drugs in nulligravida women was associated with borderline serous tumors, but not with invasive histological subtypes (4). Previous studies have focused on clomiphene and gonadotropin therapy. One study has demonstrated that women receiving more than 12 cycles of clomiphene citrate therapy are at a higher risk of having ovarian cancer (5). Multiple large meta-analyses concluded that a sole infertility treatment did not increase the risk of ovarian cancer, and infertility itself was an independent risk factor for epithelial ovarian cancers (3, 6). Letrozole is an aromatase inhibitor that blocks estrogen biosynthesis, suppresses ovarian estradiol secretion, raises follicle-stimulating hormone (FSH) levels, and has been used for ovulation induction (7). The risks of multiple pregnancies, teratogenicity,

and adverse effects on the endometrium caused by letrozole were lower compared with clomiphene citrate (8).

2. Case Presentation

A 32-year-old G1P1 woman was referred to the Gynecologic Laparoscopy Department of Arash women's hospital to rule out ovarian torsion in the right adnexa. She had been suffering from abdominal pain for 2 days and was referred for a surgical consultation.

The patient had been spontaneously pregnant with a full-term baby eight years earlier and had been suffering from secondary infertility for 2 years. She had regular menses and no family history of breast or ovarian cancers. The screening laboratory tests were normal for both the patient and her spouse. A hysterosalpingogram showed a normal uterine cavity with patent tubes. Based on these findings, the couple was selected to undergo intrauterine insemination (IUI) following ovulation induction with letrozole. Vaginal ultrasonography prior to the ovulation induction showed no ovarian abnormalities. In days 3 - 7 of a spontaneous menstrual cycle, the patient received the starting dose of letrozole (2.5 mg/day), but ovulation did not occur. In the second cycle, letrozole was administered at a dose of 5 mg/day over days 3 - 7 of the menstrual cycle. Due to the emergence of six dominant follicles, the second cycle was canceled. In the third cycle, the patient received

the same dose as the second cycle, but due to the development of multiple large follicles, we decided to cancel the human chorionic gonadotropin (HCG) injection and IUI. The patient then experienced menses. A further examination revealed a 48-mm right ovarian cyst with thin septa and low levels of internal echo; therefore, the ovulation induction was delayed until the time of the cyst regression. Vaginal ultrasonography after two months showed a 130 × 92 mm cyst, thick septa, and an irregular border that could have resulted from ovarian torsion (Figure 1).

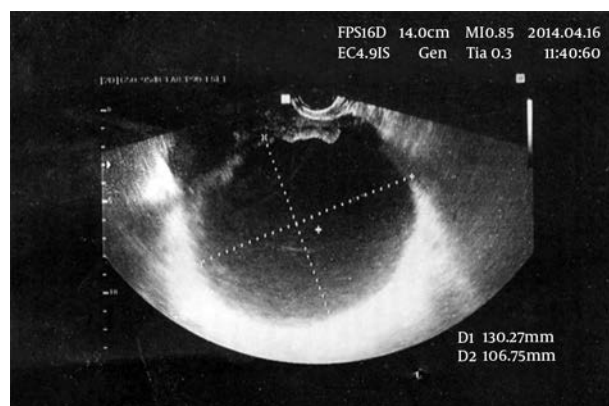


Figure 1. Sonography View of the Large Complex Cyst in the Ovary

The patient was admitted to the emergency ward. Laboratory tests and tumor markers were requested. Physical examination confirmed a dominant abdominal tenderness in the right lower quadrant and a firm mass attached to the uterus was palpated in the lower abdomen. An emergency laparoscopy was performed under general anesthesia to rule out ovarian torsion. Preoperative antibiotics were also injected. A pneumoperitoneum was established using a Veress needle with CO₂ at a maximum intraabdominal pressure of 14 mmHg, and three trocars were used in standard positions. The uterus appeared normal. A suspected complex large right ovarian cyst (12 cm) without torsion and a 4 cm left ovarian cystic mass were observed. Other pelvic and abdominal sites were normal. The cyst was extracted from the abdominal cavity using an Endobag without any perforation of the cyst. The patient was discharged from the hospital after 2 days without any complications. Five days later, the patient's CA-125 was determined to be 230 U/ml (normal range < 35 U/ml). CA19-9 and CEA as carcinoembryonic antigens were at normal ranges. Pathology reported a primary ovarian cystadenocarcinoma and a mucinous type ovary (Figure 2).

An abdominal-pelvic axial computed tomography (CT) scan with intravenous and oral contrast agents showed a large lobulated multiseptated cystic mass in the poste-

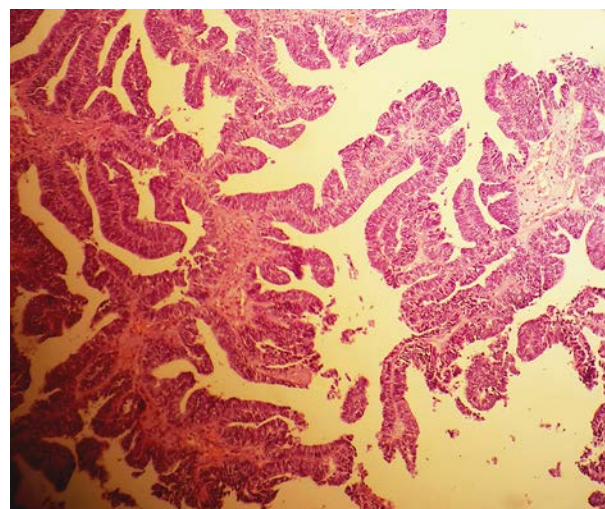


Figure 2. The Histopathology Examination Demonstrates a Papillary Serous Carcinoma of an Ovary

rior cul-de-sac that measured 70 × 35 mm with enhancing septae and an invasion into the mesorectal fat. No ascites was detected. Liver, hepatic bile ducts, gall bladder, kidneys, adrenal glands, spleen, pancreas, stomach, bowels, the omentum, and mesentery were intact. The para-aorta, retroperitoneum, urinary bladder, ischioanal fossa, muscles, and bony skeleton were normal. On laparotomy, a 5-cm left ovarian mass and right ovary without mass were detected. The patient underwent a total abdominal hysterectomy, bilateral salpingo-oophorectomy, omentectomy, and removal of the retroperitoneal lymph nodes. There was no obvious tumor spreading elsewhere in the abdominal cavity. The peritoneal cytology was positive.

The pathologic examination revealed that the endometrium, myometrium, and uterine serosa were not involved and there was no malignancy of the lymph nodes. Based on our findings, the patient was diagnosed with a papillary serous carcinoma of the ovaries, which, according to the FIGO grading system, was determined to be a stage IC.

After the surgery, six cycles of chemotherapy using paclitaxel and carboplatin were conducted without any significant complications.

3. Discussion

This report describes an epithelial ovarian tumor in an infertile woman presenting with an acute abdomen. Ovarian cancer is the fifth most prevalent lethal cancer among women.

A family history of breast or ovarian cancer plays an important role in ovarian cancer, and heritable risk factors are responsible for 5 - 10% of ovarian cancers. Late menopause and infertility increase the risk of ovarian cancer, whereas pregnancy, tubal ligation, oral contraceptives, and hysterectomy reduce the risk (1, 2).

There are two mechanisms regarding these risk factors including incessant ovulation and high levels of gonadotropin, both of which could increase the risk of malignancy in infertile women. One of the main concerns is that ovarian stimulation probably increases the risk of ovarian tumors (2).

In several case-control studies, a higher risk of ovarian cancer was noticed in treated infertile women compared with those who were untreated. The risk is not associated with the type of infertility (9). Ness et al. showed a high risk of borderline serous tumors in nulligravida women taking fertility drugs, however, these drugs did not raise the incidence of invasive serous tumors and other types of ovarian cancers. This risk is not related to the duration of the treatment and does not increase in women with previous pregnancies (4). A meta-analysis later demonstrated that infertility treatments do not independently increase the risk of ovarian cancer, rather, infertility itself is the sole risk factor for ovarian cancers (6, 10, 11).

Most studies have focused on clomiphene and gonadotropin therapy. Letrozole is an aromatase inhibitor used for ovulation induction in women considered to be poor responders and those with breast cancer (12). Letrozole is a member of the drugs that block estrogen biosynthesis, thus, it reduces the negative estrogenic feedback on the pituitary gland and leads to a greater decrease in serum estradiol levels compared with clomiphene citrate (13). Theoretically it seems that letrozole causes fewer side effects such as an increased cancer risk. So far, there has been no report of cancer risk related to letrozole consumption for ovulation induction.

After the administration of an aromatase inhibitor in a premenopausal woman, the dominant follicle grows, estrogen levels increase, and normal negative feedback occurs centrally because aromatase inhibitors do not deplete the brain estrogen receptors. FSH is then suppressed and the smaller-growing follicles become atretic, which result in a monofollicular ovulation in most cases (14, 15). In the present study, the sole consumption of letrozole caused the growth of multiple follicles, thus, indicating the importance of the emergence of new ovarian cysts within the treatment of infertility. Furthermore, due to the adverse outcomes of the third cycle of ovulation induction carried out in this study, it seems that lower letrozole doses could lead to more satisfactory results. Additionally, the conservative management of patients with a complex ovarian

cyst necessitates further examinations in 2 months. This report is one of the rare cases of epithelial ovarian cancer during the sole ovulation induction with letrozole. In this case, it remains vague whether the cancer was present before letrozole consumption or if it was stimulated by the treatment. Based on an ultrasound scan, follicular growth after ovulation induction with letrozole rapidly develops the ovarian malignancy. The emergence of new ovarian cysts in an ovulation induction cycle in infertile women is of great importance and is necessary to rule out the malignancy prior to conservative management.

Conducting further large sample size studies regarding the association between letrozole consumption and ovarian malignancy is recommended.

Acknowledgments

This study was performed in the Tehran University, faculty of medicine.

Footnotes

Authors' Contribution: Zahra Asgari supervised the study. Safoura Rouholamin developed the original idea and wrote the manuscript, and Reihaneh Hosseini and Afshaneh Tehranian drafted the manuscript.

Funding/Support: This work was supported by the Medical Faculty of Tehran Medical University.

References

- Whiteman DC, Murphy MF, Cook LS, Cramer DW, Hartge P, Marchbanks PA, et al. Multiple births and risk of epithelial ovarian cancer. *J Natl Cancer Inst.* 2000;**92**(14):1172-7. [PubMed: 10904091].
- Salehi F, Dunfield L, Phillips KP, Krewski D, Vanderhyden BC. Risk factors for ovarian cancer: an overview with emphasis on hormonal factors. *J Toxicol Environ Health B Crit Rev.* 2008;**11**(3-4):301-21. doi: 10.1080/10937400701876095. [PubMed: 18368558].
- Brinton LA, Lamb EJ, Moghissi KS, Scoccia B, Althuis MD, Mabie JE, et al. Ovarian cancer risk associated with varying causes of infertility. *Fertil Steril.* 2004;**82**(2):405-14. doi: 10.1016/j.fertnstert.2004.02.109. [PubMed: 15302291].
- Ness RB, Cramer DW, Goodman MT, Kjaer SK, Mallin K, Mosgaard BJ, et al. Infertility, fertility drugs, and ovarian cancer: a pooled analysis of case-control studies. *Am J Epidemiol.* 2002;**155**(3):217-24. [PubMed: 11821246].
- Rossing MA, Daling JR, Weiss NS, Moore DE, Self SG. Ovarian tumors in a cohort of infertile women. *N Engl J Med.* 1994;**331**(12):771-6. doi: 10.1056/NEJM199409223311204. [PubMed: 8065405].
- Kashyap S, Moher D, Fung MF, Rosenwaks Z. Assisted reproductive technology and the incidence of ovarian cancer: a meta-analysis. *Obstet Gynecol.* 2004;**103**(4):785-94. doi: 10.1097/01.AOG.0000119226.39514.1d. [PubMed: 15051576].
- Cole PA, Robinson CH. Mechanism and inhibition of cytochrome P-450 aromatase. *J Med Chem.* 1990;**33**(11):2933-42. [PubMed: 2231592].

8. Malloch L, Rhoton-Vlasak A. An assessment of current clinical attitudes toward letrozole use in reproductive endocrinology practices. *Fertil Steril.* 2013;**100**(6):1740-4. doi: [10.1016/j.fertnstert.2013.08.040](https://doi.org/10.1016/j.fertnstert.2013.08.040). [PubMed: [24112529](https://pubmed.ncbi.nlm.nih.gov/24112529/)].
9. Potashnik G, Lerner-Geva L, Genkin L, Chetrit A, Lunenfeld E, Porath A. Fertility drugs and the risk of breast and ovarian cancers: results of a long-term follow-up study. *Fertil Steril.* 1999;**71**(5):853-9. [PubMed: [10231045](https://pubmed.ncbi.nlm.nih.gov/10231045/)].
10. Bristow RE, Karlan BY. Ovulation induction, infertility, and ovarian cancer risk. *Fertil Steril.* 1996;**66**(4):499-507. [PubMed: [8816606](https://pubmed.ncbi.nlm.nih.gov/8816606/)].
11. Mahdavi A, Pejovic T, Nezhat F. Induction of ovulation and ovarian cancer: a critical review of the literature. *Fertil Steril.* 2006;**85**(4):819-26. doi: [10.1016/j.fertnstert.2005.08.061](https://doi.org/10.1016/j.fertnstert.2005.08.061). [PubMed: [16580355](https://pubmed.ncbi.nlm.nih.gov/16580355/)].
12. Mitwally MF, Casper RF. Aromatase inhibition improves ovarian response to follicle-stimulating hormone in poor responders. *Fertil Steril.* 2002;**77**(4):776-80. [PubMed: [11937133](https://pubmed.ncbi.nlm.nih.gov/11937133/)].
13. Requena A, Herrero J, Landeras J, Navarro E, Neyro JL, Salvador C, et al. Use of letrozole in assisted reproduction: a systematic review and meta-analysis. *Hum Reprod Update.* 2008;**14**(6):571-82. doi: [10.1093/humupd/dmn033](https://doi.org/10.1093/humupd/dmn033). [PubMed: [18812422](https://pubmed.ncbi.nlm.nih.gov/18812422/)].
14. Kamat A, Hinshelwood MM, Murry BA, Mendelson CR. Mechanisms in tissue-specific regulation of estrogen biosynthesis in humans. *Trends Endocrinol Metab.* 2002;**13**(3):122-8. [PubMed: [11893526](https://pubmed.ncbi.nlm.nih.gov/11893526/)].
15. Naftolin F. Brain aromatization of androgens. *J Reprod Med.* 1994;**39**(4):257-61. [PubMed: [8040841](https://pubmed.ncbi.nlm.nih.gov/8040841/)].