

Brow Position after Endoscopic Brow Lift

Ali Asghar Rahimi Shahmirzadi,^{1,*} Hamid Reza Fathi,¹ Korosh Ghanbarzadeh,¹ Mohammad Davudov,¹

and Ghasemali Khorasani¹

¹Tehran University of Medical Sciences, Tehran, IR Iran

*Corresponding author: Ali Asghar Rahimi Shahmirzadi, Tehran University of Medical Sciences, Tehran, IR Iran. E-mail: aliasgharshahmirzadi@yahoo.com

Received 2016 November 21; Revised 2017 February 14; Accepted 2017 March 26.

Abstract

Background: Over the past few years, other methods have been replaced by endoscopic forehead rejuvenation. In many cases, it is the treatment of choice and it is widely used for the rejuvenation of the upper third of the face, especially to raise eyebrows.

Objectives: Due to the growing number of cosmetic surgeries and particularly endoscopic surgeries, awareness of the effectivity and longevity of endoscopic surgery appears necessary due to relatively high costs and complications that the patient imposes. There is still ambiguity about changes which appear during aging in the forehead area, however, almost all forehead rejuvenation surgeries are based upon the fact that forehead aging causes eyebrow dropping.

Methods: All patients, who had endoscopic brow lift surgery at Amir Aalam hospital in 2013, were considered in this study. The surgeries were performed at Amir Aalam hospital of Tehran, Iran, by a plastic surgeon and usually on an outpatient basis (day-care basis) and by means of the standard procedures during 1 year. All patients had sub-periosteal endoscopic brow lift surgery, which was performed by 5 separate incisions. Standard photography was performed for all patients with standard views before and after surgery. Complications and surgical techniques were described for the patients in an understandable (simplified) manner. To evaluate the position of the brows before and after surgery, photography was performed before and after the surgery.

Results: Twenty-five patients had an endoscopic brow lift surgery at Amir Aalam hospital, during year 2013. The information and the photography of 20 patients were evaluated. The average age of the patients was 54 years old. Eighteen patients were female and 2 were male. All patients were Iranian. The photographic comparison before and after surgery clearly showed elevation of the brows. On the medial side, the average elevation was 5.25 mm and on the lateral side that was 4.5 mm. In all cases, there were statistically significant differences ($P = 0.001$).

Conclusions: Based on the results of this study, we could conclude that endoscopic forehead rejuvenation surgery, which is used for the rejuvenation of the upper third of the face, has had a clear brow elevation with complete satisfaction in Iranian patients. Most patients (95.2%) were satisfied and only encountered slight side effects.

Keywords: Brow Position, After Endoscopic Brow Lift

1. Background

Due to the growing number of cosmetic surgeries, and particularly endoscopic surgeries, awareness of the effectivity and longevity of endoscopic surgery appears necessary due to relatively high costs and complications that the patient imposes. There is still ambiguity about changes which appear during aging in the forehead area, however, almost all forehead rejuvenation surgeries are based upon the fact that, forehead aging causes some degree of eyebrow dropping (1-8). Over the past few years, other methods have been replaced by endoscopic forehead rejuvenation. In many cases, it has been the treatment of choice and it is widely used for the rejuvenation of the upper third of the face, especially to raise eyebrows (7, 9-12).

There has been much discussion about the results of open and endoscopic forehead rejuvenation. The request of most patients, who visit plastic surgeons for the correction of their upper eyelids, is brow lift (7, 8). The aim is

to improve but not change the appearance of the patient. Lifting eyebrows more than usual can cause an abnormal and permanent surprised face, in fact, looking worse and not better (1, 8). Brow Lift causes the patient to look more alert, more dynamic, and healthy (1, 5, 8, 13-15). This study aimed at answering questions about long-term results of endoscopic forehead rejuvenation surgery.

2. Methods

All patients, who had endoscopic brow lift surgery at Amir Aalam hospital during year 2013 were included in this study. The surgeries were performed at Amir Aalam hospital of Tehran, Iran, by a plastic surgeon and usually on an outpatient basis (day-care basis) and by means of a standard procedure during 1 year. All patients had sub-periosteal endoscopic brow lift surgery, which was performed by 5 separate incisions.

Standard photography with standard views before and after surgery was performed for all patients. Complications and surgical techniques were described to patients in an understandable (simplified) manner.

To evaluate the position of the brows before and after surgery, photographs were taken before and after surgery.

Patients with congenital and acquired diseases around the eyes (peri-orbital) or forehead (frontal) and patients, who for any reason had an incomplete photograph, were excluded from the study.

Distance of the upper border of the eyebrow from intercanthal line in internal and external canthi and the distance of the inner edge of the brows was measured in millimeters. To correct the difference between the photographs before and after surgery, the diameter of the iris was considered as 10 mm. Photographs were taken during 6 to 16 months after surgery.

3. Results

Twenty-five patients had an endoscopic brow lift surgery at Amir Aalam hospital, during year 2013. One of the patients was excluded from the study due to congenital disease, 1 patient due to facial nerve paralysis, and 3 patients due to lack of access and incomplete photography after surgery. Overall, the information and photography of 20 patients were evaluated.

Patient's ages ranged from 40 years to 68 years and the average age was 54 years old. Two patients were male and 18 were female. All patients were Iranian. The comparison of photographs before and after surgery clearly showed elevation of the brows. On the medial side, the average elevation was 5.25 mm and on the lateral side, this was 4.5 mm. In all cases, there were statistically significant differences ($P=0.001$) (Table 1 and Figure 1).

When the results were compared based on the patient's gender, in 18 female patients (90%), the same result was confirmed and in all cases there were statistically significant differences ($P=0.001$) (Table 2 and Figure 2), yet, the results were not statistically significant in males (Table 3 and Figure 3).

When the results were compared based on age, in patients, who were 50 years of age and younger, the previous results were confirmed. Also, in patients, who were older than 50 years of age, the previous results were confirmed, except for the left lateral canthus (Tables 4 - 6, Figures 4 - 6).

All patients had at least 1 plastic surgery before, after or during the endoscopic surgery.

Eighteen patients (90%) had at least 1 surgery, 16 (80%) of which had upper eyelid blepharoplasty and 2 (10%) had blepharoplasty done on all 4 eyelids.

The patient's satisfaction was scored from 1 to 10 by questioning the patients. Nearly all patients were satisfied with the surgery. Complications related to endoscopic surgery were limited and the complications were mostly related to other surgeries.

4. Discussion

There are several procedures for brow lift. Open coronal approach has been considered as the gold standard method for a long time. Other methods are anterior hairline approach, temple approach, transpalpebral approach, and direct suprabrow approach. At this time, endoscopic brow lift was a procedure of choice for brow ptosis (1, 10, 11).

Endoscopy leads to a better understanding of the forehead and temporal anatomy, which is done with 3 to 5 incisions in the scalp and the extent of the forehead dissection is similar to open coronal lift.

The dissection plan in the medial side can be subgaleal, yet, is more subperiosteal. At the beginning, the dissection can be done blindly, yet, near the orbital rim; endoscopic magnification is used to prevent any damage to the nerves. Lateral dissection is done on the deep temporal fascia. In order to prevent damage to the temporal nerve, the sentinel vein and the interior temporal septum was used as a landmark. Then the pockets were connected from the lateral side to the medial side. Soft tissue adhesions were released in the lateral orbital rim and the supraorbital rim. Dissection could be carried over or under the periosteum. During the release of the orbital rim, the supraorbital nerve could be seen. For removal of the glabellar muscles, the supratrochlear nerves were preserved when they passed through the corrugator supercilii muscle. It should be noted that the medial flap should not be widely released so that the eyebrows are not separated from each other and their medial side should not be too high. When dissection is done, the forehead flap is pulled upward and lateral along the appropriate vector.

Some surgeons do not perform fixation. Usually 2 fixation methods are used, including suture fixation, in which the superficial fascia is stitched to the deep temporal fascia in the lateral side, and bony fixation on the medial side (1, 6, 10-12).

The advantages of the endoscopic brow lift are better exposure, shorter scars, magnification, lower risk for alopecia, and reduced scalp sensory changes. It has some disadvantages, including high cost, long learning curve, and technology dependency.

The best patient for endoscopic procedures is someone, who has a short and flat forehead, thick hair, normal skin, and whose hairline has not receded.

Table 1. Parameters of Surgery Outcome

Parameters	Mean ± SD	P Value
Right Lateral (before)	19.85 ± 3.84	0.001
Right Lateral (after)	22.20 ± 3.97	
Right Medial (before)	17.90 ± 3.61	0.001
Right Medial (after)	20.55 ± 3.62	
Left Medial (before)	17.85 ± 3.36	0.001
Left Medial (after)	20.45 ± 3.55	
Left Lateral (before)	20.10 ± 3.54	0.001
Left Lateral (after)	22.35 ± 3.79	
Interbrow Distance (before)	20.30 ± 3.18	0.385
Interbrow Distance (after)	20.5 ± 3.30	

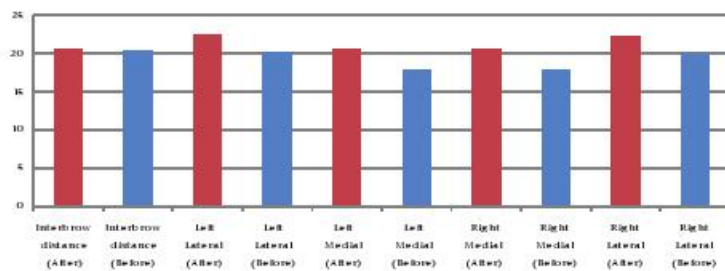


Figure 1. Parameters of Surgery Outcome

Table 2. Parameters of Surgery Outcome in Females

In Female	Mean ± SD	N	P Value
Right Lateral (before)	19.28 ± 2.70	18	0.001
Right Lateral (after)	21.61 ± 3.22	18	
Right Medial (before)	17.28 ± 1.96	18	0.001
Right Medial (after)	19.83 ± 2.50	18	
Left Medial (before)	17.28 ± 1.84	18	0.001
Left Medial (after)	19.72 ± 2.35	18	
Left Lateral (before)	19.50 ± 2.28	18	0.001
Left Lateral (after)	21.78 ± 3.00	18	
Interbrow Distance (before)	20.78 ± 2.90	18	0.361
Interbrow Distance (after)	21.00 ± 3.07	18	

The position and shape of the eyebrow is the result of the interaction of depressor muscles and the only eyebrow elevator, which is the frontalis muscle. The lateral part of the eyebrow is sensitive to this factor because the function of the frontalis muscle on the lateral side reduces, yet, gravity and orbicularis oculi muscle continue pulling it down

and the only resisting force is soft tissue adhesions. The result of this is the gradual ptosis of 1/3 of the lateral eyebrow, which causes a sad, tired, and old look. Most people try to compensate these changes by plucking the eyebrows, makeup, and tattooing.

Proper eyebrow position is on top of the supraorbital

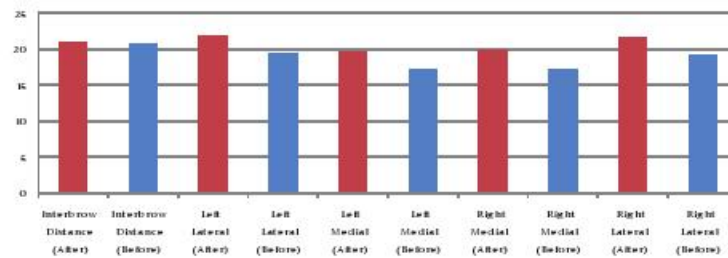


Figure 2. Parameters of Surgery Outcome in Females

Table 3. Parameters of Surgery Outcome in Males

In Men	Mean ± SD	N	P Value
Right Lateral (before)	25.00 ± 9.90	2	0.344
Right Lateral (after)	27.50 ± 7.78	2	
Right Medial (before)	23.50 ± 10.61	2	0.395
Right Medial (after)	27.00 ± 7.07	2	
Left Medial (before)	23.00 ± 9.90	2	0.295
Left Medial (after)	27.00 ± 7.07	2	
Left Lateral (before)	25.50 ± 9.19	2	0.295
Left Lateral (after)	27.50 ± 7.78	2	
Interbrow Distance (before)	16.00 ± 2.83	2	0.999
Interbrow Distance (after)	16.00 ± 1.41	2	

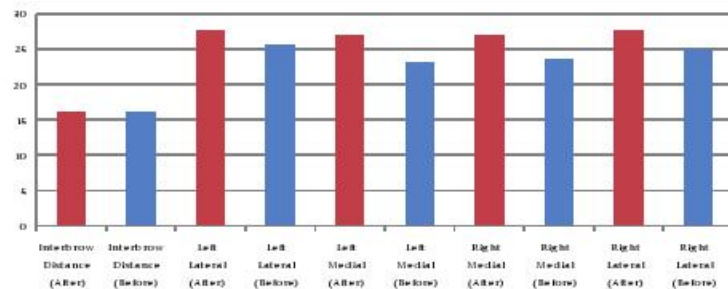


Figure 3. Parameters of Surgery Outcome in Males

rim. However, this is usually right, yet, the eyebrow position has different factors and also its shape is more important than its position.

Identifying the main reason of peri-orbital aging is important and old pictures help in this case.

Studies have shown that brow lift could elevate brows between 0 to 7 mm (1, 6, 16). Although brow lift alone does not cause the patient to look more beautiful, yet, in some studies high eye-brows are considered as a measurement result (outcome) (1, 2, 8, 17-19). Patients want to know the extent of their eyebrow elevation and their appearance after surgery (1, 3, 8). When aesthetic brow surgery is evaluated, the following questions should be addressed:

I. Has Brow lift created a big change? (Was it worth it?)
 II. Has the brow lift stayed?
 III. How will their eyebrows look? (Will they look abnormal?)

Based on the results of this study, it could be concluded that endoscopic forehead rejuvenation surgery, which is used for the rejuvenation of the upper third of the face,

Table 4. Parameters of Surgery Outcome in Patients Younger than Fifty Years of Age

In < 50 y	Mean ± SD	N	P
Right Lateral (before)	20.00 ± 2.28	6	0.007
Right Lateral (after)	22.50 ± 2.66	6	
Right Medial (before)	18.17 ± 2.04	6	0.02
Right Medial (after)	20.67 ± 2.50	6	
Left Medial (before)	17.83 ± 1.83	6	0.02
Left Medial (after)	20.50 ± 2.66	6	
Left Lateral (before)	20.00 ± 2.00	6	0.005
Left Lateral (after)	22.33 ± 2.66	6	
Interbrow Distance (before)	19.17 ± 2.64	6	0.3
Interbrow Distance (after)	19.33 ± 2.25	6	

Table 5. Parameters of Surgery Outcome in Fifty-Year-Old Patients

In 50 y	Mean ± SD	N	P Value
Right Lateral (before)	17.43 ± 3.10	7	0.004
Right Lateral (after)	20.57 ± 3.69	7	
Right Medial (before)	16.14 ± 2.12	7	0.009
Right Medial (after)	19.29 ± 3.25	7	
Left Medial (before)	16.29 ± 2.14	7	0.008
Left Medial (after)	19.43 ± 2.76	7	
Left Lateral (before)	17.86 ± 2.34	7	0.01
Left Lateral (after)	20.86 ± 3.34	7	
Interbrow Distance (before)	21.00 ± 1.29	7	0.2
Interbrow Distance (after)	21.57 ± 0.98	7	

Table 6. Parameters of Surgery Outcome in Patients Older than Fifty Years of Age

In > 50 y	Mean ± SD	N	P Value
Right Lateral (before)	20.00 ± 2.28	7	0.01
Right Lateral (after)	22.50 ± 2.66	7	
Right Medial (before)	18.17 ± 2.04	7	0.015
Right Medial (after)	20.67 ± 2.50	7	
Left Medial (before)	17.83 ± 1.83	7	0.02
Left Medial (after)	20.50 ± 2.66	7	
Left Lateral (before)	20.00 ± 2.00	7	0.1
Left Lateral (after)	22.33 ± 2.66	7	
Interbrow Distance (before)	19.17 ± 2.64	7	0.7
Interbrow Distance (after)	19.33 ± 2.25	7	

has had a clear brow elevation with high satisfaction in Iranian patients. Most patients (95.2%) were satisfied and only

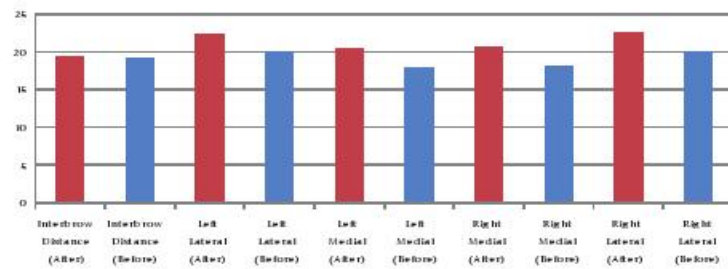


Figure 4. Parameters of Surgery Outcome in Younger than Fifty Years of Age

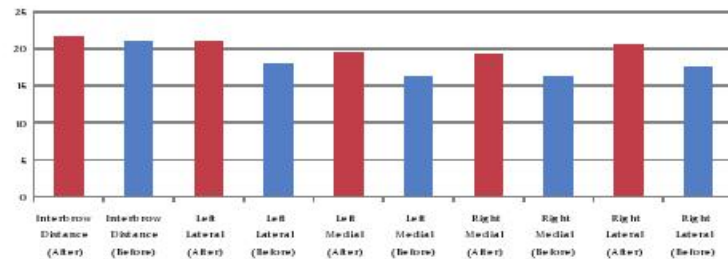


Figure 5. Parameters of Surgery Outcome in Fifty-Year-Old Patients

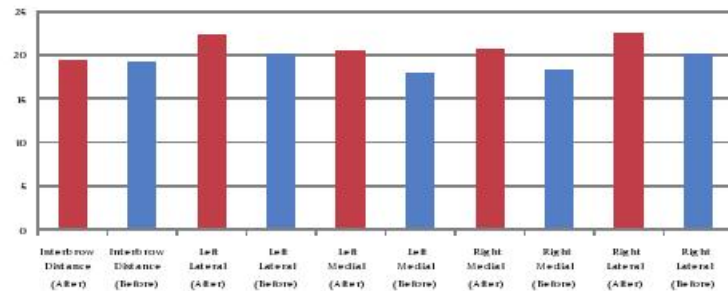


Figure 6. Parameters of Surgery Outcome in Patients Older than Fifty Years of Age

encountered slight side effects. None of the patients complained about the surgery scar. Position of the brows, with 6 to 16 months of follow-up, was highly satisfactory. In the medial side, the average elevation was 5.25 mm and on the lateral side, this was 4.5 mm.

Therefore, the following points are recommended:

- 1) Endoscopic forehead surgery should be more widely used at educational centers so that plastic surgeons gain more experience.
- 2) It appears that the number of patients, who have had endoscopic surgeries is low, so with an increasing sample size, more accurate results can be obtained (Figure 7).

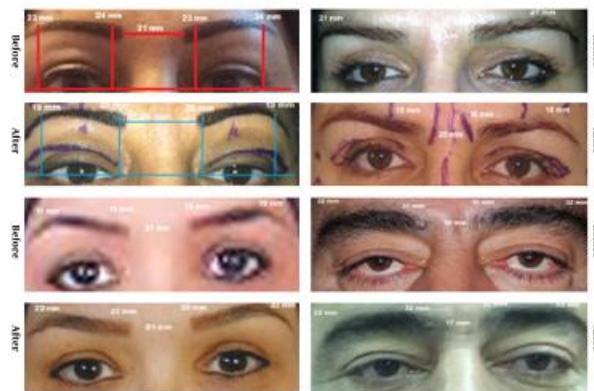

Figure 7. Brow Lift

References

- Jones BM, Lo SJ. The impact of endoscopic brow lift on eyebrow morphology, aesthetic, and longevity: objective and subjective measurements over a 5-year period. *Plast Reconstr Surg.* 2013;**132**(2):226e-38e. doi: [10.1097/PRS.0b013e3182958b9f](https://doi.org/10.1097/PRS.0b013e3182958b9f). [PubMed: 23897351].
- Warren R]. The modified lateral brow lift. *Aesthet Surg J.* 2009;**29**(2):158-66. doi: [10.1016/j.asj.2009.01.011](https://doi.org/10.1016/j.asj.2009.01.011). [PubMed: 19371849].
- Guyuron B. Endoscopic forehead rejuvenation: I. Limitations, flaws, and rewards. *Plast Reconstr Surg.* 2006;**117**(4):1121-33. doi: [10.1097/01.prs.0000202125.19093.b4](https://doi.org/10.1097/01.prs.0000202125.19093.b4). [PubMed: 16582774] discussion 1134-6.
- Keller GS, Mashkevich G. Endoscopic forehead and brow lift. *Facial Plast Surg.* 2009;**25**(4):222-33. doi: [10.1055/s-0029-1242034](https://doi.org/10.1055/s-0029-1242034). [PubMed: 19924595].
- Berkowitz RL, Jacobs DI, Gorman PJ. Brow fixation with the Endotine Forehead device in endoscopic brow lift. *Plast Reconstr Surg.* 2005;**116**(6):1761-7. [PubMed: 16267444] discussion 1768-70.
- Elkwood A, Matarasso A, Rankin M, Elkowitz M, Godek CP. National plastic surgery survey: brow lifting techniques and complications. *Plast Reconstr Surg.* 2001;**108**(7):2143-50. [PubMed: 11743421] discussion 2151-2.
- Iblher N, Manegold S, Porzelius C, Stark GB. Morphometric long-term evaluation and comparison of brow position and shape after endoscopic forehead lift and transpalpebral browpexy. *Plast Reconstr Surg.* 2012;**130**(6):830e-40e. doi: [10.1097/PRS.0b013e31826d9f37](https://doi.org/10.1097/PRS.0b013e31826d9f37). [PubMed: 23190834].
- Byrd HS, Burt JD. Achieving aesthetic balance in the brow, eyelids, and midface. *Plast Reconstr Surg.* 2002;**110**(3):926-33. [PubMed: 12172161] discussion 934-9.
- Graf RM, Tolazzi AR, Mansur AE, Teixeira V. Endoscopic periosteal brow lift: evaluation and follow-up of eyebrow height. *Plast Reconstr Surg.* 2008;**121**(2):609-16. doi: [10.1097/01.prs.0000298111.56163.3b](https://doi.org/10.1097/01.prs.0000298111.56163.3b). [PubMed: 18300981] discussion 617-9.
- Behmand RA, Guyuron B. Endoscopic forehead rejuvenation: II. Long-term results. *Plast Reconstr Surg.* 2006;**117**(4):1137-43. doi: [10.1097/01.prs.0000215331.89085.a6](https://doi.org/10.1097/01.prs.0000215331.89085.a6). [PubMed: 16582776] discussion 1144.
- Thorne CH. The Art of Aesthetic Surgery: Principles and Techniques. *Plast Reconstruct Surg.* 2006;**118**(1):261. doi: [10.1097/01.prs.0000233175.98613.aa](https://doi.org/10.1097/01.prs.0000233175.98613.aa).
- Jones BM, Grover R. Endoscopic brow lift: a personal review of 538 patients and comparison of fixation techniques. *Plast Reconstr Surg.* 2004;**113**(4):1242-50. [PubMed: 15083028] discussion 1251-2.
- Mendelson BC. Facelift anatomy, SMAS, retaining ligaments and facial spaces. *Aesthetic Plastic Surg.* 2009;**6**:1-22.
- Chiu ES, Baker DC. Endoscopic brow lift: a retrospective review of 628 consecutive cases over 5 years. *Plast Reconstr Surg.* 2003;**112**(2):628-33. doi: [10.1097/01.PRS.0000071042.11435.2E](https://doi.org/10.1097/01.PRS.0000071042.11435.2E). [PubMed: 12900626] discussion 634-5.
- Honig JF, Frank MH, Knutti D, de La Fuente A. Video endoscopic-assisted brow lift: comparison of the eyebrow position after Endotine tissue fixation versus suture fixation. *J Craniofac Surg.* 2008;**19**(4):1140-7. doi: [10.1097/SCS.0b013e3181764b19](https://doi.org/10.1097/SCS.0b013e3181764b19). [PubMed: 18650749].
- Klatsky S. Forehead plasty for facial rejuvenation. *J Allergy Clin Immunol.* 2000;**106**(1):eA1. doi: [10.1067/jmaj.2000.110281](https://doi.org/10.1067/jmaj.2000.110281).
- Swiftjr R, Nolan W, Aston S, Basner A. Endoscopic Brow Lift: Objective Results After 1 Year. *Aesthetic Surg J.* 1999;**19**(4):287-92. doi: [10.1053/aq.1999.v19.100009001](https://doi.org/10.1053/aq.1999.v19.100009001).
- Neligan P, Warren R], Van Beek A. Plastic surgery. Elsevier Saunders; 2013.
- Knize DM. Transpalpebral approach to the corrugator supercilii and procerus muscles. *Plast Reconstr Surg.* 1995;**95**(1):52-60. [PubMed: 7809268] discussion 61-2.