

# Serial Polymorphonuclear Predominance of Cerebrospinal Fluid in a Child with Advanced Tuberculous Meningitis: A Case Report

Hadiseh Hosamirudsari,<sup>1,\*</sup> Farhad Afsari,<sup>2</sup> and Farnaz Etesam<sup>3,4</sup>

<sup>1</sup>Assistant Professor of Infectious Diseases, Infectious Diseases Department, Baharloo Hospital, Tehran University of Medical Sciences, Tehran, Iran

<sup>2</sup>Assistant Professor of Neurology, Baharloo Hospital, Tehran University of Medical Sciences, Tehran, Iran

<sup>3</sup>Assistant Professor of Psychiatry, Baharloo Hospital, Tehran University of Medical Sciences, Tehran, Iran

<sup>4</sup>Psychosomatic Research Center, Imam Khomeini Hospital, Tehran University of Medical Sciences, Tehran, Iran

\*Corresponding author: Hadiseh Hosamirudsari, Assistant Professor of Infectious Diseases, Infectious Diseases Department, Baharloo Hospital, Behdardi St., Railway Sq., Tehran University of Medical Sciences, Tehran, Iran. Tel: +98-21556800-11, Fax: +98-2155648189, E-mail: h-hosami@sina.tums.ac.ir

Received 2017 January 29; Revised 2017 March 14; Accepted 2017 April 12.

## Abstract

**Introduction:** Tuberculous meningitis (TBM) is the most fatal form of tuberculosis. Despite adequate treatment, its mortality and morbidity is high. Clinical, laboratory, and radiologic findings help in diagnosis of TBM, although analysis of cerebrospinal fluid (CSF) might sometimes delay and mislead the rapid diagnosis.

**Case Presentation:** We present a 14-year-old Afghan immigrant male, with uncommon laboratory results of advanced TBM, who referred to Baharloo hospital in Tehran, Iran, in September 2016. He experienced headache and anxiety one month prior to referring to the hospital; he had fever, severe headache, vomiting and showed bizarre behavior 7 days before admission. Suspecting meningoencephalitis, the physician advised empirical treatment. The first CSF revealed polymorphonuclear (PMN) predominance with low glucose, which was repeated in the second and third CSF analysis. This pattern indicates early phase of TB meningitis. In day 4, antituberculous treatment with corticosteroid was administered empirically. Unfortunately, he succumbed to disease in day 36. Polymerase chain reaction (PCR) for mycobacterium tuberculosis (MTB) in CSF was positive. The patient's presentation (lethargic to coma) and brain computed tomography (CT) scan indicated advanced stage of disease.

**Conclusions:** All physicians should consider TB meningitis in any patient with low glucose even with serial PMN predominance in CSF.

**Keywords:** CSF, Meningitis, Polymorphonuclear, Tuberculosis

## 1. Introduction

Tuberculosis is the most important worldwide health problem, and meningitis is its gravest form with high mortality and morbidity (1). Meningitis occurs in 1% of tuberculosis cases and its fatality rate is high, 15% to 40%, even with effective treatment. However, without treatment, it raises to 100% (2). In a case series study in Iran that included 96 TBM patients, the overall TBM mortality rate was 22% (3). This is close to the TBM mortality rates reported in other parts of the world. A review on 50 cases of TBM conducted in Denmark found the mortality, morbidity, and cure rates to be 19%, 48%, and 33% (4), indicating the importance of prompt diagnosis and treatment of TBM.

In children, tuberculous meningitis (TBM) usually occurs as post primary tuberculosis, and in adults it is the complication of old foci reactivation due to aging, alcoholism, malnutrition, malignancy, HIV infection, drugs, and head trauma (2).

Most of TBM cases are diagnosed in advanced stages due to its vague presentation in the early phase (5), misinterpretation of disease by physicians, patient's low socioe-

conomic condition, and sometimes rapid progression of TBM (6).

Positive CSF PCR for MTB, Stage 3 TBM, hydrocephalous, and old age are indications of poor prognosis (7) in TBM patients. Therefore, the early diagnosis of TBM and prompt treatment are crucial to prevent its mortality and morbidity. Diagnosis of TBM is based on clinical, radiologic, and laboratory findings, particularly CSF (8).

The studies conducted on the CSF Serial PMN predominance up to the present time have not paid due attention to the advanced form of cerebral TB. The assumption that "Serial PMN dominance of CSF decreases the possibility of cerebral TB occurrence." might lead to negligence of the TB. Therefore, it is necessary to raise the present case. Instead of ruling out TB based on repetition of PMN predominance, the present case focuses on clinical presentation along with hypoglycorrhacia.

## 2. Case Presentation

A 14-year-old Afghan male was admitted to Baharloo hospital in Tehran, Iran, in September 2016. He complained

about severe headache, fever, nausea, and vomiting. He immigrated to Iran 4 months earlier (in May); for one month (from August), he suffered from fever, anxiety, depression, and behavioral changes such as irritability and tearfulness. In several medical visits, he was diagnosed as homesick due to immigration without a diagnostic evaluation of the fever as an accompanying sign. His brother denied any previous disorders or close contact with TB. Also, his family history of tuberculosis was negative.

In the first day of physical examination, he was agitated and complained of severe headache. The patient's BMI was 18.7, and his vital signs were T: 38.8°C, PR: 84/min, RR: 20/min, BP: 130/80 mmHg. Pupillary reflex was 2+ in the right and 3+ in the left side; there was neck stiffness, and plantar reflexes were nonresponsive in both sides. There was no other abnormality.

Suspecting meningoencephalitis, the physician started empirical treatment with ceftriaxone, vancomycin, and acyclovir with corticosteroid. Brain CT scan and lumbar puncture were done.

CSF results in the first day revealed the followings: glucose: 29 mg/dL, blood glucose: 114 mg/dL, protein: 16 mg/dL, WBC: 70/mm<sup>3</sup> (P: 72%, L: 28%). Brain CT scan results showed diffuse edema (Figure 1A). CBC showed the following results: WBC: 7800/mm<sup>3</sup>, Hb: 13.1 g/dL, ESR: 35 mm (Table 1). Chest radiography was normal.

In day 2 of admission, he had fever and headache; CSF analysis revealed glucose: 62 mg/dL, blood glucose: 122 mg/dL, protein: 109 mg/dL, WBC: 60/mm<sup>3</sup> (P: 60%, L: 40%).

In day 4, anti-TB was added to previous treatment because of fever and headache, and low glucose in CSF analysis. CT scan results revealed hydrocephalous periventricular interstitial edema (Figure 1B). His fever subsided 48 hours after anti-TB treatment; ESR and CRP were decreased gradually.

In the seventh day, his consciousness level decreased suddenly and he was intubated. The laboratory investigation for blood cultures, brucellosis, syphilis, HIV, cryptococcus, herpes simplex virus, varicella zoster virus and collagen vascular diseases were negative. There were no evidence for cerebral malaria and typhoid. CSF polymerase chain reaction for MTB was positive. In the sixth day, brain CT scan results showed hypodense lesion with hydrocephalous (Figure 1C). Unfortunately, he died on the 36<sup>th</sup> day.

### 3. Discussion

CNS tuberculosis is the most lethal form of tuberculosis and its mortality is around 100% in untreated cases (1, 9, 10). TB meningitis usually occurs after primary infection

in children; however, in adults it is reactivation of old tuberculous foci (2). There is no evidence of HIV positive, diabetes mellitus, and malignancy that could result in immunosuppression.

The conclusive diagnosis of TBM is based on detection of tuberculous bacilli in CSF through smear and/or culture (11); these were examined in the current case. However, because other causes of PMN predominance of CSF such as bacterial and fungal agents were ruled out by multiplex PCR (Table 1), TBM was considered as almost definite. The cardiac origin of brain abscess has also been ruled out by negative blood cultures.

TBM is categorized into 3 stages in the patient's clinical presentation and imaging. In stage 1, the patient is in early stage, without any focal neurologic deficit. In stage 2, the patient is lethargic or confused with mild focal neurologic deficit. In stage 3, the patient is delirious with advanced TBM (2). Our case was admitted as stage 2 TBM, supported by the positive CSF PCR for MTB.

The most important issue in TBM is its early diagnosis and treatment; without treatment, its fatality rate is around 100%. Meanwhile its major complication is cerebral infarction and disability (9, 12). To diagnose TBM, clinical presentation, imaging, and laboratory data are essential (8). The characteristic feature of CSF in TBM is as follows; high protein, low glucose, and mononuclear pleocytosis. However, PMN predominance can be found in early phase of the disease (2).

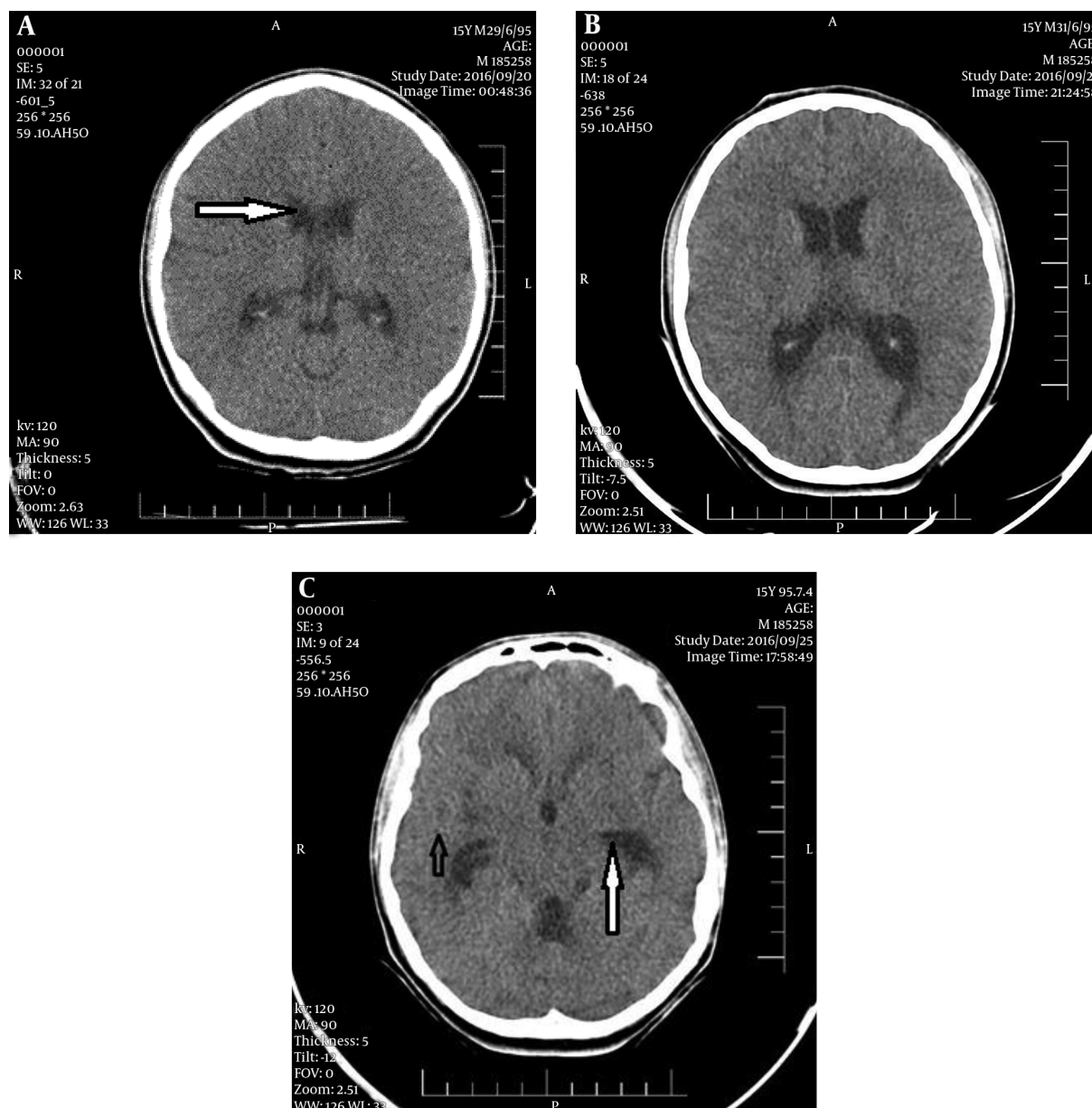
The outstanding feature of our case is that in the first, second, and third CSF analysis, we found PMN predominance that indicated early stage of TBM. In contrast, the CT scan and clinical presentation of the patient showed advanced stage (2, 13). Due to the patient's unstable condition, brain MRI was not done, which could have significantly helped to confirm the diagnosis.

The other feature of this case is the fact that the patient's anxiety and behavioral change (due to TBM) were overshadowed by immigration and diagnosis of homesickness.

According to the experimental researches, homesickness is defined as a complex manifestation of cognitive symptoms such as ruminations and preoccupations about home, social withdrawal in the new environment, and somatic symptoms like weight loss. It has been roughly compared to separation anxiety (excessive anxiety related to separation from home) (14). Children and adolescents, in particular, somatize their mood symptoms regularly, and headaches are one of the known somatic complaints in anxiety and depression. Therefore, there was definitely room for inaccuracies in this case (15).

There remain 2 points that could have helped in differential diagnosis. First, the symptoms appeared about 3

Figure 1. Figure 1



A, the first day brain CT scan showed hydrocephalus (white arrow) and interstitial edema; B, the second day brain CT scan showed progressive hydrocephalus (compared with previous CT); C, brain CT scan in 6<sup>th</sup> day shows hypodense lesion (hollow arrow). The appearance of temporal horn reveals progressive hydrocephalus (white arrow).

months after immigration, even though homesickness can be expressed even before separating from home (14). Fever was a more significant part of the diagnosis because even though it appeared to accompany the symptoms of homesickness, it did not appear regularly in such circumstances. Reviewing the texts suggests changes in mental states, especially in chronic TB meningitis, but few studies have am-

plified these symptoms (16).

Neglecting the background medical condition of a patient checking in with psychiatric symptoms is common. In a study, primary care physicians failed to diagnose underlying physical disorders in 38% of the patients who had psychiatric symptoms, and psychiatrists in 48%. About 50% of psychiatric patients with physical conditions re-

**Table 1.** Variables of the Case

Variables	Results
<b>Signs and symptoms</b>	Severe headache, fever, nausea, vomiting, along with anxiety and depression (1 month ago), anisocoria, neck stiffness
<b>Laboratory results, (first referral lab), First day</b>	CSF (WBC):70 (Poly: 72% Lymph: 28%)
	CSF (glucose) mg/dL: 29
	CSF (protein) mg/dL: 16
	CSF PCR (HSV 1 AND 2): negative
	WBC/mm <sup>3</sup> : 7800 (Poly: 75%, Lymph: 21%)
	Hb g/dL: 13.1
	Plt/mm <sup>3</sup> : 245000
	ESR mm: 35
	blood glucose mg/dL: 114
	blood cultures (3 sets): negative
	PBS (malaria): negative
	HIV-Ab: negative
	<b>Laboratory results (first referral lab), Second day</b>
CSF (glucose) mg/dL: 62	
CSF(protein) mg/dL: 109	
blood glucose mg/dL: 122	
CRP: 80	
<b>Laboratory Result (second referral lab) Eighth days</b>	CSF (WBC): 360 (poly: 96%, lymph; 4%)
	CSF (glucose) mg/dL: 37
	CSF (protein) mg/dL: 198
	CSF (VDRL): negative
	CSF PCR (M. Tuberculosis): Positive
	CSF PCR (Brucella): negative
	CSF PCR (Borrelia Borgdorferi): negative
	CSF PCR (Cryptococcus): negative
	CSF multiplex PCR(bacterial and fungal): negative
	WBC/mm <sup>3</sup> : 8700 (Poly: 88%, Lymph: 10%)
	Hb g/dL:12.9
Plt/mm <sup>3</sup> : 198000	
ESR mm: 35	
blood glucose mg/dL: 101	
<b>Radiographic changes</b>	Normal chest radiography
	Brain CT scan: hypodense lesion, progressive hydrocephalia in short period

mained undiagnosed as to the underlying medical illness (17). These findings show the importance of diagnostic workup of the patients with psychiatric symptoms, particularly when they appear with atypical representations.

In conclusion, any low glucose CSF analysis should be

considered as TB meningitis even with serial PMN predominance. Further studies to assess the manifestations of tuberculosis in the brain would also assist in early diagnosis and management of patients.

## Acknowledgments

Dr. Sandip Chatterjee, Dr. S.G. Srikanth and Dr. Ming-Hsun Lee are thanked for their constructive comments, which significantly improved this manuscript. The editor in chief is gratefully acknowledged for valuable comments and handling of the manuscript.

## Footnotes

**Conflict of Interests:** There is no conflict of interest.

**Funding/Support:** This research did not receive any specific grant from funding agencies in the public, commercial, or not-for-profit sectors.

## References

1. Andronikou S, Smith B, Hatherhill M, Douis H, Wilmshurst J. Definitive neuroradiological diagnostic features of tuberculous meningitis in children. *Pediatr Radiol*. 2004;**34**(11):876-85. doi: [10.1007/s00247-004-1237-1](https://doi.org/10.1007/s00247-004-1237-1). [PubMed: [15378213](https://pubmed.ncbi.nlm.nih.gov/15378213/)].
2. Leonard J. Tuberculous meningitis. 2017
3. Ahmadinejad Z, Ziaee V, Aghsaefar M, Reiskarami SR. The prognostic factors of tuberculous meningitis. *Internet J Infect Dis*. 2003;**3**(1).
4. Sali S, Valipour N. An unusual presentation of tuberculous meningitis. *Arch Clin Infect Dis*. 2015;**10**(3) doi: [10.5812/archcid.26083](https://doi.org/10.5812/archcid.26083).
5. Radmanesh F, Nejat F, El Khashab M. Cerebral infarction as the first presentation of tuberculosis in an infant: a case report. *J Microbiol Immunol Infect*. 2010;**43**(3):249-52. doi: [10.1016/S1684-1182\(10\)60039-4](https://doi.org/10.1016/S1684-1182(10)60039-4). [PubMed: [21291854](https://pubmed.ncbi.nlm.nih.gov/21291854/)].
6. Miftode EG, Dorneanu OS, Leca DA, Juganariu G, Teodor A, Hurmuzache M, et al. Tuberculous Meningitis in Children and Adults: A 10-Year Retrospective Comparative Analysis. *PLoS One*. 2015;**10**(7):e0133477. doi: [10.1371/journal.pone.0133477](https://doi.org/10.1371/journal.pone.0133477). [PubMed: [26186004](https://pubmed.ncbi.nlm.nih.gov/26186004/)].
7. Hsu PC, Yang CC, Ye JJ, Huang PY, Chiang PC, Lee MH. Prognostic factors of tuberculous meningitis in adults: a 6-year retrospective study at a tertiary hospital in northern Taiwan. *J Microbiol Immunol Infect*. 2010;**43**(2):111-8. doi: [10.1016/S1684-1182\(10\)60018-7](https://doi.org/10.1016/S1684-1182(10)60018-7). [PubMed: [20457427](https://pubmed.ncbi.nlm.nih.gov/20457427/)].
8. Srikanth SG, Taly AB, Nagarajan K, Jayakumar PN, Patil S. Clinicoradiological features of tuberculous meningitis in patients over 50 years of age. *J Neurol Neurosurg Psychiatry*. 2007;**78**(5):536-8. doi: [10.1136/jnnp.2006.095620](https://doi.org/10.1136/jnnp.2006.095620). [PubMed: [17220292](https://pubmed.ncbi.nlm.nih.gov/17220292/)].
9. van Well GT, Paes BF, Terwee CB, Springer P, Roord JJ, Donald PR, et al. Twenty years of pediatric tuberculous meningitis: a retrospective cohort study in the western cape of South Africa. *Pediatrics*. 2009;**123**(1):e1-8. doi: [10.1542/peds.2008-1353](https://doi.org/10.1542/peds.2008-1353). [PubMed: [19367678](https://pubmed.ncbi.nlm.nih.gov/19367678/)].
10. Chatterjee D, Radotra BD, Vasishta RK, Sharma K. Vascular complications of tuberculous meningitis: An autopsy study. *Neurol India*. 2015;**63**(6):926-32. doi: [10.4103/0028-3886.170086](https://doi.org/10.4103/0028-3886.170086). [PubMed: [26588628](https://pubmed.ncbi.nlm.nih.gov/26588628/)].
11. Chatterjee S. Brain tuberculomas, tubercular meningitis, and post-tubercular hydrocephalus in children. *J Pediatr Neurosci*. 2011;**6**(Suppl 1):S96-S100. doi: [10.4103/1817-1745.85725](https://doi.org/10.4103/1817-1745.85725). [PubMed: [22069437](https://pubmed.ncbi.nlm.nih.gov/22069437/)].
12. Chen CH, Chang YJ, Sy HN, Chen WL, Yen HC. Risk assessment of the outcome for cerebral infarction in tuberculous meningitis. *Rev Neurol (Paris)*. 2014;**170**(8-9):512-9. doi: [10.1016/j.neurol.2014.06.004](https://doi.org/10.1016/j.neurol.2014.06.004). [PubMed: [25194476](https://pubmed.ncbi.nlm.nih.gov/25194476/)].
13. Thwaites GE, Macmullen-Price J, Tran TH, Pham PM, Nguyen TD, Simmons CP, et al. Serial MRI to determine the effect of dexamethasone on the cerebral pathology of tuberculous meningitis: an observational study. *Lancet Neurol*. 2007;**6**(3):230-6. doi: [10.1016/S1474-4422\(07\)70034-0](https://doi.org/10.1016/S1474-4422(07)70034-0). [PubMed: [17303529](https://pubmed.ncbi.nlm.nih.gov/17303529/)].
14. Stroebe M, Schut H, Nauta M. Homesickness: A systematic review of the scientific literature. *Rev Gen Psychol*. 2015;**19**(2):157-71. doi: [10.1037/gpr0000037](https://doi.org/10.1037/gpr0000037).
15. Hankin BL. Adolescent depression: description, causes, and interventions. *Epilepsy Behav*. 2006;**8**(1):102-14. doi: [10.1016/j.yebeh.2005.10.012](https://doi.org/10.1016/j.yebeh.2005.10.012). [PubMed: [16356779](https://pubmed.ncbi.nlm.nih.gov/16356779/)].
16. Katti MK. Pathogenesis, diagnosis, treatment, and outcome aspects of cerebral tuberculosis. *Med Sci Monit*. 2004;**10**(9):RA215-29. [PubMed: [15328498](https://pubmed.ncbi.nlm.nih.gov/15328498/)].
17. Cosci F, Fava GA, Sonino N. Mood and anxiety disorders as early manifestations of medical illness: a systematic review. *Psychother Psychosom*. 2015;**84**(1):22-9. doi: [10.1159/000367913](https://doi.org/10.1159/000367913). [PubMed: [25547421](https://pubmed.ncbi.nlm.nih.gov/25547421/)].