

Solitary Rectal Ulcer Syndrome in a Young Patient: A Case Report

Mengting Ruan,¹ Yichi Zhang,¹ Zhenning Feng,¹ Bo Qu,¹ Mingzi Han,¹ and Shizhu Jin^{1*}

¹Department of Gastroenterology and Hepatology, the Second Affiliated Hospital, Harbin Medical University, Harbin, China

*Corresponding author: Shizhu Jin, Department of Gastroenterology and Hepatology, the Second Affiliated Hospital, Harbin Medical University, 148 Baojian Road, Harbin, China. Tel: +86-13654699988, E-mail: drshizhujin@126.com

Received 2016 December 09; Revised 2017 March 21; Accepted 2017 April 29.

Abstract

Introduction: Solitary rectal ulcer syndrome (SRUS) is rarely observed in young people and its clinical manifestations and endoscopic observations in young patients are atypical. Except for histopathological observations, SRUS can be hardly differentiated from other bowel diseases such as rectal carcinoma or ulceration.

Case Report: The current report presented a case of SRUS in an 18-year-old male living in Harbin, China. The patient complained of gastrointestinal hemorrhage and abdominal pain as his first symptoms. SURS was diagnosed after colonoscopy supported by his complete recovery following the treatment with Etiasa. Issues relevant to the diagnosis and treatment of SURS were discussed in the current article.

Conclusions: Employment of colonoscopy is a great help in the early diagnosis of SURS; thus, this technique has benefits for the treatment and recovery of patients.

Keywords: Gastrointestinal Hemorrhage, Prolapse, Rectal Diseases, Ulcer

1. Introduction

Solitary rectal ulcer syndrome (SRUS) is an uncommon benign disease of the rectum in the mucosal prolapse syndromes (MPS). The main clinical manifestations of SRUS include abdominal pain, hematochezia, constipation, tenesmus as well as some generic abdominal conditions. A similar description of these clinical manifestations was first written by Cruveilhier (1). Most of the SRUS cases are under 50 years old, typically between 30 and 50 years, with the annual incidence rate of 0.001% (2). Cases in children and adolescents are very rare. The incidence rates in males and females are approximately the same, although some articles reported that females are more prone to be affected (2).

The diagnosis of SRUS is mainly based on the clinical manifestation, endoscopic observation, and histopathological examination. The endoscopic appearance includes singular or multiple ulcerations, and/or irregular polypoid lesions on the luminal surface of rectum. Some researchers suggested that the term of SRUS may not be appropriate (3). It is difficult to differentiate SRUS from rectal cancer or other rectum ulcerative diseases by the sole observations under a colonoscopy. The etiology of SRUS remains to be elucidated. Some perspective studies suggest that SRUS may be associated with unhealthy life habits or the use of enema. Pathological changes surrounding SRUS include ischemic injury of rectal mucosa, rectal prolapse, perineal descent, or self-digitation. Paradoxical contraction of the pelvic floor, external anal sphincter, and abdominal pres-

sure may also contribute to the formation of ischemic injury of rectal mucosa (4). The available treatment plans for SRUS are various and controversial. Here is reported a case of SRUS in an 18-year-old patient.

2. Case Report

An 18-year-old male patient came to the outpatient facility and complained of intermittent abdominal pain and hematochezia for 2 months in 2014. Abdominal examination showed no obvious abnormalities. Routine blood test, biochemical indicators, tumor markers, and fecal routine examinations were normal (Table 1). There was no history of colorectal cancer and other bowel diseases in his family. The first colonoscopy was implemented on December 3, 2014. It revealed a pattern of lesions in the rectum with exudate and dirtiness covering the surface of the lesions (5 cm from anus). The base of lesion was like a white spot with a hard texture, and it easily bled in response to a light touching. A provisional diagnosis of rectal cancer was made on the basis of the above observations under the colonoscopy and 7 pieces of tissue sample from the lesion were processed for biopsy. The results showed inflammatory cell infiltration, fibroblasts in the lamina propria, elastic fibers, and smooth muscle hyperplasia, suggesting the existence of mucosal prolapse syndrome. One month later, the second colonoscopy was performed on the patient, which showed the same lesions as observed at the first time. The biopsy of the lesioned tissue samples from

the second colonoscopy showed inflammatory exudation, fibroblasts in the lamina propria, and smooth muscle cells hyperplasia. Considering the results of the biopsy and colonoscopy, a final diagnosis of SRUS was made. The Etiasa (1000 mg q, 6 hours per os) was prescribed from January to Mar 2015. Then, the third colonoscopy was performed after 3 months treatment with Etiasa. The images of the colonoscopy showed superficial ulcers and scar formation on the luminal surface of the rectum (5 cm from anus), with a small amount of purulent secretions attached to the surface of lesion, and the ulcer margin looked like "chicken skin". Biopsy of tissue samples showed chronic inflammation of the mucous membranes, exudation of inflammatory and necrosis, and mild atypical hyperplasia of glands. The lesions in the rectum had improved significantly, as indicated by narrow band imaging (NBI). More significantly, the patient's symptoms of hematochezia, abdominal pain, constipation, and other symptoms were also alleviated. Therefore, the treatment dosage of Etiasa was adjusted to 1000 mg q 8, hours per os until complete remission of the symptoms. Then, the dosage of Etiasa was adjusted to 1000 mg, bid per os for another 3 months, according to his symptoms without colonoscopy. In 2016, a follow-up colonoscopy examination was performed on the patient. The images of this colonoscopy showed that the mucosal tissue had returned to normal conditions and there was no significant ulceration in the rectum (Figure 1). During the treatment by Etiasa, the patient did not present any other symptoms.

All the equipment used for the patient was calibrated regularly by experts in the relevant departments of the hospital. Therefore, no correction was made to all the data described in the current case.

3. Discussion

SRUS is a rare benign condition where individuals experience difficult defecation. It is characterized by mucosal prolapse, tenesmus, rectal bleeding, constipation, and the passage of mucus, or rectal pain. The patient in the current case predominately experienced abdominal pain and gastrointestinal hemorrhaging. Previously, SRUS and MPS were not considered as separate conditions. In recent articles, however, SRUS is categorized as a type of MPS, whereas MPS is classified as a category of the bowel diseases consisting of rectal prolapse, inflammatory cap polyp, proctitis cystica profunda (PCP), inflammatory cloacogenic polyp, inflammatory myoglandular polyp, and SRUS (4, 5). Both MPS and SRUS may share the same clinical pathological features.

The etiology of SRUS may be associated with certain lifestyles, the Sjogren syndrome (6), spinal cord injury (7),

Table 1. Clinical Laboratory Results of the Current Case

		Results
Routine blood test	White blood cell	7.8 (4.0 - 10.0) × 10 ⁹ /L
	Hemoglobin, g/L	142 (110 - 160)
	Hematocrit, %	40.8 (37.0 - 50.0)
	Platelet	302 (100 - 300) × 10 ⁹ /L
Biochemical indicators	Alanine aminotransferase, U/L	23 (0 - 40)
	Aspartate aminotransferase	16 (0 - 40)
	Albumin, g/L	48.9 (35.0 - 55.0)
	Creatinine, uM/L	88 (44 - 110)
	Glucose, mM/L	5.95 (3.90 - 6.10)
	K ⁺ , mM/L	3.67 (3.50 - 5.50)
	Na ⁺ , mM/L	143.3 (135.0 - 145.0)
	Cl ⁻ , mM/L	105.6 (101.0 - 111.0)
	Ca ²⁺ , mM/L	2.25 (2.10 - 2.80)
	Total cholesterol, mM/L	3.37 (1.80 - 5.17)
Triglyceride, mM/L	1.56 (0.56 - 1.70)	
Fecal routine examination	Fecal occult blood	Negative (negative)
	Fecal red blood cell	0/HP
	Fecal white blood cell	0/HP
	Fecal ovum	0/HP
Tumor markers	Cancer embryo antigen, ng/mL	2.89 (< 5)
	Carbohydrate antigen 125, U/mL	18.60 (< 35)
	Carbohydrate antigen 153, U/mL	13.80 (< 31.3)
	Carbohydrate antigen 199, U/mL	< 2.00 (< 37)
	Squamous cell carcinoma antigen, ng/mL	1.0 (0.0 - 1.5)
	Alpha-fetoprotein, ng/mL	1.52 (0.89 - 8.78)

pregnancy (8), enema use or insertion of suppositories (9), and living habits such as the use of bidets (10), staying in the bathroom for a long time using a stream of water, or cleaning the inside part of rectal as far as possible. The patient of the current report did not have any one of the above mentioned living habits, and did not drink alcohol and smoke. He rarely ate fruits and vegetables and had constipation for several years, which is a risk factor for SRUS as reviewed above. Ischemic injury of rectal mucosa is recognized as the main mechanism of SRUS, in addition to rectal

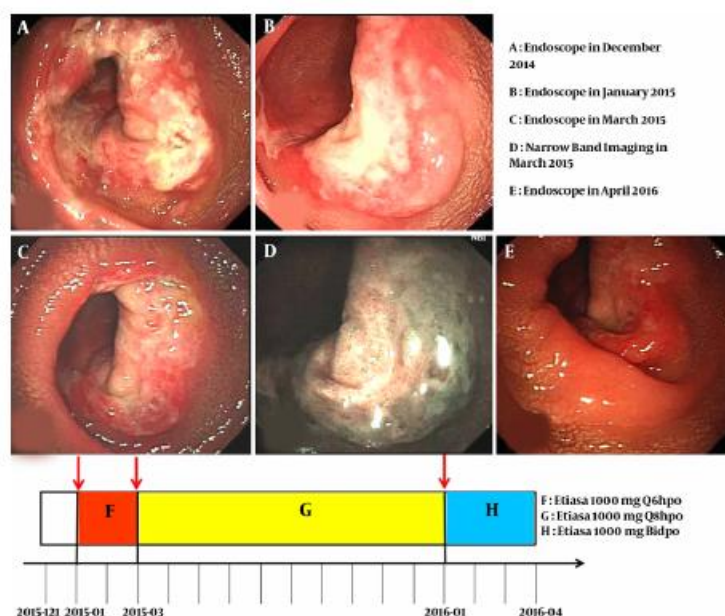


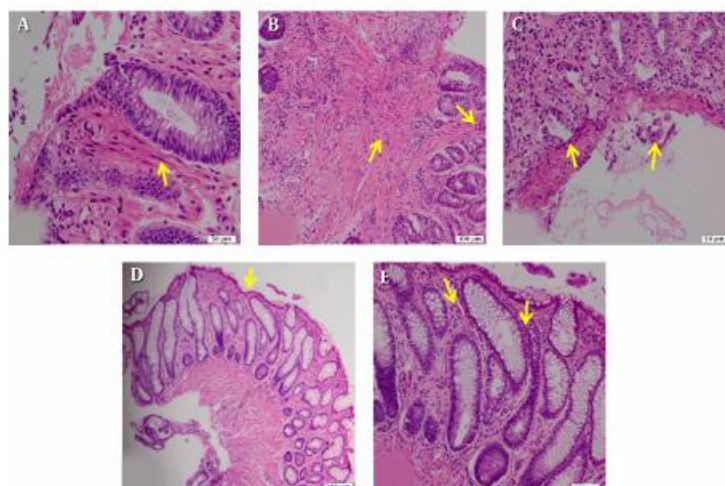
Figure 1. The Endoscopic Images of the Patient at the Indicated Time Points Used to Adjust the Dosage of Etiasa, Recovery Process Follow-Up, and Adjust the Treatment Plan for the Patient.

prolapse, perineal descent, or self-digitation. The reasons for ischemic injury of rectal mucosa include paradoxical contraction of the pelvic floor, external anal sphincter, and abdominal pressure.

It is hard to distinguish SRUS from other bowel diseases such as rectal cancer, inflammatory bowel disease (IBD), ischemic bowel disease, inflammatory polyps, hyperplastic polyps, or other kinds of MPS under endoscopic images. In the current case, the blood routine test showed that white blood cells and hemoglobin levels were normal, indicating that the patient did not have infections or unusual gastrointestinal bleeding; biochemical tests concluded that liver functions, renal function, hydronium, and glucose were normal; and there was no indication of tumor; fecal routine examinations presented normal results, confirming that the patient did not have abnormal bleeding and stool infection. Deep irregular ulcerations were observed on the luminal surface of rectum about 5 cm from the anal verge under the endoscopy. The preliminary diagnosis of the current case was rectal cancer according to the endoscopic images. To confirm this diagnosis, some pieces of lesions were taken for tissue biopsy. In some articles, chromoendoscopy was suggested as a possible method to diagnose SRUS as this method can reveal concentric circular lesion, which is similar to annual tree-ring signs. The number of concentric circles was proportional to the duration of SRUS (11).

The gold standard of SRUS is the histopathological findings. Histopathologic examination of the tissue biopsy in the current case showed fibromuscular obliteration of the lamina propria, smooth muscle cells in the lamina propria, disorientation of muscle fibers, extension of fibromuscular tissue into the lamina propria, thickened and splayed muscularis mucosa, extension of glands into the submucosal layer, hyperplastic and serrated mucosa, crypt distortion as well as distorted mucosal glands (Figure 2). Together with the findings under colonoscopy, the patient was diagnosed with SRUS. In the current case, the SRUS was diagnosed through images of colonoscopy combined with the classic pathological images. However, in certain references, some professors supported the use of chromoendoscopy as an important method to diagnose SRUS. Unfortunately, chromoendoscopy was not used in the current case. Besides, no other auxiliary examinations such as X-rays and barium enema were taken to get a preliminary feeling of intestinal morphology.

The current available treatment options for SRUS include adjusting dietary habits and lifestyles to avoid prolapsing and minimize straining of the bowel system. Consuming a high-fiber diet and developing a good life style are of help; pharmacologic treatment with bulking agents such as docusate sodium, hydrocortisone enema, sucral-fate and mesalamine is the dominant therapy. If the drug treatment is non-effective, human fibrin sealant, laser

Figure 2. The Histopathologic Observations of the Patient

A, Fibromuscular obliteration of the lamina propria, smooth muscle cells in the lamina propria; B, Disorientation of muscle fibers (left arrow); extension of fibromuscular tissue into the lamina propria (right arrow); C, Thickened and splayed muscularis mucosa (left arrow); extension of glands into the submucosal layer (right arrow); D, Hyperplastic and serrated mucosa; E, Crypt distortion, mucosal glands distortion.

therapy, and balloon dilation should be suggested; even surgery if the surgical indications are fulfilled. The preferred surgical approaches are rectopexy, excision, and the Delorme procedure (2). New treatment modalities include biofeedback and other therapies (12). SRUS is a reversible disease and can be self-healing. In clinical practices, different treatment plans can be selected according to the patient's individual indications and advantages. In the current case, after the diagnosis of SRUS, the patient was treated with Etiasa for about 15 months and endoscopy examination was applied for each stage to adjust the dose of Etiasa as mentioned above. The viewpoints on the curative effect of Etiasa are different. Some experts believe that corticosteroid and mesalazine are ineffective in SRUS (2); whereas others hold the opposite point that mesalazine has beneficial effects on SRUS (7). Only a single drug was used for treatment of the current case and at the same time, the patient was asked to change his undesirable lifestyle to avoid constipation, and to shorten the time spent in the washroom. This suggestion was made as some references explained that the prognosis of SRUS was closely related to a change of lifestyles. Therefore, authors are still uncertain about the role of treatment with Etiasa and lifestyle changes and their share in correlation with the healing process. Data were confidential in the current report and the colonoscopy images could not be presented. The patient was asked for permission to show the picture in the current report. At the same time, the colonoscopy examinations were taken by the same doctor and the rectal biopsies were reviewed by 1 specific pathologist.

In conclusion, SRUS is a benign and reversible disease with the symptoms of abdominal pain, bloody stool, and other atypical symptoms. There are no typical clinical characteristics of SRUS; therefore, it is easy to misdiagnose it with other diseases such as IBD, colorectal carcinoma, etc. Colonoscopy and histopathology could be the standard diagnosis for SRUS. However, from one aspect, the doctors should have a sense of suspicion about SRUS and be alert about the patient if he/she has gastrointestinal hemorrhages. Furthermore, the patient should understand this kind of disease; hence, they can better help themselves and bring awareness to others. On the other hand, the patient should keep healthy living habits to avoid constipation or rectal prolapse and go to the hospital for symptomatic treatment. Etiasa is the first line drug to treat SRUS, although other drugs also show therapeutic effects at various degrees.

Acknowledgments

The authors are grateful to the patient who was willing and allowing them to share the case report. Authors also appreciate the help of Dr. Haiyun Xu, a professor of Shantou University Medical College, with revising the manuscript, and the assistance of the pathologist, Yufei Jiao, MD, PhD, the second affiliated hospital of Harbin Medical University, Harbin, Heilongjiang, China.

Footnote

Authors' Contribution: Study concept and design: Shizhu Jin; acquisition of data: Yichi Zhang and Zhenning Feng; analysis and interpretation: Bo Qu; drafting of the manuscript: Mengting Ruan; critical revision of the manuscript for important intellectual content: Mengting Ruan; administrative, technical, and material support: Mingzi Han; study supervision: Shizhu Jin.

References

1. Sakuta M. [One hundred books which built up neurology (35)-Cruveilhier J "Anatomie Pathologique du Corps Humain"(1829-1842)]. *Brain Nerve*. 2009;**61**(11):1354-5. [PubMed: 19938693].
2. Zhu QC, Shen RR, Qin HL, Wang Y. Solitary rectal ulcer syndrome: clinical features, pathophysiology, diagnosis and treatment strategies. *World J Gastroenterol*. 2014;**20**(3):738-44. doi: 10.3748/wjg.v20.i3.738. [PubMed: 24574747].
3. Tjandra JJ, Fazio VW, Church JM, Lavery IC, Oakley JR, Milsom JW. Clinical conundrum of solitary rectal ulcer. *Dis Colon Rectum*. 1992;**35**(3):227-34. [PubMed: 1740066].
4. Abid S, Khawaja A, Bhimani SA, Ahmad Z, Hamid S, Jafri W. The clinical, endoscopic and histological spectrum of the solitary rectal ulcer syndrome: a single-center experience of 116 cases. *BMC Gastroenterol*. 2012;**12**:72. doi: 10.1186/1471-230X-12-72. [PubMed: 22697798].
5. Brosens LA, Montgomery EA, Bhagavan BS, Offerhaus GJ, Giardiello FM. Mucosal prolapse syndrome presenting as rectal polyposis. *J Clin Pathol*. 2009;**62**(11):1034-6. doi: 10.1136/jcp.2009.067801. [PubMed: 19861563].
6. Koga H, Shimizu K, Tarumi K, Sadahira Y, Matsumoto T, Iida M, et al. Rectal mucosal prolapse syndrome as an unusual gastrointestinal manifestation of Sjogren's syndrome: a case report. *J Med Case Rep*. 2009;**3**:85. doi: 10.1186/1752-1947-3-85. [PubMed: 19946561].
7. Wang F, Frisbie JH, Klein MA. Solitary rectal ulcer syndrome (colitis cystica profunda) in spinal cord injury patients: 3 case reports. *Arch Phys Med Rehabil*. 2001;**82**(2):260-1. doi: 10.1053/apmr.2001.16341. [PubMed: 11239322].
8. Sood SK, Garner JP, Amin SN. Spontaneous resolution of solitary rectal ulcer syndrome during pregnancy: report of a case. *Dis Colon Rectum*. 2008;**51**(7):1149-52. doi: 10.1007/s10350-008-9268-6. [PubMed: 18392597].
9. Urganc N, Kalyoncu D, Usta M, Eken KG. A rare cause of severe rectal bleeding: solitary rectal ulcer syndrome. *Pediatr Emerg Care*. 2014;**30**(10):736-8. doi: 10.1097/PEC.0000000000000239. [PubMed: 25275355].
10. Miura T, Kimura K, Sato Y, Kanai N. Rectal mucosal prolapse syndrome and a bidet. *Pediatr Int*. 2003;**45**(4):467-8. [PubMed: 12911486].
11. Ninomiya Y, Oh EH, Mizuno M. The annual tree ring sign: a new endoscopic finding of mucosal prolapse syndrome. *Gastrointest Endosc*. 2013;**78**(4):657. doi: 10.1016/j.gie.2013.06.001. [PubMed: 23849820] discussion 658.
12. Rao SS, Ozturk R, De Ocampo S, Stessman M. Pathophysiology and role of biofeedback therapy in solitary rectal ulcer syndrome. *Am J Gastroenterol*. 2006;**101**(3):613-8. doi: 10.1111/j.1572-0241.2006.00466.x. [PubMed: 16464224].