

# Gastrointestinal Stromal Tumor Associated with Myasthenia Gravis: A Case Report

Laurentiu Nedelcu,<sup>1,2,\*</sup> and Teodora Dumitrescu<sup>2</sup>

<sup>1</sup>Department of Internal Medicine and Medical Semiology, University Transylvania, Brasov, Romania

<sup>2</sup>Department of Internal Medicine, Emergency County Hospital, Brasov, Romania

\*Corresponding author: Laurentiu Nedelcu, Department of Internal Medicine and Medical Semiology, University Transylvania, Brasov, Romania. E-mail: laumedelcu@yahoo.com

Received 2017 February 18; Revised 2017 March 14; Accepted 2017 March 29.

## Abstract

**Introduction:** Gastrointestinal stromal tumors (GIST) represent less than 1% of all gastrointestinal tumors. The GIST diagnosis in a patient with a newly discovered myasthenia gravis (MG) raises the problem of evolution and treatment.

**Case Presentation:** We present the case of a 58-year-old patient, who has been diagnosed with MG on December 2015 at emergency clinical county hospital Brasov, Romania. After further investigations, a localized gastric GIST was discovered. The treatment was surgical (January 2016) and the one-year evolution after the surgery was without relapse. Genetic mutations in the KIT and PDGFR genes were investigated.

**Conclusions:** GIST may be accidentally discovered in asymptomatic patients. Genetic mutation examinations are needed in order to provide evidence. MG in association with GIST is rare and raises problems of diagnosis and treatment.

**Keywords:** Gastrointestinal Stromal Tumors, Myasthenia Gravis, Mutations

## 1. Introduction

GIST represents 1% of all gastrointestinal tumors, however, they are the most common mesenchymal tumors of the digestive system. They can appear in any segment of the digestive system, but most frequently, in the stomach (aprox. 60%) and small intestine (aprox. 30%). Other locations, such as the large intestine, the anorectal region, the pancreas, and the esophagus, are rare. They most commonly occur in adults between 40 and 70 years old, without any geographical or ethnical differences, and they develop from the myenteric ganglion cells called the interstitial cells of Cajal (1).

The GIST name was first used in 1983 by Mazur and Clark (2) who histologically reevaluated a series of gastric wall tumors that were considered to be leiomyomas or leiomyosarcomas. Their source was likely to have been represented by the myenteric ganglion cells (2).

Endoscopic biopsy and laparoscopic excision are the first steps in the diagnosis. The histological diagnosis will continue with an immunohistochemistry (Over 95% of GIST have c-kit expression with diffuse cytoplasmic staining pattern) and molecular biology. The diagnosis of GIST is confirmed by the mutational analysis for known mutations involving KIT and PDGFRA (3). An important step in the understanding of the molecular mechanisms was the discovery of a KIT protein and its mutations (4). This discovery allowed the individualization of GIST. The KIT pro-

tein is a tyrosine kinase receptor, similar to the platelet-derived growth factor alpha receptor (PDGFRA). The activation of one of these receptors is involved in the pathogenesis of GIST (5). Tyrosine kinase inhibitors suppress the signal and reduce the proliferation of tumor cells. These findings have led to the introduction of tyrosine kinase inhibitors in the GIST treatment as adjuvant therapy after the complete resection and for the treatment of unresectable and recurrent GIST (6). Approximately 10% of GIST does not harbor any mutation of the KIT and PDGFRA genes. These GISTs are designated as "KIT/PDGFRA-wild type" or just "wild type" GIST (7).

## 2. Case Presentation

We present the case of a 58-year-old male patient that presented himself to our clinic on December 2015 for a daily fluctuating muscular weakness, accentuated by effort, and relieved by rest. The patient has difficulties in walking long distances and climbing stairs. These symptoms first appeared 2 months ago and during the last week the patient also presented chewing disorders.

In the patient's history there was an episode of upper gastrointestinal bleeding (melena) in 2013, which was attributed to the consumption of 3 Ketoprofen pills (non-steroidal anti-inflammatory). The upper gastrointestinal endoscopy performed in our clinic revealed a gastric polyp on the posterior gastric wall, near the gastric angle. The

histological examination reveals a normal gastric mucosa with a moderate chronic inflammatory, diffuse lymphoplasmatic infiltrate.

The neurological examination performed on December 2015 reveals a typical myasthenia face: immobile, expressionless, with a mild bilateral ptosis, mastication difficulties, and mild to strong swallowing disorders. Proximal muscle strength is low in the upper and lower limbs. There are no signs of atrophy and no sensitivity or coordination problems.

The electromyography performed at "Neuroptics Med" clinic Bucharest revealed a postsynaptic myasthenia block. The value of the acetylcholine receptor antibodies (AChR) was increased: 23.625 nmol/L (normal value < 0.400 nmol/L). The muscle-specific antibodies against the tyrosine kinase (MuSK) were negative: < 0.01 U/mL (reference range < 0.4 U/mL). The test was performed by an accredited medical laboratory of the German Limbach laboratory group.

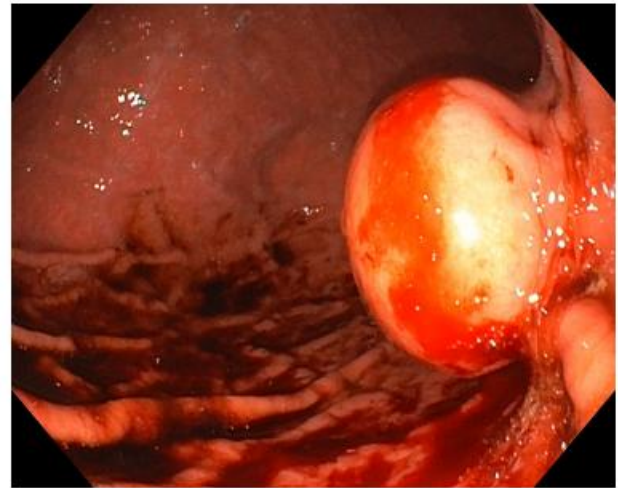
The patient's symptoms, neurological, electrophysiological examinations, and the titer of the acetylcholine receptor antibodies sustain the generalized, Class III A, myasthenia gravis diagnosis. According to the Myasthenia Gravis American Foundation, the III A class is defined by limb and axial muscles problems, usually with a lesser involvement of the oropharyngeal muscles (8).

No connections with other autoimmune diseases - such as thyrotoxicosis (TSH = 1.60 mIU / L, FT4 = 1.29 ng / dL), systemic lupus erythematosus, rheumatoid arthritis, Sjogren's syndrome, and polymyositis were found.

Since MG and Lambert-Eaton myasthenia syndrome (LEMS) can accompany malignancies (9, 10), we have expanded the investigations. The thorax computer tomography scan excluded a thymoma or a lung cancer. Given the clinical history (upper gastrointestinal bleeding) and the need for the initiation of the corticosteroid treatment, a decision for an upper and a lower gastrointestinal endoscopy was made. A 3 cm polypoid gastric tumor was discovered on the posterior gastric wall. It had a wide implantation base, a top cord, and erosions on the surface (Figures 1 and 2). The endoscopic aspect and long-term evolution sustained a GIST diagnosis. An exploratory laparoscopy and an atypical laparoscopic resection of the gastric great curvature was performed on February 2016.

The gastric resection piece was histopathologically analyzed. The dimensions were 4/2, 5/4 cm. It was protrusive, had an elastic consistency, extended outside the exterior stomach wall, and was covered by the serous layer. Typical mitosis were present (2 mitosis / 50 high power fields). Immunohistochemically, the tumor cells are intensely positive, and the proliferation index is 5%. The histological aspect is that of a gastric stromal tumor (GIST) with a low ma-

**Figure 1.** I.M., 58 Years Old, Aspect Within the Endoscopy



Polypoid gastric tumor on the posterior gastric wall.

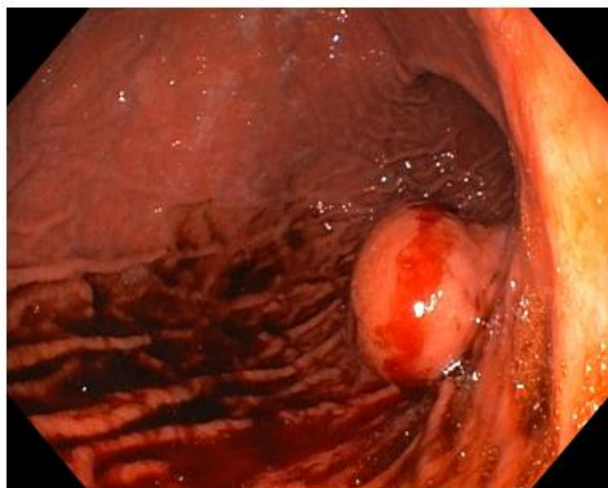
lignant potential. The pTNM classification is pT2 pNx pMx.

The molecular genetic study for detecting mutations in the cKIT and PDGFR genes has detected the mutation c.2525 A > T - p. (Asp842Val) in the PDGFRFA gene at the 18th exon. No mutations were detected in the cKIT gene in the 9,11,13,17 exons and in the PDGFR gene in the 12,14 exons. The patient was informed and an informed consent was signed (11). The detection was performed by "personal genetics" bucharest using next generation sequencing (NGS). The testing was confirmed by The institute of pathologic and genetics Gosselies-Charleroi, Belgium.

One year after the surgery, the patient's condition was favorable. The cancer screening was negative and the upper gastrointestinal endoscopy detected no modifications. The patient was also taken into neurological care and he continued the administration of the cortisone treatment with an obvious improvement of the myasthenic syndrome.

### 3. Discussion

The GIST diagnosis was established after investigating a patient with MG, that presented upper gastrointestinal bleeding 2 years ago. In that moment, a gastric polyp was described and the histological examination did not evoke the possibility of a GIST diagnosis. The digestive bleeding was presumed to be caused by the consumption of NSAIDs. There is a high probability that the former described polyp is actually a GIST. The "polyp" localisation on the posterior gastric wall was identical with that of the stromal tumor.

**Figure 2.** I.M., 58 Years Old, Aspect Within the Endoscopy

Polypoid gastric tumor on the posterior gastric wall.

The possibility of a paraneoplastic syndrome was taken into consideration, due to MG-GIST association. The peripheral nervous system can be affected in the paraneoplastic syndrome at the muscles, peripheral nerves, and neuromuscular junction.

Impaired neuromuscular junction has been described (12) in MG and LEMS. This usually occurs in the small cell lung cancer. The thorax CT scan excludes a lung tumor and the antibodies against the calcium channels type P / Q are negative (18.6 pmol / L). In approximately 10% - 15% of patients with MG, especially in younger people, a thymoma has been discovered. Therefore, MG can be considered as the most common paraneoplastic manifestation in patients with thymoma. The examined patient had no thymoma. Other MG associated tumors have not been described. For this reason, without having other arguments, we can consider that the association MG-GIST is a random one.

The risk stratification of patients with GIST is based on the location of the tumor, its size, and its mitotic index (13). For gastric localisation, a tumor, between the size of 2 and 5 cm, and a mitotic index  $< 5/50$  hpf, has a very low risk - 1.9% (5).

Genetic studies show that 85% of GIST have active mutations in the protooncogenes KIT, 3% - 5% have PDGFRA mutations, and a small amount are mutation free. The examined patient has a rare mutation in the PDGFRA gene at the 18th exon.

The curative treatment of GIST is a surgical one, with the complete resection of the tumor. The mutation description allowed the emergence of therapies that have a

direct action upon the protooncogenes KIT / PDGFRA. Imatinib mesylate is a tyrosine selective molecular kinase inhibitor, originally used in the treatment of the chronic myelogenous leukemia. Its introduction in the GIST therapy increased the survival rate in patients with relapses and those with unresectable or metastatic tumors. The regulatory authorities in the United States of America and Europe have allowed the use of imatinib mesylate. Thus, in 2002, the Food and Drug Administration approved its use in the metastatic GIST and in 2008 its use as an adjuvant therapy after the complete resection of a GIST. The European Medicines Agency approves the use of imatinib mesylate in the resected GIST, that are KIT positive, and with an increased risk (14). A future problem is the identification of mutations with a high risk of relapse. It was reported that only KIT exon 11 deletions genes are associated with an increased risk of relapse (15). GIST with KIT exon 9 mutations had higher response rates to the treatment with imatinib mesylate (16).

Other therapeutic options are represented by Sunitinib and Regorafenib. Sunitinib is considered to be the standard second-line treatment recommended for patients with metastatic GIST or with imatinib intolerance (17). A study published in The Lancet analyzed the efficiency and safety of regorafenib in patients with unresectable or metastatic GIST with a previous ineffective treatment with imatinib and sunitinib (18).

This case study has some limitations: the missing of immunohistochemical picture and the delayed diagnosis of GIST. We were able to perform the molecular genetic study for detecting mutations in the cKIT and PDGFR genes. This is a positive point in the management of the patient.

### 3.1. Conclusions

We presented the case of a newly diagnosed patient with MG, which simultaneously presents a surgically resected GIST with a low risk and a PDGFRA mutation in the 18th exon. The patient's 1 year evolution after the resection is favorable. No tyrosine kinase inhibitors were administered. The association of MG with GIST is not common. A paraneoplastic syndrome was excluded. The management of the patient was complete from clinic to genetic; the treatment was adequate. The evolution is favorable after 1 year. The patient entered a surveillance program that requires clinical examination, upper gastrointestinal endoscopy, and abdominal CT scan at every 6 months.

### Acknowledgments

We thank Synevo Romania, Santomar Oncodiagnostic Cluj Romania, Neuroptics Med. Bucharest Romania,

personal genetics Bucharest Romania, the institute of pathologic and genetics Gosselies-Charleroi Belgium, German Limbach laboratory group, as well as Doctor Bogdan Moldovan from Brasov Romania for their support.

### Footnote

**Authors' Contribution:** Laurentiu Nedelcu collected, analyzed the data, and supervise the manuscript; Teodora Dumitrescu has prepared and edited the documentation.

### References

1. Cichoż-Lach H, Kasztelan-Szczerbinska B, Słomka M. Gastrointestinal stromal tumors: epidemiology, clinical picture, diagnosis, prognosis and treatment. *Pol Arch Med Wewn.* 2008;**118**(4):216-21. [PubMed: 18575421].
2. Mazur MT, Clark HB. Gastric stromal tumors. Reappraisal of histogenesis. *Am J Surg Pathol.* 1983;**7**(6):507-19. [PubMed: 6625048].
3. E. SMO/European Sarcoma Network Working Group. Gastrointestinal stromal tumours: ESMO Clinical Practice Guidelines for diagnosis, treatment and follow-up. *Ann Oncol.* 2014;**25** Suppl 3:iii21-6. doi: 10.1093/annonc/mdu255. [PubMed: 25210085].
4. Tan CB, Zhi W, Shahzad G, Mustacchia P. Gastrointestinal stromal tumors: a review of case reports, diagnosis, treatment, and future directions. *ISRN Gastroenterol.* 2012;**2012**:595968. doi: 10.5402/2012/595968. [PubMed: 22577569].
5. Heinrich MC, Corless CL, Duensing A, McGreevey L, Chen C, Joseph N, et al. PDGFRA activating mutations in gastrointestinal stromal tumors. *Science.* 2003;**299**(5607):708-10. doi: 10.1126/science.1079666. [PubMed: 12522257].
6. Songdej N, von Mehren M. GIST treatment options after tyrosine kinase inhibitors. *Curr Treat Options Oncol.* 2014;**15**(3):493-506. doi: 10.1007/s11864-014-0295-3. [PubMed: 24952730].
7. Wada R, Arai H, Kure S, Peng WX, Naito Z. "Wild type" GIST: Clinicopathological features and clinical practice. *Pathol Int.* 2016;**66**(8):431-7. doi: 10.1111/pin.12431. [PubMed: 27427238].
8. Jaretzki A3, Barohn RJ, Ernstoff RM, Kaminski HJ, Keeseey JC, Penn AS, et al. Myasthenia gravis: recommendations for clinical research standards. Task Force of the Medical Scientific Advisory Board of the Myasthenia Gravis Foundation of America. *Neurology.* 2000;**55**(1):16-23. [PubMed: 10891897].
9. Tarr TB, Wipf P, Meriney SD. Synaptic Pathophysiology and Treatment of Lambert-Eaton Myasthenic Syndrome. *Mol Neurobiol.* 2015;**52**(1):456-63. doi: 10.1007/s12035-014-8887-2. [PubMed: 25195700].
10. van Sonderen A, Wirtz PW, Verschuuren JJ, Titulaer MJ. Paraneoplastic syndromes of the neuromuscular junction: therapeutic options in myasthenia gravis, lambert-eaton myasthenic syndrome, and neuromyotonia. *Curr Treat Options Neurol.* 2013;**15**(2):224-39. doi: 10.1007/s11940-012-0213-6. [PubMed: 23263888].
11. Purcaru D, Preda A, Popa D, Moga MA, Rogozea L. Informed consent: how much awareness is there? *PLoS One.* 2014;**9**(10):e110139. doi: 10.1371/journal.pone.0110139. [PubMed: 25329168].
12. Rees JH. Paraneoplastic syndromes: when to suspect, how to confirm, and how to manage. *J Neurol Neurosurg Psychiatry.* 2004;**75** Suppl 2:ii43-50. [PubMed: 15146039].
13. Sobin LH, Compton CC. TNM seventh edition: what's new, what's changed: communication from the International Union Against Cancer and the American Joint Committee on Cancer. *Cancer.* 2010;**116**(22):5336-9. doi: 10.1002/cncr.25537. [PubMed: 20665503].
14. Roggin KK, Posner MC. Modern treatment of gastric gastrointestinal stromal tumors. *World J Gastroenterol.* 2012;**18**(46):6720-8. doi: 10.3748/wjg.v18.i46.6720. [PubMed: 23239909].
15. Corless CL, Ballman KV, Antonescu C, Blanke CD, Blackstein ME, Demetri GD, et al. Relation of tumor pathologic and molecular features to outcome after surgical resection of localized primary gastrointestinal stromal tumor (GIST): Results of the intergroup phase III trial ACOSOG Z9001. *J Clinical Oncol.* 2010;**28**(15\_suppl):10006. doi: 10.1200/jco.2010.28.15\_suppl.10006.
16. Heinrich MC, Owzar K, Corless CL, Hollis D, Borden EC, Fletcher CD, et al. Correlation of kinase genotype and clinical outcome in the North American Intergroup Phase III Trial of imatinib mesylate for treatment of advanced gastrointestinal stromal tumor: CALGB150105 Study by Cancer and Leukemia Group B and Southwest Oncology Group. *J Clin Oncol.* 2008;**26**(33):5360-7. doi: 10.1200/JCO.2008.17.4284. [PubMed: 18955451].
17. Mulet-Margalef N, Garcia-Del-Muro X. Sunitinib in the treatment of gastrointestinal stromal tumor: patient selection and perspectives. *Oncotargets Ther.* 2016;**9**:7573-82. doi: 10.2147/OTT.S101385. [PubMed: 28008275].
18. Demetri GD, Reichardt P, Kang YK, Blay JY, Rutkowski P, Gelderblom H, et al. Efficacy and safety of regorafenib for advanced gastrointestinal stromal tumours after failure of imatinib and sunitinib (GRID): an international, multicentre, randomised, placebo-controlled, phase 3 trial. *Lancet.* 2013;**381**(9863):295-302. doi: 10.1016/S0140-6736(12)61857-1. [PubMed: 23177515].