



A Case Report of Intracranial Complication Following Septorhinoplasty

Fares Najari,^{1*} Masoud Ghadipasha,² Ali Alimohammadi,³ Ideh Baradaran Kayal,⁴ and Khadijeh

Saravani⁵

¹MD, Forensic Specialist, Faculty Member of Shahid Beheshti University of Medical Sciences, Tehran, Iran

²MD, Forensic Medicine Specialist, Associate Professor, Member of Legal Medicine Research Center. Legal Medicine Organization, Tehran, Iran

³MD, Forensic Specialist, Faculty Member of Legal Medicine Organization, Tehran, Iran

⁴MD, Forensic Medicine Specialist, Shahid Beheshti University of Medical Sciences, Tehran, Iran

⁵MD, Forensic Medicine Assistant, Shahid Beheshti University of Medical Sciences, Tehran, Iran

*Corresponding author: Fares Najari, Department of Forensic Medicine, Shahid Beheshti University of Medical Science, Daneshjou Blvd, Erabi Ave, Velenjak, P.O.Box: 1983969411, Tehran, Iran. E-mail: fares.hospital@yahoo.com

Received 2017 March 09; Revised 2017 May 15; Accepted 2017 August 12.

Abstract

Introduction: Septorhinoplasty is one of the most common cosmetic procedures in Iran. Intracranial complications such as meningitis, cerebrospinal fluid (CSF) rhinorrhea, pneumocephalus, and damage to the skull's base are rare, but potential life-threatening complications are associated with such procedures, though very few cases of intracranial complications after septorhinoplasty have been reported.

Case Presentation: A 29-year-old woman was admitted to a limited surgery clinic in Tehran, Iran in 2015 for septorhinoplasty, and 4 days post-operation she complained of headache, drowsiness, and CSF rhinorrhea. The patient's surgical complications included a skull base fracture, pneumocephalus, and an epidural hematoma.

Conclusions: Prevention of life-threatening complications following septorhinoplasty is important. Prevention, early detection, and appropriate treatment of intracranial complications will result in fewer catastrophic outcomes. To prevent damage to the skull base and other cerebral complications, it is necessary that surgeons use a suitable technique, understand appropriate anatomical information, maintain awareness of possible anatomic variations, and practice gentle manipulation of the ethmoid roof.

Keywords: Rhinoplasty, Cerebrospinal Fluid Rhinorrhea, Pneumocephalus, Postoperative Complications

1. Introduction

Septorhinoplasty is one of the most common cosmetic procedures in Iran. It has traditionally been performed as an open procedure, working through hemi-transfixion incisions just caudal to the septum. Mucoperichondrial flaps are raised bilaterally, and the offending cartilage and bone are selectively removed (1). Common side effects of septorhinoplasty include swelling, inflammation, infection, hemorrhage, hematoma, stricture of the nasal canal, rhinitis, and damage to nasolacrimal ducts. Common associated deformities can include a saddle nose or depressed nose, damage to the nose skin, nasal tip deformity and numbness, olfactory disorders, and perforation of the nasal septum. In addition to these complications, there are rare complications that include meningitis, cerebrospinal fluid (CSF) rhinorrhea, cavernous sinus thrombosis, pneumocephalus, subarachnoid hemorrhage, sub-

dural abscess, brain abscess, damage to the cribriform plate (2, 3), ocular complications, toxic shock syndrome, post rhinoplasty nasal cysts, and telangiectasias (4).

Although rare, intracranial complications of septorhinoplasty are life threatening, and there are few case reports on fatal intracranial complications. A review of the English-language literature showed 7 case reports of CSF rhinorrhea following septoplasty and 5 case reports following rhinoplasty. Death related to nasal surgery is also rare. In India, Alexander et al. (2008) reported that a healthy 58-year-old woman who underwent nasal polypectomy, septoplasty, and intranasal endoscopic ethmoidectomy died 2 days after surgery due to the following brain injuries: subarachnoid hemorrhage, intraventricular hemorrhage, and hydrocephalus, all related to damage of the cribriform plate (5). Then in 2013, Aliasghar Peyvandi and Navid Ahmady Roozbahany from Tehran, Iran reported a case of a 17-year-old male patient who suf-

ferred a ventricular hemorrhage and hydrocephalus due to a skull base injury after septoplasty, and died 1 month later (6). Here, we describe a very rare intracranial complication after septorhinoplasty, as awareness of these rare complications can help physicians in prevention, early detection, and appropriate treatment of life-threatening complications.

2. Case Presentation

An otherwise healthy 29-year-old woman was admitted to a limited surgery clinic in Tehran, Iran to repair a nasal deformity, septal deviation to the left, and narrowing of the nasal vestibule. In October 2015, she underwent open septorhinoplasty, an osteotomy, and a dorsal graft of 2 layers of the septum under general anesthesia. She did not report any preexisting diseases, specific problems, or trauma before the operation, and her routine pre-operative tests (including CBC, PT, PTT, INR, FBS, and Urea) were normal. She was discharged from the clinic the same day in good general condition, but 4 days after surgery she presented to a private general hospital with headache, drowsiness, and CSF rhinorrhea. She did not report any trauma in her history and there was no sign of trauma upon physical examination. She experienced convulsions and loss of consciousness within the first 12 hours after admission.

The patient underwent a spiral brain CT scan without contrast that demonstrated cerebral edema, an intraparenchymal hematoma in left frontal lobe, and pneumocephalus on the surface of both frontal lobes. Moreover, there was also increased opacity and increased air fluid levels in the paranasal sinuses. Upon angiography of the carotid artery, a 2×3 mm saccular aneurysm of the left ophthalmic artery was found. The patient received medical treatment, but died 10 days after rhinoplasty.

On autopsy, no lacerations or bruises on the head or face were observed. The brain autopsy showed no bleeding under the skin of the scalp or between muscles. The brain tissue was looser and softer than normal, edematous, and congested. A brain contusion of about 4×4 cm was seen in the right temporal lobe, and about 20 cc of blood clots were observed in the right lateral ventricle (Figure 1), as well as 5 cc epidural hematomas as clots in the anterior of the right petrous bone (Figure 2). In the skull base, a circular fracture was observed at the anterior of the right petrous bone with a diameter of approximately 5 mm, and the lateral ventricles contained about 100 cc of amber-colored liquid. Other organs were normal and pulmonary embolism was not evident.

Upon histopathological inspection, liver tissue slices appeared normal, pulmonary tissue was minimally edematous, and gastric erosion was found in the stomach.

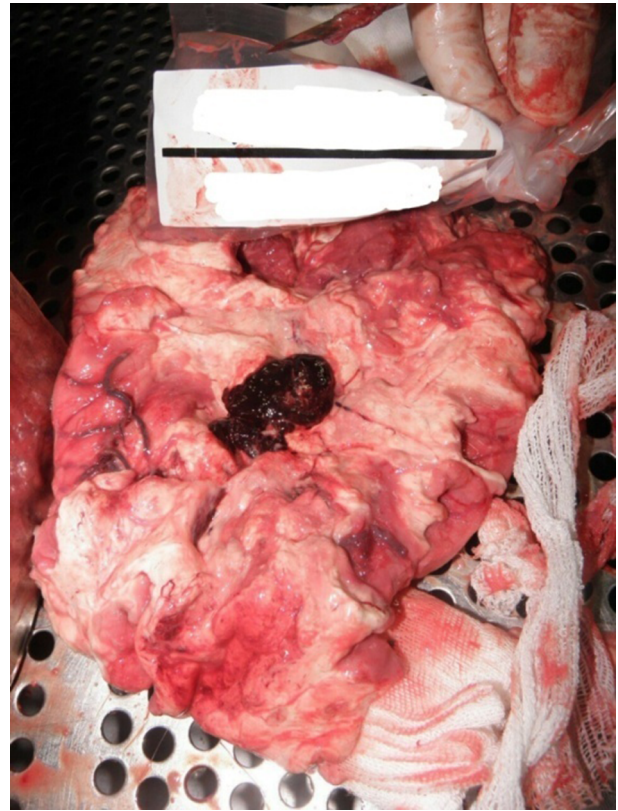


Figure 1. Blood Clots in the Ventricle

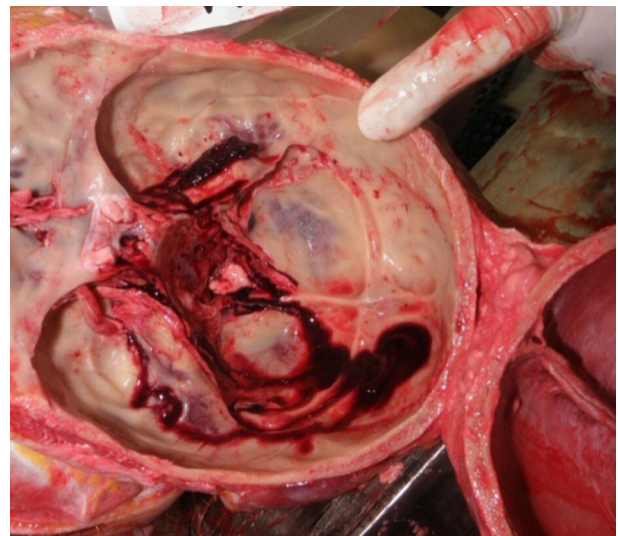


Figure 2. Epidural Hematoma in the Anterior of Right Petrous Bone

Brain tissue slices demonstrated diffuse vital hemorrhage,

neuronal necrosis was seen in a damaged area, and the margins of that area were edematous.

The relatives of the deceased patient sued the surgeon. The medical commission of medical procedures determined that the cause of death was skull base injuries received during surgery that caused intracranial hemorrhage and a pseudoaneurysm, which led to eventual rupture, bleeding, and subsequently caused the patient's death.

3. Discussion

As previously mentioned, to date few cases of CSF rhinorrhea following septorhinoplasty have been reported. In our case, the patient had CSF rhinorrhea due to a skull base fracture.

Rhinorrhea of the CSF following rhinoplasty and endoscopic sinus surgery has been reported, but is rare after septoplasty. It is caused by damage to the skull base during nasal surgery.

In 2010, Annabelle and colleagues reported a case in which the ethmoid plate was broken during septoplasty and caused CSF rhinorrhea; in fact, the silastic splint pushed against the right middle turbinate, displaced it, and created a subtle fracture in the ethmoid plate (7). In 2008, Bilgic et al. reported that a 45-year-old woman from Istanbul, Turkey underwent rhinoplasty because of septal deviation and septal perforation. CSF rhinorrhea began 2 days after the operation. A cranial CT image showed a fistula within the anterior cranial fossa. Significant headache and stiffness of the neck became evident after 6 days. The patient recovered at the 10-day mark through medical treatment. In this case, manipulation of the nasal septum resulted in trauma to the cribriform plate and resulted in rhinorrhea (8).

The onset of CSF rhinorrhea following septorhinoplasty may occur following a delay, as in a case report by Tarkan et al. in 2012 from Adana, Turkey, which described a 28-year-old female who experienced CSF rhinorrhea 3 weeks after septoplasty (9). In our case study, however, CSF rhinorrhea occurred 4 days after surgery. In 1983, Marshall and colleagues performed a study on 10 cadavers, which included both male and female cadavers aged 18 to 64 years old at the time of death. The group observed that a 3 mm osteotome could easily fracture the floor of the anterior cranial fossa. Greater force was required to allow the osteotome to enter the anterior cranial fossa. However, a much greater than usual force during a rhinoplasty surgery is required to create a fracture, because it is unlikely that the supportive bones at the root of the nose will break easily (10).

Skull base injury due to rhinoplasty occurs usually at the lateral lamella, at the junction of cribriform plate, and the ethmoid labyrinth, because these are very thin areas of the skull where the dura is stuck strongly (Figure 3). The wall of the sphenoid anterior sinus is attached to the posterior part of the perpendicular (vertical) plate of the ethmoid and vomer, which may be damaged during repair of a deviated septum (11). In the case we reported however, the fracture was observed in the anterior of the temporal petrous bone. Because this bone is circular, it is possible that surgical instruments induced this injury.

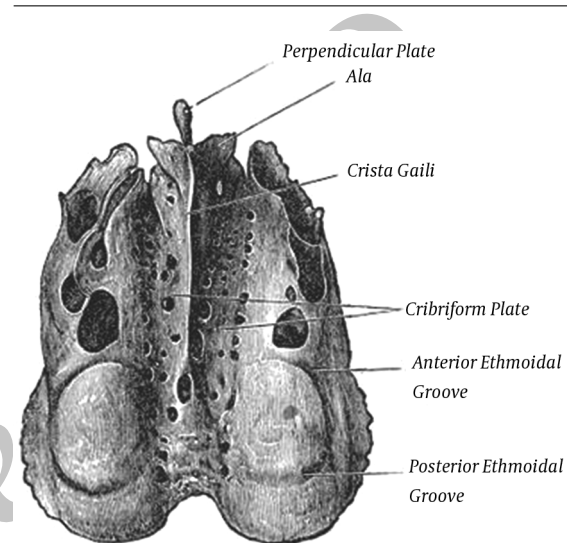


Figure 3. Upper View of Ethmoid

Onerci et al. described two cerebral complications of CSF-rhinorrhea after septoplasty from Ankara, Turkey, and concluded that rotational movements during the breaking and removal of the perpendicular (vertical) plate of the ethmoid in the posterior nasal septum may lead to damage of the cribriform plate. Manipulation of nasal cartilage during septoplasty and the subsequent splint placement may lead to damage at the junction of the upper turbinate and the cribriform plate. During the lifting of the mucoperichondrium septal flap, over-raising the elevator forceps may perforate the cribriform plate (2).

Pneumocephalus was also observed in our case study. Within our group, Chiari discovered an air bubble inside the brain at the time of autopsy and Wolf determined that it was a pneumocephalus. In the case presented by Al Arfaj in 2014, a 28-year-old woman presented with headache to the emergency department 4 days after septorhinoplasty, with pneumocephalus observed upon CT scan in the frontal lobe (12), as observed in our case. Guvenc et al. in Turkey presented a case of tension pneumocephalus with-

out CSF leak 1 month after septoplasty (13).

It is very important to prevent life-threatening cerebral complications in septorhinoplasty. To avoid damage to the skull base and other cerebral complications, it is necessary that surgeons use a suitable technique, understand appropriate anatomical information, maintain awareness of possible anatomic variations, and practice gentle manipulation of the ethmoid roof.

3.1. Limitation of Our Study

We did not have any graphy or brain CT results of the patient prior to surgery as this was not available in her medical records.

Acknowledgments

We would like to express our special thanks to the forensic center of Tehran, Iran.

Footnotes

Authors' Contribution: All authors qualified the four criteria for authorship contribution based on the recommendations of the international committee of medical journal editors.

Conflict of Interests: The authors declared no potential conflict of interest with respect to the authorship and/or publication of this article.

References

1. Ketcham AS, Han JK. Complications and management of septoplasty. *Otolaryngol Clin North Am.* 2010;**43**(4):897-904. doi: [10.1016/j.otc.2010.04.013](https://doi.org/10.1016/j.otc.2010.04.013). [PubMed: [20599092](https://pubmed.ncbi.nlm.nih.gov/20599092/)].
2. Onerci TM, Ayhan K, Ogretmenoglu O. Two consecutive cases of cerebrospinal fluid rhinorrhea after septoplasty operation. *Am J Otolaryngol.* 2004;**25**(5):354-6. [PubMed: [15334401](https://pubmed.ncbi.nlm.nih.gov/15334401/)].
3. Hafezi F, Kouchakzadeh K, Naghibzadeh B. History and status of nose surgery. *Iran J Surg.* 2009;**17**(2):88-94.
4. Cochran CS, Landecker A. Prevention and management of rhinoplasty complications. *Plast Reconstr Surg.* 2008;**122**(2):60e-7e. doi: [10.1097/PRS.0b013e31817d53de](https://doi.org/10.1097/PRS.0b013e31817d53de). [PubMed: [18626319](https://pubmed.ncbi.nlm.nih.gov/18626319/)].
5. Tawadros AM, Prahlow JA. Death related to nasal surgery: case report with review of therapy-related deaths. *Am J Forensic Med Pathol.* 2008;**29**(3):260-4. doi: [10.1097/PAF.0b013e3181832432](https://doi.org/10.1097/PAF.0b013e3181832432). [PubMed: [18725785](https://pubmed.ncbi.nlm.nih.gov/18725785/)].
6. Peyvandi A, Roozbahany NA. Skull base injury leading to death after conventional septoplasty. *Am J Forensic Med Pathol.* 2013;**34**(1):5-6. doi: [10.1097/PAF.0b013e3182518e31](https://doi.org/10.1097/PAF.0b013e3182518e31). [PubMed: [23361069](https://pubmed.ncbi.nlm.nih.gov/23361069/)].
7. Leong AC, Patel T, Rehman F, Oyarzabal M, Gluckman P. Cerebrospinal fluid rhinorrhea complicating septoplasty: a novel mechanism of injury. *Ear Nose Throat J.* 2010;**89**(1):27-9. [PubMed: [20155696](https://pubmed.ncbi.nlm.nih.gov/20155696/)].
8. Bilgic MI, Karaca M, Karanfil H, Akoz T. A rare but disturbing complication of rhinoplasty: rhinorrhea. *J Craniofac Surg.* 2008;**19**(5):1433. doi: [10.1097/SCS.0b013e3181869ddc](https://doi.org/10.1097/SCS.0b013e3181869ddc). [PubMed: [18812882](https://pubmed.ncbi.nlm.nih.gov/18812882/)].
9. Tarkan O, Soylu L, Aydogan B, Ozdemir S, Surmelioglu O. Delayed cerebrospinal fluid leakage: an unusual septoplasty complication. *J Oral Maxillofac Surg.* 2012;**70**(4):e298-300. doi: [10.1016/j.joms.2011.12.026](https://doi.org/10.1016/j.joms.2011.12.026). [PubMed: [22449435](https://pubmed.ncbi.nlm.nih.gov/22449435/)].
10. Marshall DR, Slattery PG. Intracranial complications of rhinoplasty. *Br J Plast Surg.* 1983;**36**(3):342-4. [PubMed: [6860864](https://pubmed.ncbi.nlm.nih.gov/6860864/)].
11. Gulsen S, Yilmaz C, Aydin E, Kocbiyik A, Altinors N. Meningoencephalocele formation after nasal septoplasty and management of this complication. *Turk Neurosurg.* 2008;**18**(3):281-5. [PubMed: [18814119](https://pubmed.ncbi.nlm.nih.gov/18814119/)].
12. Al Arfaj A. A rare complication of septorhinoplasty. *Plast Reconstr Surg Glob Open.* 2014;**2**(12):e273. doi: [10.1097/GOX.0000000000000224](https://doi.org/10.1097/GOX.0000000000000224). [PubMed: [25587507](https://pubmed.ncbi.nlm.nih.gov/25587507/)].
13. Guvenc G, Eren E, Arslanoglu S, Yuceer N. A rare complication of septoplasty: tension pneumocephalus without rhinorrhea. *J Craniofac Surg.* 2014;**25**(4):e360-1. doi: [10.1097/SCS.0000000000000804](https://doi.org/10.1097/SCS.0000000000000804). [PubMed: [25006947](https://pubmed.ncbi.nlm.nih.gov/25006947/)].