



Determination of the Optimal Angle for Needle Insertion During Caudal Epidural Steroid Injection in Adults Using Ultrasound Imaging

Erhan Gökçek^{1,*} and Ayhan Kaydu¹

¹Department of Anesthesiology and Reanimation, Diyarbakır Selahaddin Eyyübi State Hospital, Diyarbakır, Turkey

*Corresponding author: Department of Anesthesiology and Reanimation, Diyarbakır Selahaddin Eyyübi State Hospital, Diyarbakır, Turkey. Tel: +90-4122285430, Email: gokcekerhan_44@hotmail.com

Received 2017 December 12; Revised 2017 December 27; Accepted 2018 January 23.

Abstract

Background: Lumbar back pain is a common disease, which reduces life quality. Caudal epidural steroid injection (CESI) is frequently preferred to relieve lumbar back pain. However, various major complications can be observed due to CESI. A new technique of needle angle should be improved to prevent complications such as intraosseous, intrathecal or intravascular injection during CESI.

Objectives: Caudal epidural steroid injection is one of the methods frequently used to treat chronic lumbar back pain. The current study aimed at examining the anatomy of the sacral hiatus and determining the optimal angle of the needle for CESI.

Methods: The current clinical trial was performed in Diyarbakır Selahaddin Eyyübi State Hospital from January to June in 2017. The study included 150 adult patients (first group = 92 males (%61.3), second group = 58 females (%38.7) aged 18 - 78 years applied to the Algology Polyclinic with ASA-PS classes I and II (the American Society of Anesthesiologists (ASA) physical status classification system). Measurements were taken during the CESI applied under ultrasonography (USG) guidance of the intercornual distance, the sacral space, and the optimal needle entry angle.

Results: The intercornual distance was significantly higher in group one (mean \pm standard deviation (SD): 16.6 \pm 2.04) than group two (mean \pm SD: 15.8 \pm 2.51) ($P < 0.049$). No difference was observed between group one (mean \pm SD: 4.49 \pm 0.75) and group two (mean \pm SD: 4.45 \pm 0.88) with respect to sacral space ($P > 0.79$). The most appropriate entry angle for the needle in the application of CESI was mean 71.04° in the whole patient group, as 71.9° in group one and 69.7° in group two. There was no significant difference between the genders in terms of the mean optimal angle ($P > 0.091$). Also, no significant difference was observed among the patients in terms of the demographic data ($P > 0.05$).

Conclusions: The results of the current study revealed that the optimal needle angle for CESI applied under USG guidance was 71.04°, different from traditional method and the injection procedure could be safely made directly to the epidural space without changing the angle after entry of the needle to the epidural space.

Keywords: Back Pain, Caudal Epidural, Injection, Lumbar Back Pain, Optimal Angle

1. Background

The caudal epidural block is a widely used method for postoperative analgesia in children and to treat chronic lumbar back pain (1, 2). Epidural steroid injections are applied for chronic lumbar back pain since the 1950s (3). Caudal epidural steroid injection (CESI) was first applied in a blind manner from the intercornual mid-distance by bilateral cornual palpation. Despite a success rate of 96% in children with the blind technique (4, 5), the success rate in adults is approximately 70% (6, 7). The difference in adult patients is due to anatomic differences in the sacrum.

For a successful caudal epidural injection, accurate placement of the needle in the caudal space is necessary.

Several anatomic studies are conducted regarding the caudal canal, but most of them are based on cadaver studies (8, 9). It is vital to precisely establish the location of the sacral hiatus, which is an important anatomic structure for caudal epidural injection since the sacral hiatus's apex indicates the sacral canal. Therefore, anatomic variations in the sacral hiatus affect the success of caudal injections. Although fluoroscopy is the gold standard for confirmation of the needle placement during the CESI procedure, ultrasonography (USG) is an effective tool in caudal injections due to ease of use, the provision of images in real time, and no exposure to radiation (10).

The current study mainly aimed at calculating the optimal angle for needle application aided by USG to reduce

the risk of intraosseous, intrathecal, or intravascular injection during CESI procedure in adults (11, 12). The study also aimed at measuring the sacral anatomic structures (13, 14).

2. Objectives

The current study aimed at calculating the optimal needle entry angle during CESI applied to patients with lumbar back pain and gaining more knowledge about sacral hiatus distance.

3. Methods

3.1. Study Design

The current clinical trial was conducted at Diyarbakır Selahaddin Eyyübi State Hospital, Diyarbakır, Turkey, from January to June in 2017. The written consent was obtained from each participant.

3.2. Sample Size

Power analysis was practiced to calculate the required sample size to reach 80% statistical power with a confidence interval (CI) of 95% and 5% level of significance before the study. It was evaluated that 100 patients were enough to reach the goal. It was decided to recruit at least 150 patients (20% higher than the initial sample size) in the current study due to possible exclusions and dropouts.

3.3. Sample Collection and Participants

The inclusion criteria were patients examined by Selahaddin Eyyübi State Hospital Neurosurgery Polyclinic and diagnosed with lumbar disc hernia (L4 - 5, L5 - S1) by evaluation of lumbar magnetic resonance image (MRI) and response to cure with ASA-PS classes I and II (the American Society of Anesthesiologists physical status classification system).

Approximately 150 out of 200 patients (1st group = 92 males, 2nd group = 58 females), referred to the polyclinic with the complaints of back and leg pain, with no need for an emergency operation, and underwent CESI under USG guidance were included in the study with their consent.

The exclusion criteria were surgical indications of lumbar disc hernia, lumbar extrusion on MRI, the appearance of a sequestered disc, allergy to local anesthetic or steroids, infection in the needle site, coagulopathy, or pregnancy. The patients were examined in the polyclinic, and their age, gender, height, and weight were recorded (Figure 1).

One hundred fifty patients referred for the caudal epidural steroid injection. They were classified into two groups; ASA class I or II, and were enrolled using the consecutive sampling method. The patients were in the age

range of 18 - 78 yearsold. The exclusion criteria were patients with ASA-PS class III or higher, cardiovascular diseases, pulmonary diseases, renal, hepatic and, endocrine dysfunctions, hypertension, psychiatric diseases, epilepsy, hypersensitivity to lidocaine, using opioid or non-opioid analgesics prior to the operation, and a history of laparotomy more than once. The purpose of the ASA-PS grading system is to determine the intensity of the patient's "sickness" or "physical state" before caudal epidural steroid injection. A summary of this classification is given below and also further details can be obtained from websites of the American Society of Anesthesiologists:

3.4. ASA-PS

3.4.1. ASA-PS Class I: Healthy Patient

A healthy person who does not have a disease or a systemic problem other than a surgical pathology that does not cause a systemic disorder.

3.4.2. ASA-PS Class II: Patients with Mild Systemic Disease

A person with a mild systemic disorder that requires surgical intervention or another disease (mild anemia, chronic bronchitis, hypertension, emphysema, obesity, diabetes, and so on).

3.4.3. ASA-PS Class III: Patients with Severe Systemic Disease

A person with an illness that limits his activity, but does not make him weak (such as hypovolemia, latent heart failure, past myocardial infarction, advanced diabetes, and limited pulmonary function).

3.4.4. ASA-PS Class IV

A person with an illness that causes a complete loss of strength and creates a serious threat to life (shock, decompensated heart or respiratory system, kidney, liver failure, and so on).

3.4.5. ASA-PS Class V

The patient who was about to die and had an operation with the hope of surviving and the patient who was not expected to live longer than 24 hours whether he had surgery or not.

3.4.6. ASA-PS Class VI

This group was added to the other five groups later. This group contains patients with brain death and suitable for transplantation.

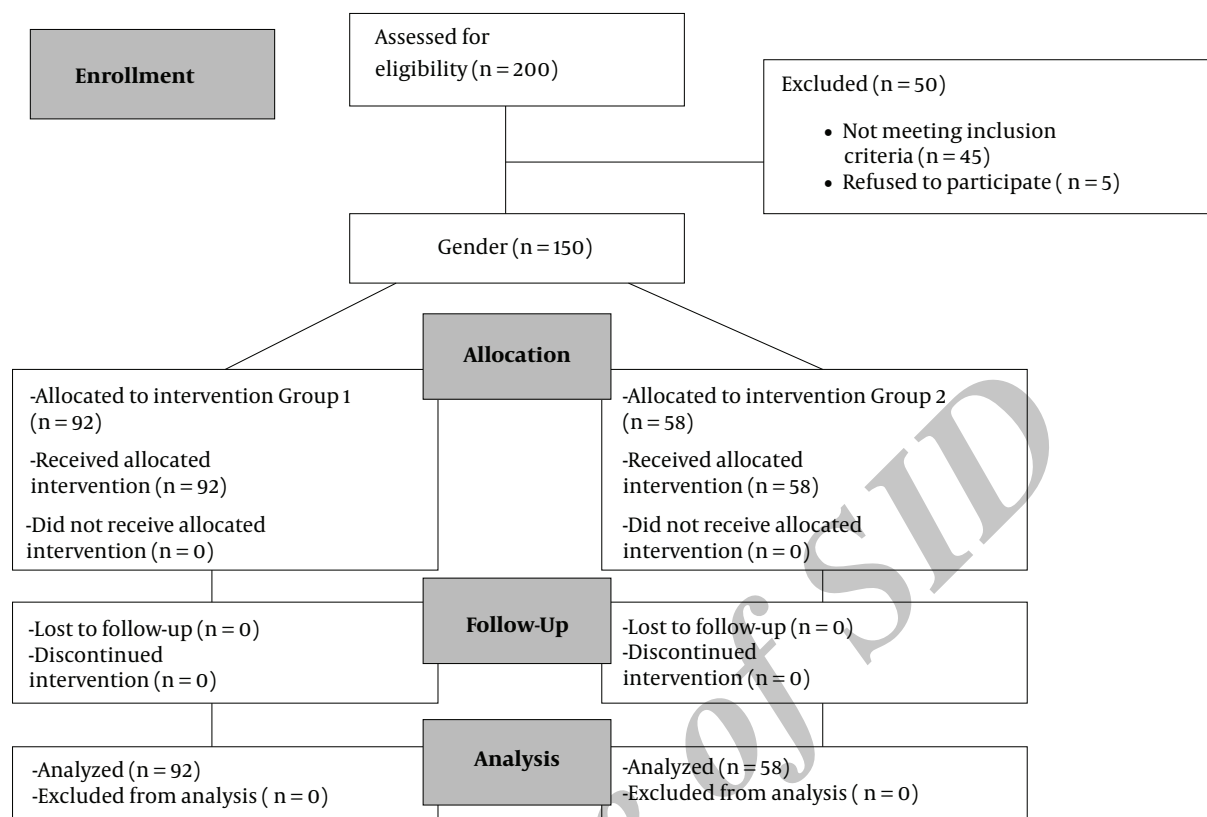


Figure 1. Consort Diagram (1st group = male; 2nd group = female, USG-guided caudal epidural steroid injection).

3.5. Interventions and Measurements

Patients were taken to the application room for the caudal epidural injection. A 20-gauge vascular route was opened and 0.9% NaCl solution (100 mL/hour) was attached. Monetarization was applied to arterial blood pressure, pulse, peripheral oxygen saturation (SPO₂), and electrocardiogram (ECG). The patient was positioned prone with a pillow below the abdomen. The entry area was cleaned with the povidone-iodine antiseptic solution and sterile drape. The sacral hiatus was identified and local anesthetic containing lidocaine was applied with a 2 mL syringe and a 27-gauge, 1.5 inches (Germany) dental-tipped needle. The US probe was sterile covered.

Under USG guidance (Sonosite® M-Turbo Bothell WA, USA) (HFL38X/13-6 MHz Transducer, Bothell WA, USA) to first obtain a transverse image of the sacral hiatus, the transducer was placed over the sacral cornua. On the transverse image, the distance between the two cornuas (intercornual distance) and the depth of the caudal space in the sacral cleft (caudal canal depth) were measured first (Figure 2). The transducer was then turned 90° and placed between the two cornuas to obtain an image of the length of

the caudal canal. The optimal angle was measured on this image (Figure 3). By entering the needle to the midpoint of the sacral canal, the optimal angle was identified as the angle after passing the sacrococcygeal ligament (Figure 4). To calculate the most suitable angle, a virtual line was drawn parallel to the sacral floor on the longitudinal image and the optimal angle defined as the point at which the entry point of the needle from the skin crossed this virtual line.

In all patients, a 50 mm 20-gauge Epican® Paed (Braun, Melsungen, Germany) caudal block needle was used (Figure 5). When it was felt that the needle tip passed the epidural space by passing through the soft tissue, contact was made with the bone and then by drawing the needle back by a small amount, distribution of the drug within the caudal canal and correct placement was checked with the aid of USG and the optimal angle was measured. Anatomical structures were measured on the sonogram with the digital calipers of the USG machine after the caudal epidural steroid injection. A solution of 0.2 mg/kg with 2.5% bupivacaine and 6 mg betamethasone prepared for patients (Celestone Chrono-dose®, Schering AG, Berlin, Germany) diluted with 0.9% NaCl was administered slowly into the

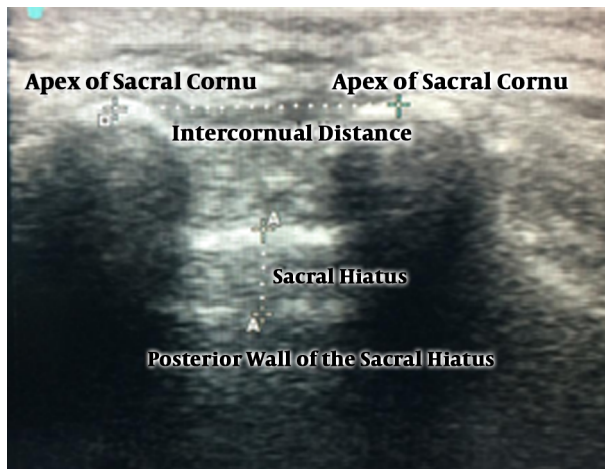

Figure 2. Ultrasound image of the sacral hiatus. The intercornual distance between bilateral cornua was measured between the apexes of both cornua on a transverse image.

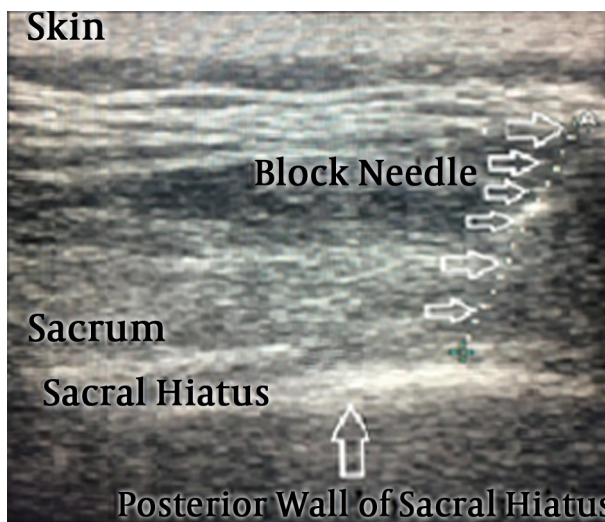


Figure 3. The optimal angle for needle insertion was measured between the line parallel to the posterior wall of the sacral hiatus and the skin surface.

epidural space of all patients (15). Following the procedure, the patients were admitted to the postoperative recovery room and monitored closely for hemodynamics for half an hour. The Bromage scale was applied every 15 minutes to the patients. When hemodynamics were stable, and the Bromage scale was nil, the patients were transferred to the ward. After monitoring for 24 hours in the ward, the patients were discharged with a prescription. Then, the patients were telephoned and questioned at home about any complications.

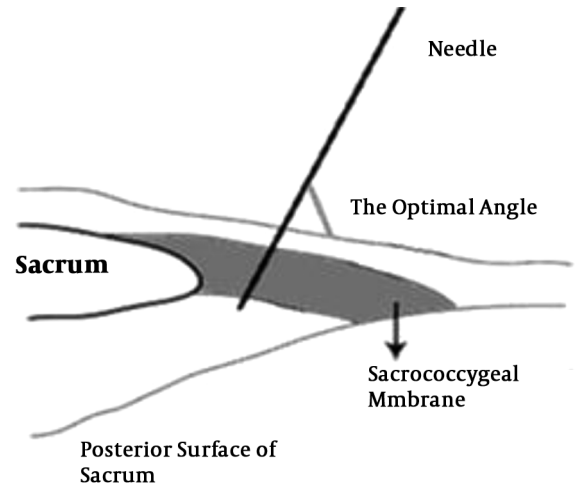


Figure 4. Schematic drawing showing how the optimum angle is predicted.

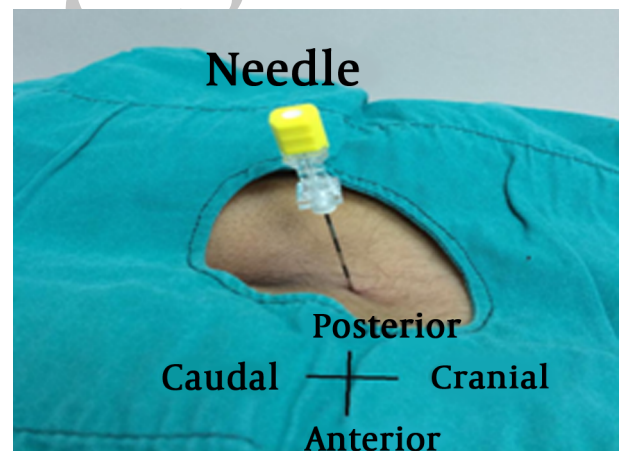


Figure 5. A 20-gauge 50-mm caudal block needle

3.6. Statistical Analysis

The data were analyzed SPSS Statistical Software for Windows, version 16 (SPSS Inc., Chicago, ILL., USA). Results for continuous variables are expressed as the mean \pm standard deviation (SD). Categorical variables are shown as a frequency (percent). For statistical analysis, parametric (independent and paired-samples t-tests, univariate generalized linear model [GLM] [$\alpha = 0.05$]) analyses were used to compare response variables with two groups. Also, Chi-square and the Fisher exact tests were used to compare proportions between the two groups. The data were evaluated at a 95% CI. A value of $P < 0.05$ was considered as the level of significance.

3.7. Ethical Consideration, Consent, and Permissions

The current study was a single-center clinical trial, approved by the Ethics Committee of Diyarbakır Training and Research Hospital, Turkey (no. 2017/56, 09 June 2017) and conducted according to the Declaration of Helsinki. The written informed consent was obtained from all patients or surrogates before participation.

4. Results

The study included a total of 150 adult patients with back and leg pain. These comprised 92 males (61.3%) and 58 females (38.7%) with a mean age of 40.27 ± 12.7 years for the 1st and 44.65 ± 14.6 years for the 2nd groups. The difference between the groups in terms of mean age was statistically insignificant ($P = 0.06$). The average body mass index (BMI) was $26.69 \pm 13.48 \text{ kg/m}^2$ in the 1st and $27.63 \pm 15.38 \text{ kg/m}^2$ in the 2nd groups ($P = 0.61$). Demographic information of the patients in both groups are shown in [Table 1](#).

In all patients, the measurements were made on both the transverse and longitudinal images of the sacral hiatus. The hyperechoic movement of the caudal needle advancing into the sacral epidural space represented real time with the longitudinal image under USG. In all patients, when the sacrococcygeal ligament was passed, a 'give' or 'pop' was identified.

Single entry was sufficient for the placement of the caudal needle in the epidural space under USG guidance and took less than three minutes.

The intercornual distance in the 1st group ($16.6 \pm 2.04 \text{ mm}$) was significantly greater than that of the 2nd group ($15.8 \pm 2.51 \text{ mm}$) ($P = 0.049$). No difference was observed between the two groups in terms of the sacral gap ($P = 0.79$). The sacral canal diameter was measured as $< 2 \text{ mm}$ in only one patient. The caudal epidural steroid injection was not successful in five patients due to a closed sacrum hiatus ([Table 2](#)).

No statistically significant difference was observed between the groups regarding the mean optimal angle for needle placement. The most suitable angle for needle placement was $71.9^\circ \pm 6.43^\circ$ in the 1st and $69.7^\circ \pm 6.8^\circ$ in the 2nd groups, and therefore, the most suitable angle for the whole patient group was $71.04^\circ \pm 6.65^\circ$ ([Table 2](#)).

No major complications were observed in any of the patients, and minor complications such as headache, nausea, and vomiting were observed in five patients ([Table 1](#)).

5. Discussion

In the current study, it was observed that the CESI procedure applied under USG guidance was an easier tech-

nique, and minimized the complications of intraosseous, intravascular, or intrathecal injection that can occur. The results showed that with a caudal block needle entry angle of 71.04° under Doppler USG guidance, the medication could be delivered directly to the caudal epidural space as the needle passed the sacrococcygeal ligament without changing the angle after entry to the caudal epidural space.

Although epidural injection procedures can be applied by caudal, interlaminar, and transforaminal routes, the injection applied via the caudal epidural route provided an increasingly preferred option, which is relatively safer with a low risk of dural puncture. In the evaluation of correct placement of the caudal needle, although fluoroscopy is the gold standard, due to the exposure to radiation, the difficulty of use, and limited availability, USG was preferred in the current study. Together with fluoroscopic confirmation, USG is currently observed as a 100% effective tool to identify the sacral hiatus location and shows the correct placement of the needle in the caudal epidural space ([15-17](#)).

In several studies, after the needle reached the sacral floor by passing through the sacrococcygeal ligament at $50^\circ - 68^\circ$ angle, the needle was brought to a horizontal angle of $15^\circ - 35^\circ$, and advanced parallel to the floor of the sacral space to inject the drug. The majority of those studies were conducted on cadavers or pediatric patients ([9, 10, 12, 18](#)). In a study on 49 adult patients with low back pain, Doo et al. ([19](#)), applied the needle at $45^\circ - 60^\circ$ angle to the skin and after passing through the sacrococcygeal ligament, the needle was brought to a horizontal angle of $15^\circ - 30^\circ$ and the injection was made. It was found that the risk of intravascular injection was eliminated by advancing the needle in the sacral canal. Park et al. ([10](#)), found the mean optimal angle of 21° (range, $10^\circ - 38^\circ$) for needle placement in 130 children aged 2 - 184 months. In a cadaver study by Aggarwal et al. ([8](#)), the mean optimal angle for needle entry was 24.3° (range, $12^\circ - 32^\circ$).

When the results of the current study were compared with those of previous studies, the difference was that the patients were adult. It was observed that with an entry angle of 71.04° , after passing the sacrococcygeal ligament, under USG guidance, the drug was distributed in the epidural space without changing the needle entry angle.

Senoglu et al. ([13](#)), found that during the caudal epidural block, after passing through the sacrococcygeal ligament, it was only necessary to advance the needle a few millimeters. According to the current study, as changing the needle entry angle and advancement can lead to various complications (intravascular, intrathecal, and intraosseous), the method used in the current study can be considered safer and more applicable.

Table 1. Distribution of the General Characteristics of Patients in the Study Groups^a

Variable	1st Group, N = 92	2nd Group, N = 58	P Value ^b
Age, y	40.27 ± 12.7	44.65 ± 14.6	0.06
BMI, kg/m ²	26.69 ± 13.48	27.63 ± 15.38	0.61
ASA-PS class			0.14
I	30 (30.6)	38 (65.5)	
II	62 (69.4)	20 (34.5)	
Time to block, min	2.4 ± 0.46	2.5 ± 0.50	0.72
Target level			0.18
L4 - L5	37 (40.2)	30 (51.7)	
L5 - S1	55 (59.8)	28 (48.3)	
Complication	3 (1.58)	2 (3.44)	0.66

Abbreviations: ASA-PS, American Society of Anesthesiologist physical status; SD, standard deviation.

^a Values are expressed as Mean ± SD or No. (%).

^b Independent-samples *t*-test.

Table 2. Ultrasound Measurements Between Male and Female Patients^a

Parameter	Total	1st Group, N = 92	2nd Group, N = 58	P Value ^b
Intercornual distance, mm	16.3 ± 2.27	16.6 ± 2.04	15.8 ± 2.51	0.049
Diameter of sacral canal, mm	4.47 ± 0.80	4.49 ± 0.75	4.45 ± 0.88	0.79
Successful blockade	1.04 ± 0.20	1.02 ± 0.16	1.06 ± 0.24	0.37
Optimal angle for needle Insertion °	71.04 ± 6.65	71.9 ± 6.43	69.7 ± 6.8	0.091

^a Values are expressed as Mean ± SD.

^b Independent-samples *t*-test.

Doo et al. (19), divided 49 adult patients into two groups. In group 1 the traditional method was applied with 2 cm advancement to the sacral canal, and in group 2, the drug was administered immediately after passing through the sacrococcygeal ligament. When the success rates were compared, success was achieved in 68% of subjects in group 1 and 95.8% of subjects in group 2. Intravascular injection was observed in 24% of subjects in group 1 and in none of the subjects in group 2. No intrathecal injection was observed in either group, and it was concluded that the new technique had a higher success rate than the traditional method. The current study obtained similar results.

Maniquis Smigel et al. (20), applied the caudal epidural injection procedure with a vertical angle under fluoroscopy guidance and positive epidurogram with 90% success and 0% intravascular injection were reported. In the current study, no major complications were observed, Doppler USG imaging was used with a vertical angle, and since the angle applied in the current study was less traumatic in respect to the risk of intraosseous injection, it can be considered safer.

Conn et al. (2), found that the intercornual distance

was 16.4 mm and the sacral canal diameter was 6.1 mm. Senoglu et al. (13), reported that the intercornual distance was 17.47 mm (range, 7 - 28 mm) and the sacral hiatus was 4.46 mm (range, 1 - 7 mm). In a pediatric study by Park et al. (10), the intercornual distance was measured as 17 mm (range, 9.6 - 24 mm), the sacral hiatus depth as 3.5 mm (range, 1 - 8 mm), the distance of the posterior sacral bone from the skin as 21 mm (range, 10 - 39 mm), and the success rate was 92.3% with no complications. The current study had similar results; the intercornual distance measured 16.3 ± 2.27 mm and the sacral gap was 4.47 ± 0.80 mm.

In two previous studies, the intercornual distance value was lower than that of the current study. One of them was a study by Sekiguchi et al. (9), in which intercornual distance was reported 10.2 mm (range, 2.2 - 18.4 mm) and the sacral hiatus, 6.0 mm (range 1.9 - 11.4 mm). In the second one, Aggarwal et al. (14), reported that the intercornual distance was 7.9 mm. The reason for the higher values of the intercornual distance in the current study can be due to ethnic differences.

However, the CESI procedure is accepted to be safe, but the rate of major complications is high (21, 22). A signifi-

cant complication during a traditional CESI procedure is the accidental intravascular injection. In several previous studies, the frequency of intravascular injection was reported 11% - 42% (23, 24). The dural sac generally terminates at S2, but in a study on 49 adult Indian cadavers, the risk of accidental dural puncture was approximately 8%, and the dural sacs in these cases were reported to terminate at S3 (8). In the current study, no major complications were observed, and minor complications of headache, nausea, and vomiting were observed in five patients.

5.1. Limitations

The weak points of the current study were that it was conducted only on adults and not repeated for pediatric patients, and the USG imaging was not supported with fluoroscopy.

5.2. Strengths

The strong point of the study was the presentation of an easily applicable and complication-free method with a new angle technique, which was not previously attempted. Secondly, as this new technique did not require fluoroscopy, there was no exposure to radiation.

5.3. Conclusions

Even if fluoroscopy continues to be the gold standard for CESI, it is not always available, and exposure to the radiation is a source of concern. At occasions, where fluoroscopy is not available, ultrasonography is commonly used, and it significantly increases the success rate of caudal epidural injection compared with traditional blind technique. With this new needle angle technique under USG guidance, it can be considered that there are fewer intraosseous, intravascular, and intrathecal complications. Furthermore, this new needle angle application can be easily learned and may be more comfortable for the patient. It is assumed that similar studies should be conducted with a wider patient series.

Footnotes

Authors' Contribution: Erhan Gokcek and Ayhan Kaydu conceived and designed the experiments. Erhan Gokcek and Ayhan Kaydu performed the experiments. Erhan Gokcek and Ayhan Kaydu analyzed the data. Erhan Gokcek a contributed reagents/materials/analysis tools. Erhan Gokcek and Ayhan Kaydu wrote the paper. All authors read and approved the final version of the paper. wrote the paper.

Funding/Support: The study was funded by departmental resources.

References

1. Praveen P, Remadevi R, Pratheeba N. Caudal epidural analgesia in pediatric patients: comparison of 0.25% levobupivacaine and 0.25% ropivacaine in terms of motor blockade and postoperative analgesia. *Anesth Essays Res.* 2017;**11**(1):223-7. doi: [10.4103/0259-1162.200231](https://doi.org/10.4103/0259-1162.200231). [PubMed: [28298789](https://pubmed.ncbi.nlm.nih.gov/28298789/)]. [PubMed Central: [PMC5341641](https://pubmed.ncbi.nlm.nih.gov/PMC5341641/)].
2. Conn A, Buenaventura RM, Datta S, Abdi S, Diwan S. Systematic review of caudal epidural injections in the management of chronic low back pain. *Pain Physician.* 2009;**12**(1):109-35. [PubMed: [19165299](https://pubmed.ncbi.nlm.nih.gov/19165299/)].
3. Manchikanti L, Cash KA, Pampati V, McManus CD, Damron KS. Evaluation of fluoroscopically guided caudal epidural injections. *Pain Physician.* 2004;**7**(1):81-92. [PubMed: [16868617](https://pubmed.ncbi.nlm.nih.gov/16868617/)].
4. Dalens B, Hasnaoui A. Caudal anesthesia in pediatric surgery: Success rate and adverse effects in 750 consecutive patients. *Anesth Analg.* 1989;**68**(2):83-9. [PubMed: [2913854](https://pubmed.ncbi.nlm.nih.gov/2913854/)].
5. Orme RM, Berg SJ. The 'swoosh' test an evaluation of a modified 'whoosh' test in children. *Br J Anaesth.* 2003;**90**(1):62-5. [PubMed: [12488381](https://pubmed.ncbi.nlm.nih.gov/12488381/)].
6. Renfrew DL, Moore TE, Kathol MH, el-Khoury GY, Lemke JH, Walker CW. Correct placement of epidural steroid injections: fluoroscopic guidance and contrast administration. *AJNR Am J Neuroradiol.* 1991;**12**(5):1003-7. [PubMed: [1719788](https://pubmed.ncbi.nlm.nih.gov/1719788/)].
7. Barham G, Hilton A. Caudal epidurals: the accuracy of blind needle placement and the value of a confirmatory epidurogram. *Eur Spine J.* 2010;**19**(9):1479-83. doi: [10.1007/s00586-010-1469-8](https://doi.org/10.1007/s00586-010-1469-8). [PubMed: [20512512](https://pubmed.ncbi.nlm.nih.gov/20512512/)]. [PubMed Central: [PMC2989280](https://pubmed.ncbi.nlm.nih.gov/PMC2989280/)].
8. Aggarwal A, Kaur H, Batra YK, Aggarwal AK, Rajeev S, Sahni D. Anatomic consideration of caudal epidural space: A cadaver study. *Clin Anat.* 2009;**22**(6):730-7. doi: [10.1002/ca.20832](https://doi.org/10.1002/ca.20832). [PubMed: [19637298](https://pubmed.ncbi.nlm.nih.gov/19637298/)].
9. Sekiguchi M, Yabuki S, Satoh K, Kikuchi S. An anatomic study of the sacral hiatus: A basis for successful caudal epidural block. *Clin J Pain.* 2004;**20**(1):51-4. [PubMed: [14668657](https://pubmed.ncbi.nlm.nih.gov/14668657/)].
10. Park JH, Koo BN, Kim JY, Cho JE, Kim WO, Kil HK. Determination of the optimal angle for needle insertion during caudal block in children using ultrasound imaging. *Anaesthesia.* 2006;**61**(10):946-9. doi: [10.1111/j.1365-2044.2006.04795.x](https://doi.org/10.1111/j.1365-2044.2006.04795.x). [PubMed: [16978308](https://pubmed.ncbi.nlm.nih.gov/16978308/)].
11. Botwin KP, Gruber RD, Bouchlas CG, Torres-Ramos FM, Hanna A, Rittenberg J, et al. Complications of fluoroscopically guided caudal epidural injections. *Am J Phys Med Rehabil.* 2001;**80**(6):416-24. [PubMed: [11399002](https://pubmed.ncbi.nlm.nih.gov/11399002/)].
12. Yue WM, Tan SB. Distant skip level discitis and vertebral osteomyelitis after caudal epidural injection: A case report of a rare complication of epidural injections. *Spine (Phila Pa 1976).* 2003;**28**(11):E209-11. doi: [10.1097/01.BRS.0000067280.29261.57](https://doi.org/10.1097/01.BRS.0000067280.29261.57). [PubMed: [12782996](https://pubmed.ncbi.nlm.nih.gov/12782996/)].
13. Senoglu N, Senoglu M, Oksuz H, Gumusalan Y, Yuksel KZ, Zencirci B, et al. Landmarks of the sacral hiatus for caudal epidural block: an anatomical study. *Br J Anaesth.* 2005;**95**(5):692-5. doi: [10.1093/bja/aei236](https://doi.org/10.1093/bja/aei236). [PubMed: [16155035](https://pubmed.ncbi.nlm.nih.gov/16155035/)].
14. Aggarwal A, Aggarwal A, Sahni D, Harjeet. Morphometry of sacral hiatus and its clinical relevance in caudal epidural block. *Surg Radiol Anat.* 2009;**31**(10):793-800. doi: [10.1007/s00276-009-0529-4](https://doi.org/10.1007/s00276-009-0529-4). [PubMed: [19578805](https://pubmed.ncbi.nlm.nih.gov/19578805/)].
15. Janjua S, Ali S, Afridi JA, Iqbal A, Iqbal A, Ghaffar A, et al. Effects of caudal epidural steroid injection for low back pain and sciatica. *Pak Armed Forces Med J.* 2017;**67**(Suppl-1).
16. Bansal V, Siddhartha PV, Rao H, Ray B. Is caudal epidural steroid injection effective in chronic low back pain due to multiple lumbar disc prolapse? A prospective study. *Orthop J Mp Chapter.* 2017;**23**(1).
17. Chen CP, Tang SF, Hsu TC, Tsai WC, Liu HP, Chen MJ, et al. Ultrasound guidance in caudal epidural needle placement. *Anesthesiology.* 2004;**101**(1):181-4. [PubMed: [15220789](https://pubmed.ncbi.nlm.nih.gov/15220789/)].

18. Raghunathan K, Schwartz D, Connelly NR. Determining the accuracy of caudal needle placement in children: A comparison of the swoosh test and ultrasonography. *Paediatr Anaesth*. 2008;**18**(7):606-12. doi: [10.1111/j.1460-9592.2008.02529.x](https://doi.org/10.1111/j.1460-9592.2008.02529.x). [PubMed: [18616491](https://pubmed.ncbi.nlm.nih.gov/18616491/)].
19. Doo AR, Kim JW, Lee JH, Han YJ, Son JS. A comparison of two techniques for ultrasound-guided caudal injection: The influence of the depth of the inserted needle on caudal block. *Korean J Pain*. 2015;**28**(2):122-8. doi: [10.3344/kjpp.2015.28.2.122](https://doi.org/10.3344/kjpp.2015.28.2.122). [PubMed: [25852834](https://pubmed.ncbi.nlm.nih.gov/25852834/)]. [PubMed Central: [PMC4387457](https://pubmed.ncbi.nlm.nih.gov/PMC4387457/)].
20. Maniquis Smigel L, Dean Reeves K, Jeffrey Rosen H, Patrick Rabago D. Vertical small-needle caudal epidural injection technique. *Anesth Pain Med*. 2016;**6**(3). e35340. doi: [10.5812/aapm.35340](https://doi.org/10.5812/aapm.35340). [PubMed: [27826539](https://pubmed.ncbi.nlm.nih.gov/27826539/)]. [PubMed Central: [PMC5097855](https://pubmed.ncbi.nlm.nih.gov/PMC5097855/)].
21. Dere K, Akbas M, Bicerer E, Ozkan S, Dagli G. A complication during caudal steroid injection. *J Back Musculoskelet Rehabil*. 2009;**22**(4):227-9. doi: [10.3233/BMR-2009-0236](https://doi.org/10.3233/BMR-2009-0236). [PubMed: [20023355](https://pubmed.ncbi.nlm.nih.gov/20023355/)].
22. McGrath JM, Schaefer MP, Malkamaki DM. Incidence and characteristics of complications from epidural steroid injections. *Pain Med*. 2011;**12**(5):726-31. doi: [10.1111/j.1526-4637.2011.01077.x](https://doi.org/10.1111/j.1526-4637.2011.01077.x). [PubMed: [21392252](https://pubmed.ncbi.nlm.nih.gov/21392252/)].
23. Sullivan WJ, Willick SE, Chira-Adisai W, Zuhosky J, Tyburski M, Dreyfuss P, et al. Incidence of intravascular uptake in lumbar spinal injection procedures. *Spine (Phila Pa 1976)*. 2000;**25**(4):481-6. [PubMed: [10707395](https://pubmed.ncbi.nlm.nih.gov/10707395/)].
24. Fukazawa K, Matsuki Y, Ueno H, Hosokawa T, Hirose M. Risk factors related to accidental intravascular injection during caudal anesthesia. *J Anesth*. 2014;**28**(6):940-3. doi: [10.1007/s00540-014-1840-8](https://doi.org/10.1007/s00540-014-1840-8). [PubMed: [24823700](https://pubmed.ncbi.nlm.nih.gov/24823700/)].

Archive of SID