



# Comparison of the Effects of *Nigella sativa* Oil and Nano-silver on Wound Healing in an Experimental Rat Model

Yalçın Turhan<sup>1\*</sup>, Mehmet Arıcan<sup>1</sup>, Zekeriya Okan Karaduman<sup>1</sup>, Ozan Turhal<sup>2</sup>, Mehmet Gamsızkan<sup>3</sup>, Davut Aydın<sup>4</sup> and Korhan Ozkan<sup>5</sup>

<sup>1</sup>Orhopaedcis and Traumatology Department, Duzce University Medical Faculty, Duzce, Turkey

<sup>2</sup>Orthopaedics and Traumatology Department, Cizre State Hospital, Şırnak, Turkey

<sup>3</sup>Pathology Department, Duzce University Medical Faculty, Duzce, Turkey

<sup>4</sup>Orhopaedcis and Traumatology Department, Hendek State Hospital, Sakarya, Turkey

<sup>5</sup>Orhopaedcis and Traumatology Department, Medeniyet University, Medical Faculty, Istanbul, Turkey

\*Corresponding author: Orhopaedcis and Traumatology Department, Duzce University Medical Faculty, Konuralp St., Center, Duzce, Turkey. Tel: +90-5054432979, Email: yturhan\_2000@yahoo.com

Received 2018 September 26; Revised 2018 November 08; Accepted 2018 November 13.

## Abstract

**Background:** Various topical treatments are available for skin defects. Chronic and complicated wounds can affect a patient's quality of life and cause significant economic burden and even mortality. *Nigella sativa* (NS) oil and silver-containing solutions are separately used to treat various skin disorders.

**Objectives:** The current study aimed at examining the healing potential of NS oil, Nano-silver (AgNPs) solution, and their combination to manage skin wounds in a rat model.

**Methods:** The current clinical experimental study was conducted in the Experimental Animal Unit of Abant İzzet Baysal University, Bolu, Turkey, in 2017. Full-thickness skin defects with a 1 cm<sup>2</sup> surface area were created on the backs of 20 adult Wistar albino rats. The wounds were covered with 1 cm<sup>2</sup> of absorbable oxidized regenerated cellulose (SURGICEL). The rats were numbered and assigned to four groups by simple random sampling. The agents to be compared (saline, NS oil, and AgNPs solution) were administered to the wounds twice daily for 15 days. The wounds were observed for the percentage reduction in original wound size every three days. Scars were harvested on day 15 for histological morphometric analysis.

**Results:** There were no significant differences in the mean vertical scar thickness among the saline (group 1) [1.06 ± 0.18], NS oil (group 2) [0.76 ± 0.14], AgNPs (group 3) [0.98 ± 0.44], and NS oil + AgNPs (group 4) [0.87 ± 0.38] groups (P = 0.556). However, the mean collagen density was significantly lower in groups 1 and 3 [56.50 ± 11.18 and 59.60 ± 3.16] compared with groups 2 and 4 [73.57 ± 6.30 and 80.99 ± 7.19] (P < 0.001).

**Conclusions:** Wounds treated with the combination of NS oil and Nano-silver healed significantly faster, with less scar formation, than the ones treated with NS oil or Nano-silver alone.

**Keywords:** Healing, Nano-silver, *Nigella sativa*, Oil, Rats, Scar, Skin, Wound

## 1. Background

Chronic complicated wounds can affect a patient's quality of life and cause mortality. Wound complications are associated with extended hospital stays, additional morbidities, and increased treatment costs. Although there are many wound dressings aimed to optimize the wound environment for healing, ongoing researches for the better and low-cost products are being made. It is a long time that *Nigella sativa* (NS) oil is used worldwide to treat a variety of skin disorders (1). One of the active metabolites of NS oil is thymoquinone, which protects against the hepatotoxic and nephrotoxic effects

of some chemicals (1). The healing potential of thymoquinone is thought to be related to its antioxidant and anti-inflammatory effects (2). Besides these beneficial effects, the antimicrobial potential of NS oil against multi-drug resistant *Staphylococcus aureus* is also observed. (3). The better and faster effects of NS oil on the wound and burn healing are observed in previous studies (2-4). Silver (Ag) ions have beneficial antibacterial and bacteriostatic effects to treat burns, urinary tract infections, central venous catheter infections, and chronic osteomyelitis (5). Silver nanoparticles (AgNPs) are more potent than micro-particles (6) and have antimicrobial effects against drug-sensitive and multi-drug-resistant pathogenic bacte-

ria, fungi, and viruses (7). Furthermore, AgNPs are effective against endospores of *Bacillus* and *Clostridium* spp. (8). Also, the beneficial effects of AgNPs dressings in wound treatment are shown recently (9).

## 2. Objectives

The current study aimed at evaluating the potential effects of NS oil, AgNPs, and their combination in an experimental rat model of cutaneous wound healing.

## 3. Methods

A clinical experimental study was conducted in the Experimental Animal Unit of Abant Izzet Baysal University. The study was performed in accordance with the guidelines for animal research of the National Institutes of Health (NIH, Bethesda, MD, USA) and 3R principles of the EU directive and approved by the Ethical Committee on Animal Research at Abant Izzet Baysal University, Bolu, Turkey in 2017 (No. 2017/22).

### 3.1. Chemicals

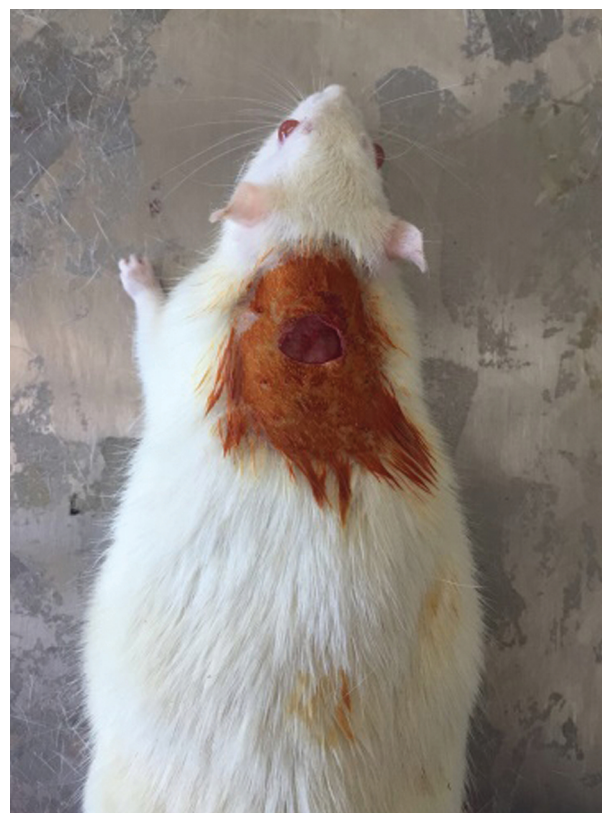The NS oil was produced by cold pressing fresh seeds without the use of chemicals. Also, AgNPs with an average size of 15 nm were used. The particles were obtained using Sodium Borohydride [ $\text{NaBH}_4$ ] as a Hydrogen source [reductant] and Sodium Lauryl Sulfate [Na-Ls] as a surface modifier.

### 3.2. Animals

In the limits permitted by the Ethics Committee and rules, 20 male Wistar-albino rats weighing 200 - 250 g and aged 6 - 8 months were used in accordance with the literature and 3R rule in the current study. The rats were obtained from the Experimental Animal Unit of Abant Izzet Baysal University. The rats were housed in metal cages in a temperature-controlled room under a 12:12 hour light/dark cycle, and fed rodent chow ad libitum, and had free access to water throughout the experiment.

### 3.3. Surgery

The rats were anesthetized with single intramuscular injections of 6 mg/kg Xylazine hydrochloride (Rompun, 23.32 mg/mL; Bayer, Pittsburgh, PA, USA) and 85 mg/kg Ketamine hydrochloride (Ketalar 50 mg/mL; Parke-Davis, Detroit, MI, USA). The backs of the rats were shaved and prepared with 10% antiseptic Povidone-Iodine solution (Povidone; Kim-Pa, Istanbul, Turkey) and full-thickness skin defects with a surface area of  $1 \text{ cm}^2$  were created with a surgi-



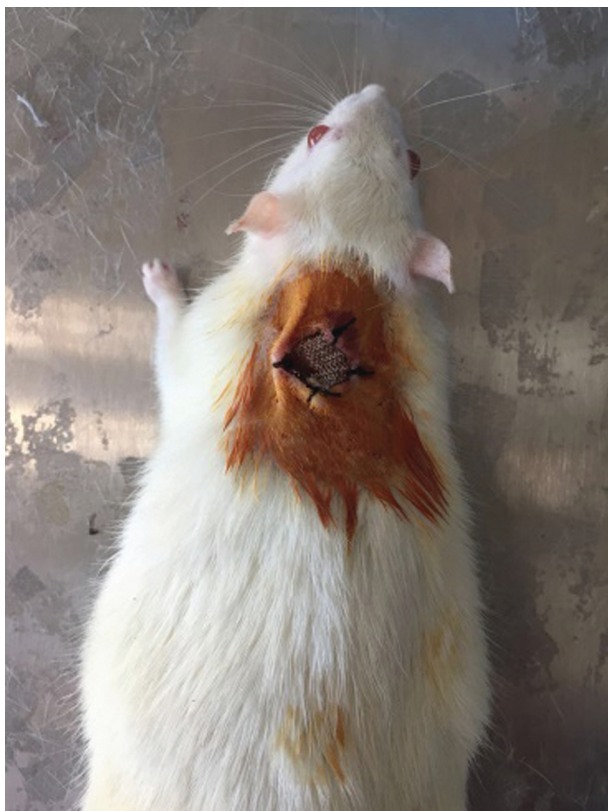**Figure 1.** Full-thickness skin defect was created by a No.15 surgical knife with about  $1 \text{ cm}^2$  surface area on the back of rats.

cal knife. The skin defects were covered with  $1 \text{ cm}^2$  of absorbable Oxidized regenerated cellulose (SURGICEL; Johnson & Johnson, Arlington, TX, USA) attached to the adjacent skin with non-absorbable sutures (2/0 silk) (Figures 1 and 2).

### 3.4. Animal Groups

The animals were numbered and then assigned into four equal groups of five animals each by simple random sampling using the table of random numbers. However, one of the animals in group 1 died the day after the surgery and was excluded from the study. Immediately after surgery, the skin defects of all rats were wet-dressed by 2 mL of saline in group 1 (control group), 2 mL of NS oil in group 2, and 2 mL of AgNPs solution in group 3 as well as 50% NS oil (1 mL) and 50% AgNPs (1 mL) solution in group 4; twice daily for 15 days.

The wounds in all rats were evaluated daily for defect diameter, infection, and contraction by the same observer (Turhan Y). Also, the wound edges were traced onto a transparency and then the tracings placed onto metric grid pa-



**Figure 2.** The skin defect was covered with 1 cm<sup>2</sup> of absorbable oxidized regenerated cellulose Surgicel® attached to the adjacent skin with non-absorbable sutures.

per, and the number of square millimeters counted (10); by this method, the percentage reduction in the original wound size was determined every three days. The rats were sacrificed by intra-cardiac puncture 15 days later, after being anesthetized.

### 3.5. Histopathological Examination

Skin tissue samples were obtained from the defects after sacrificing the rats for histopathological examination. The samples were subject to formaldehyde fixation and processing, embedded in paraffin, and cut into 5- $\mu$ m sections. The sections were stained with Hematoxylin-Eosin and Masson-Trichrome. The scar thickness and collagen density were calculated using morphometric analysis (Figures 3 and 4). Hypertrophic index (HI) and relative collagen density were used for morphometric analysis. HI is the ratio of the highest vertical height of scar area between perichondrium and skin surface to the highest vertical height of normal area around the scar between perichondrium and skin surface. The area with the greatest collagen concentration was observed under a low-power view (X40) of

each sample. Then, a photograph of this area was obtained at high power (X400) with a DS-Fit camera (Nikon, Tokyo, Japan). The photograph was converted to the black and white format, and the collagen density was calculated using Image J software (NIH) (11).

### 3.6. Statistical Analysis

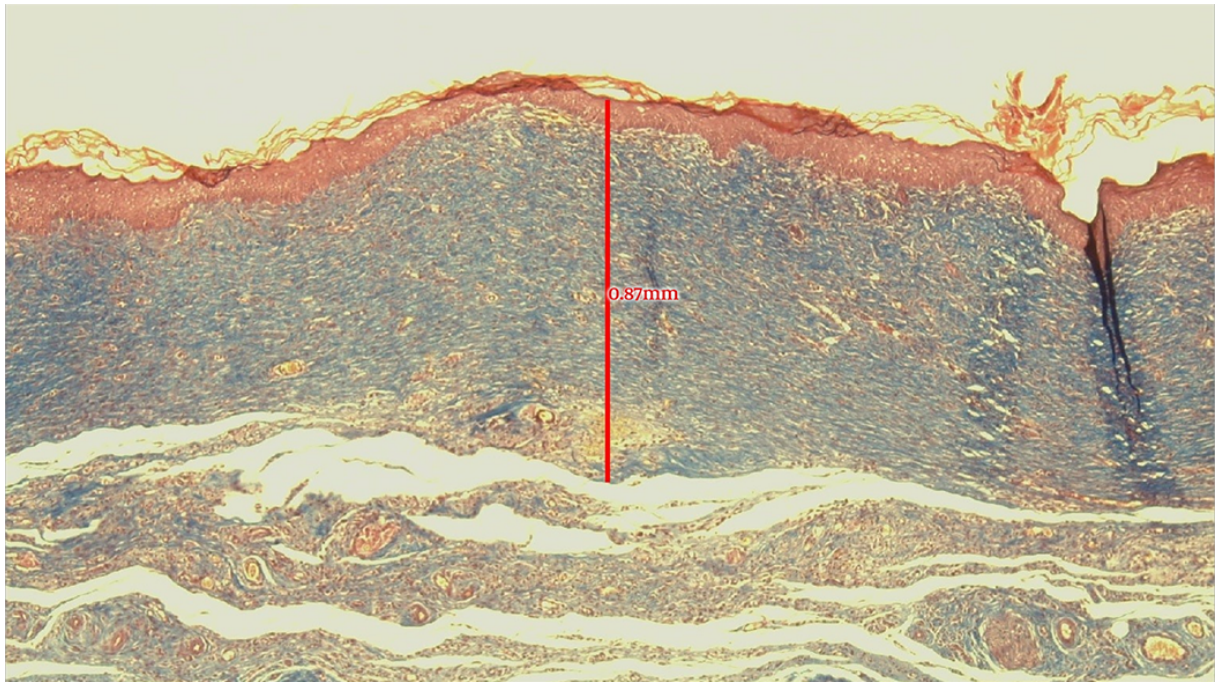
The distribution of continuous data was analyzed with the Shapiro-Wilk test. Since all variables were distributed normally in all groups according to Shapiro-Wilk test results, groups were compared using one-way analysis of variance (ANOVA) followed by the Tukey test for post hoc comparisons. Normality and sphericity assumptions were controlled; since the sphericity assumption was not provided according to the Mauchly test of sphericity, the Greenhouse-Geisser correction for P-values were considered. Repeated-measures of ANOVA were used to analyze time-dependent changes in the wound, between groups. The statistical analyses were performed with IBM SPSS Statistics for Windows, version 22.0 (IBM Corp., Armonk, N.Y., USA) and the significance level was set at 0.05.

## 4. Results

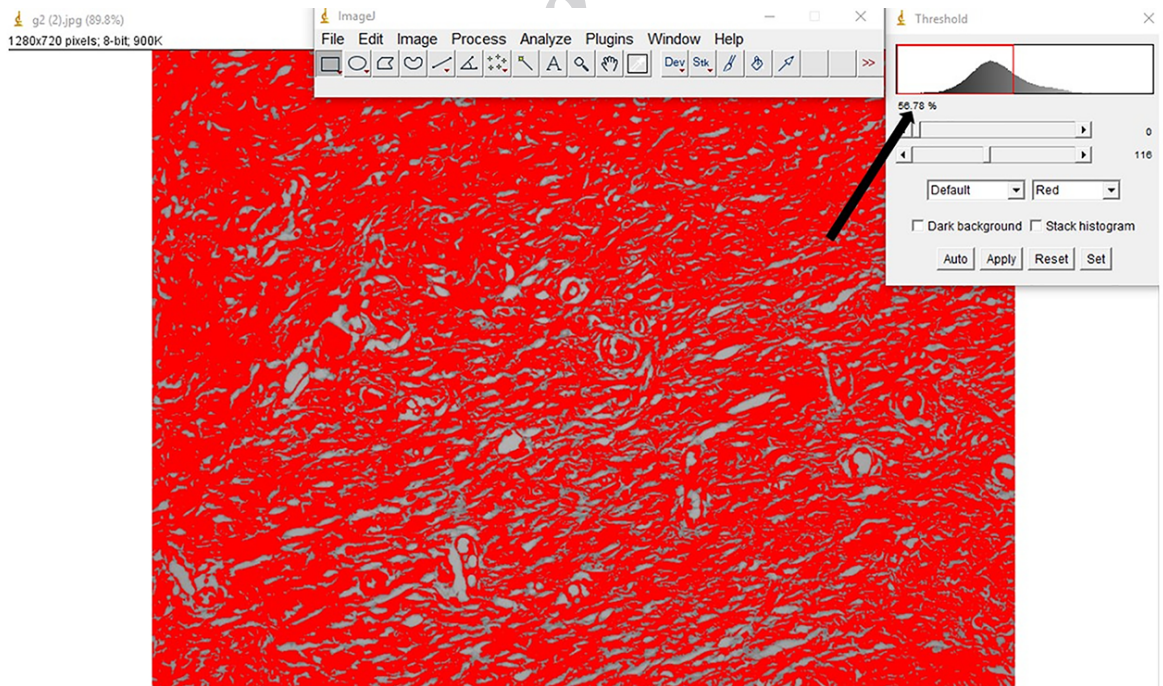
Histopathologically, all scars showed increased collagen density and loss of skin appendages compared with normal skin (Figure 5). The mean collagen density was 56.50%  $\pm$  11.18%, 73.57%  $\pm$  6.30%, 59.60%  $\pm$  3.16%, and 80.99%  $\pm$  7.19% in groups 1 to 4, respectively. The mean vertical scar thickness was 1.06  $\pm$  0.18, 0.76  $\pm$  0.14, 0.98  $\pm$  0.44, and 0.87  $\pm$  0.38 mm, respectively. The mean collagen density was highest in group 4 and the vertical scar thickness was lowest in group 2 (Table 1).

Statistically, there were no significant differences in mean vertical scar thickness among the groups ( $P = 0.556$ ). The mean collagen densities were significantly lower in groups 1 and 3 than in groups 2 and 4 ( $P < 0.001$ ). Groups 1 and 3 were similar to each other ( $P = 0.917$ ), as were groups 2 and 4 ( $P = 0.394$ ). Using the combination of NS oil and Ag-NPs (group 4), the mean collagen density was higher, and the mean vertical scar thickness was lower than those of the other groups (Table 1).

The day/group interaction was significant in terms of the temporal changes in the wound concentration (as %), which differed among the groups ( $P < 0.001$ ). The main effects of group ( $P < 0.001$ ) and time ( $P < 0.001$ ) were also significant. The differences between successive days were significant within each group, as were the differences among the groups when each day was considered separately (Table 2 and Figure 6).



**Figure 3.** Vertical scar thickness was measured from the deepest part of the scar to the skin surface for each sample. For example, vertical scar thickness of this sample was 0.87 mm.



**Figure 4.** Calculation of collagen density using morphometric analysis. For example, collagen density of this sample was calculated as 56.78 (black arrow).

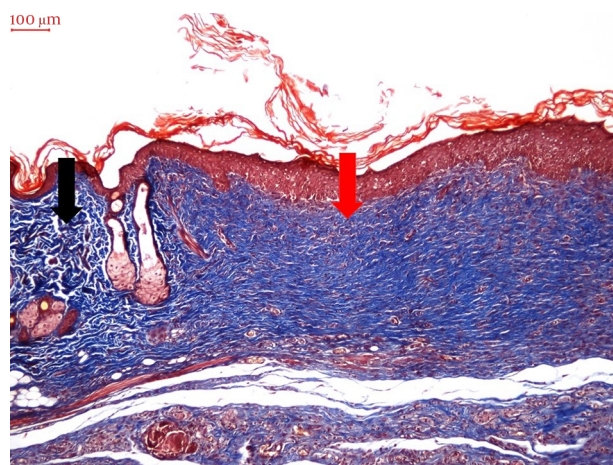
**Table 1.** Collagen Density and Mean Scar Thickness Based on Histopathological Examinations in the Study Groups

Groups <sup>a</sup>	Collagen Density <sup>b</sup>	BCa 95%CI	P Value	Scar Thickness <sup>b</sup>	BCa 95%CI	P Value	N
Group 1	56.50 ± 11.18a	(46.54 - 67.03)	< 0.001	1.06 ± 0.18	(0.95 - 1.22)	0.556	4
Group 2	73.57 ± 6.30b	(66.42 - 78.02)		0.76 ± 0.14	(0.60 - 0.87)		5
Group 3	59.60 ± 3.16a	(57.54 - 62.63)		0.98 ± 0.44	(0.68 - 1.29)		5
Group 4	80.99 ± 7.19b	(72.60 - 87.25)		0.87 ± 0.38	(0.59 - 1.18)		5

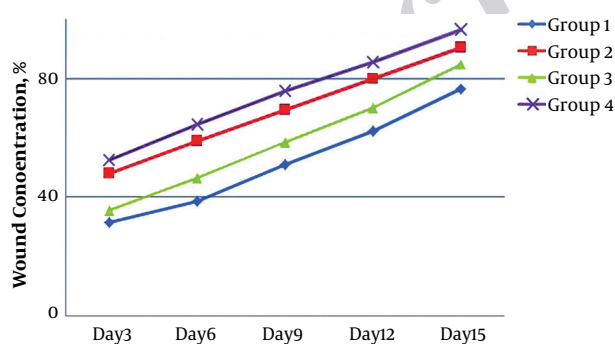
Abbreviations: BCa, bias-corrected accelerated; CI, confidence interval.

<sup>a</sup> Group 1, Saline; Group 2, *Nigella sativa* (NS) oil; Group 3, Nano-silver (AgNPs); Group 4, NS oil + AgNPs.

<sup>b</sup> Values are expressed as mean ± SD.



**Figure 5.** Increased collagen density and loss of skin appendage in the scar area (red arrow) compared with the normal skin (black arrow) (Masson's trichrome stain, X100).



**Figure 6.** Changes of wound concentration (percentage reduction in original wound size) determined by acetate tracing technique according to all groups.

**Table 2.** Percentage Reduction of Wound Concentration in the Groups Based on the Studied Days

Day <sup>a</sup>	Reduction of Wound Concentration <sup>b</sup> , %	N
<b>3</b>		
Group 1	31.40 ± 1.63	4
Group 2	47.84 ± 1.47	5
Group 3	35.82 ± 0.86	5
Group 4	52.49 ± 0.70	5
<b>6</b>		
Group 1	38.64 ± 1.30	4
Group 2	58.95 ± 0.89	5
Group 3	46.34 ± 2.19	5
Group 4	64.49 ± 0.98	5
<b>9</b>		
Group 1	51.04 ± 1.20	4
Group 2	69.29 ± 1.26	5
Group 3	58.61 ± 2.38	5
Group 4	75.67 ± 0.56	5
<b>12</b>		
Group 1	62.38 ± 0.88	4
Group 2	79.97 ± 1.04	5
Group 3	70.07 ± 1.40	5
Group 4	85.56 ± 0.71	5
<b>15</b>		
Group 1	76.42 ± 0.60	4
Group 2	90.49 ± 1.65	5
Group 3	84.93 ± 2.09	5
Group 4	96.22 ± 0.46	5

<sup>a</sup> Group 1, Saline; Group 2, *Nigella sativa* (NS) oil; Group 3, Nano-silver (AgNPs); Group 4, NS oil + AgNPs.

<sup>b</sup> Values are expressed as mean ± SD.

## 5. Discussion

The skin is the largest organ in the body, has many vital functions in homeostasis, and acts as a barrier protecting

against infections caused by bacteria, viruses, and fungi (12). If the integrity of the skin is disturbed, pathogens can cause infections more easily. Normal wound healing involves gradual completion of necessary biological processes in a specific order, involving the restructuring of damaged tissue to restore it to an as-close-to-normal state as possible (13).

The current study was the first to compare the effects of NS oil and Nano-AgNPs, alone and in combination to investigate wound healing in a rat model. NS oil and AgNPs are used to treat various skin disorders for many years. The potential antimicrobial and wound-healing effects of NS oil, and the antimicrobial potential of Ag ions and their use to treat burns and skin defects are well known (1-8, 14, 15).

The antimicrobial properties of therapeutic agents can accelerate wound healing (13). Although various studies examined the potential therapeutic effects of NS oil on the human body, few examined its topical use to treat skin wounds. Nearly all of such studies showed that NS had positive effects on wound healing (16-18). The free radicals produced after skin damage hinder the healing process, and treatment with NS oil reduces the production of free radicals and promotes healing (19).

AgNPs have potent effects against multi-drug resistant bacteria and potential benefits in wound healing (14, 15, 20, 21). The antimicrobial properties of AgNPs arise from their relatively large surface area and Nano size. AgNPs penetrate the bacterial cell membrane and enter the cell, where they interact with the respiratory chain and cell division, and ultimately cause cell death (22-24).

The skin defects made in the rats in the current study were covered with absorbable oxidized regenerated cellulose (SURGICEL®). SURGICEL is used clinically for hemostasis in surgeries. When used for wound hemostasis following skin peeling, tissue biopsies, nail avulsion, or trauma, it is absorbed from the surgical site without leaving any foreign material (25, 26). A recent study found that SURGICEL did not delay wound healing compared with control (no treatment for the defect) and gelatin (SPONGOSTAN®) groups (27). The purpose of placing SURGICEL on the skin defects in the current study was to create a carrier for the active ingredients applied to the surface (NS oil and AgNPs solution) and facilitate their absorption through the wound.

The ability of NS oil for better results in the reduction of wound size is observed (18). In a recent study by Javadi et al., the combination of NS oil with honey revealed the best results in the reduction of the wound size over time (4). In addition to NS oil, the ability of AgNPs to enhance the reduction of wound size was shown by Kantiputi et al. (28). In their study, AgNPs showed better results than con-

trol and Ag Sulphadiazine applied groups especially with the combination of Nano-zinc oxide and AgNPs. Also in the current study, the percentage reduction in wound size differed significantly within each group over time, with faster healing observed in group 4 treated with both NS oil and Nano-silver (Table 2). The potential of NS oil to accelerate the burn healing process by increasing the granulation tissue formation and collagen synthesis was observed in previous studies (16, 18). In the current study, the healing potential of NS oil in combination with Nano-silver was histologically confirmed. While there were no significant differences in the mean vertical scar thickness among groups ( $P = 0.556$ ), the difference in mean collagen density among the groups was significant ( $P < 0.001$ ), lower in groups 1 and 3 than in groups 2 and 4. The combination of the two agents (group 4) resulted in less vertical scar formation and higher collagen density for better wound healing. The better results obtained with the combination of the two agents in group 4 could be due to the synergistic antibacterial and anti-inflammatory effects of AgNPs and NS oil.

### 5.1. Conclusion

Through their antimicrobial, antioxidant, and anti-inflammatory effects, the combination of NS oil and AgNPs appears to be useful for wound management. Although it seems to be the repetition of the effect of NS on wound healing, this is the first study to display the synergistic effects of AgNPs with NS oil for wound healing; thus, this is a new approach and displays a promising result with a synergistic activity of both components. In this context, this can be considered as a new therapeutic agent with minimal cost. The weak point of this study may be the sample size.

### Footnotes

**Conflict of Interests:** The authors have not received financial payments or other benefits from any commercial entity, and all of them declared no conflict of interest during the preparation and publication of this manuscript.

**Ethical Considerations:** The study was performed in accordance with the guidelines for Animal Research of the National Institutes of Health (NIH, Bethesda, MD, USA) and 3R principles of the EU directive. The current study protocol was approved by the Ethics Committee of Abant Izzet Baysal University Animal Research (No. 2017/22).

**Funding/Support:** This research received no specific grant from any funding agency in the public, commercial, or not-for-profit sectors.

## References

- Ali BH, Blunden G. Pharmacological and toxicological properties of *Nigella sativa*. *Phytother Res*. 2003;17(4):299–305. doi: [10.1002/ptr.1309](https://doi.org/10.1002/ptr.1309). [PubMed: [12722128](https://pubmed.ncbi.nlm.nih.gov/12722128/)].
- Awad EM. In vitro decreases of the fibrinolytic potential of cultured human fibrosarcoma cell line, HT1080, by *Nigella sativa* oil. *Phytomedicine*. 2005;12(1-2):100–7. doi: [10.1016/j.phymed.2003.09.003](https://doi.org/10.1016/j.phymed.2003.09.003). [PubMed: [15693715](https://pubmed.ncbi.nlm.nih.gov/15693715/)].
- Emeka LB, Emeka PM, Khan TM. Antimicrobial activity of *Nigella sativa* L. seed oil against multi-drug resistant *Staphylococcus aureus* isolated from diabetic wounds. *Pak J Pharm Sci*. 2015;28(6):1985–90. [PubMed: [26639493](https://pubmed.ncbi.nlm.nih.gov/26639493/)].
- Javadi SMR, Hashemi M, Mohammadi Y, MamMohammadi A, Sharifi A, Makarchian HR. Synergistic effect of honey and *Nigella sativa* on wound healing in rats. *Acta Cir Bras*. 2018;33(6):518–23. doi: [10.1590/s0102-865020180060000006](https://doi.org/10.1590/s0102-865020180060000006). [PubMed: [30020313](https://pubmed.ncbi.nlm.nih.gov/30020313/)].
- Feng QL, Wu J, Chen GQ, Cui FZ, Kim TN, Kim JO. A mechanistic study of the antibacterial effect of silver ions on *Escherichia coli* and *Staphylococcus aureus*. *J Biomed Mater Res*. 2000;52(4):662–8. doi: [10.1002/1097-4636\(20001215\)52:4<662::AID-JBM10>3.0.CO;2-3](https://doi.org/10.1002/1097-4636(20001215)52:4<662::AID-JBM10>3.0.CO;2-3). [PubMed: [11033548](https://pubmed.ncbi.nlm.nih.gov/11033548/)].
- Liu W, Wu Y, Wang C, Li HC, Wang T, Liao CY, et al. Impact of silver nanoparticles on human cells: Effect of particle size. *Nanotoxicology*. 2010;4(3):319–30. doi: [10.3109/17435390.2010.483745](https://doi.org/10.3109/17435390.2010.483745). [PubMed: [20795913](https://pubmed.ncbi.nlm.nih.gov/20795913/)].
- Albers CE, Hofstetter W, Siebenrock KA, Landmann R, Klenke FM. In vitro cytotoxicity of silver nanoparticles on osteoblasts and osteoclasts at antibacterial concentrations. *Nanotoxicology*. 2013;7(1):30–6. doi: [10.3109/17435390.2011.626538](https://doi.org/10.3109/17435390.2011.626538). [PubMed: [22013878](https://pubmed.ncbi.nlm.nih.gov/22013878/)].
- Gopinath PM, Ranjani A, Dhanasekaran D, Thajuddin N, Archunan G, Akbarsha MA, et al. Multi-functional nano silver: A novel disruptive and theranostic agent for pathogenic organisms in real-time. *Sci Rep*. 2016;6:34058. doi: [10.1038/srep34058](https://doi.org/10.1038/srep34058). [PubMed: [27666290](https://pubmed.ncbi.nlm.nih.gov/27666290/)]. [PubMed Central: [PMC5036090](https://pubmed.ncbi.nlm.nih.gov/PMC5036090/)].
- Ghannam SF, Korayem HE, Farghaly LM, Hosny S. The effect of chitosan nanosilver dressing versus mesenchymal stem cells on wound healing. *J Africa Ass Phys Sci*. 2018;6(1):23–31.
- Majeske C. Reliability of wound surface area measurements. *Phys Ther*. 1992;72(2):138–41. doi: [10.1093/ptj/72.2.138](https://doi.org/10.1093/ptj/72.2.138). [PubMed: [1549635](https://pubmed.ncbi.nlm.nih.gov/1549635/)].
- Caliskan E, Gamsizkan M, Acikgoz G, Durmus M, Toklu S, Dogrul A, et al. Intralesional treatments for hypertrophic scars: Comparison among corticosteroid, 5-fluorouracil and botulinum toxin in rabbit ear hypertrophic scar model. *Eur Rev Med Pharmacol Sci*. 2016;20(8):1603–8. [PubMed: [27160135](https://pubmed.ncbi.nlm.nih.gov/27160135/)].
- Upadhyay NK, Kumar R, Siddiqui MS, Gupta A. Mechanism of wound-healing activity of *Hippophae rhamnoides* L. leaf extract in experimental burns. *Evid Based Complement Alternat Med*. 2011;2011:659705. doi: [10.1093/ecam/nep189](https://doi.org/10.1093/ecam/nep189). [PubMed: [19946025](https://pubmed.ncbi.nlm.nih.gov/19946025/)]. [PubMed Central: [PMC3152935](https://pubmed.ncbi.nlm.nih.gov/PMC3152935/)].
- Nayak S, Nalabothu P, Sandiford S, Bhogadi V, Adogwa A. Evaluation of wound healing activity of *Allamanda cathartica*. L. and *Laurus nobilis*. L. extracts on rats. *BMC Complement Altern Med*. 2006;6:12. doi: [10.1186/1472-6882-6-12](https://doi.org/10.1186/1472-6882-6-12). [PubMed: [16597335](https://pubmed.ncbi.nlm.nih.gov/16597335/)]. [PubMed Central: [PMC1456996](https://pubmed.ncbi.nlm.nih.gov/PMC1456996/)].
- Chaloupka K, Malam Y, Seifalian AM. Nanosilver as a new generation of nanoparticle in biomedical applications. *Trends Biotechnol*. 2010;28(11):580–8. doi: [10.1016/j.tibtech.2010.07.006](https://doi.org/10.1016/j.tibtech.2010.07.006). [PubMed: [20724010](https://pubmed.ncbi.nlm.nih.gov/20724010/)].
- Martinez-Gutierrez F, Thi EP, Silverman JM, de Oliveira CC, Svensson SL, Vanden Hoek A, et al. Antibacterial activity, inflammatory response, coagulation and cytotoxicity effects of silver nanoparticles. *Nanomedicine*. 2012;8(3):328–36. doi: [10.1016/j.nano.2011.06.014](https://doi.org/10.1016/j.nano.2011.06.014). [PubMed: [21718674](https://pubmed.ncbi.nlm.nih.gov/21718674/)].
- Yaman I, Durmus AS, Ceribasi S, Yaman M. Effects of *Nigella sativa* and silver sulfadiazine on burn wound healing in rats. *Veterinari Med*. 2010;55(No. 12):619–24. doi: [10.17221/2948-vetmed](https://doi.org/10.17221/2948-vetmed).
- Abu-Zinadah O. Using *Nigella sativa* oil to treat and heal chemical induced wound of rabbit skin. *J King Abdulaziz Univ Sci*. 2009;21(2):335–46. doi: [10.4197/Sci.21-2.11](https://doi.org/10.4197/Sci.21-2.11).
- Sarkhail P, Esmaily H, Baghaei A, Shafiee A, Abdollahi M, Khademi Y, et al. Burn healing potential of *Nigella sativa* seed oil in rats. *Int J Pharm Sci Res*. 2011;2(1):34.
- Kanter M, Coskun O, Kalayci M, Buyukbas S, Cagavi F. Neuroprotective effects of *Nigella sativa* on experimental spinal cord injury in rats. *Hum Exp Toxicol*. 2006;25(3):127–33. doi: [10.1191/0960327106ht6080a](https://doi.org/10.1191/0960327106ht6080a). [PubMed: [16634331](https://pubmed.ncbi.nlm.nih.gov/16634331/)].
- Rai M, Yadav A, Gade A. Silver nanoparticles as a new generation of antimicrobials. *Biotechnol Adv*. 2009;27(1):76–83. doi: [10.1016/j.biotechadv.2008.09.002](https://doi.org/10.1016/j.biotechadv.2008.09.002). [PubMed: [18854209](https://pubmed.ncbi.nlm.nih.gov/18854209/)].
- Abou El-Nour KMM, Eftaiha A, Al-Warthan A, Ammar RAA. Synthesis and applications of silver nanoparticles. *Arab J Chem*. 2010;3(3):135–40. doi: [10.1016/j.arabjc.2010.04.008](https://doi.org/10.1016/j.arabjc.2010.04.008).
- Konop M, Damps T, Misicka A, Rudnicka L. Certain aspects of silver and silver nanoparticles in wound care: A minireview. *J Nanomaterials*. 2016;2016:1–10. doi: [10.1155/2016/7614753](https://doi.org/10.1155/2016/7614753).
- Ding L, Shan X, Zhao X, Zha H, Chen X, Wang J, et al. Spongy bilayer dressing composed of chitosan-Ag nanoparticles and chitosan-Bletilla striata polysaccharide for wound healing applications. *Carbohydr Polym*. 2017;157:1538–47. doi: [10.1016/j.carbpol.2016.11.040](https://doi.org/10.1016/j.carbpol.2016.11.040). [PubMed: [27987866](https://pubmed.ncbi.nlm.nih.gov/27987866/)].
- Das S, Baker AB. Biomaterials and nanotherapeutics for enhancing skin wound healing. *Front Bioeng Biotechnol*. 2016;4:82. doi: [10.3389/fbioe.2016.00082](https://doi.org/10.3389/fbioe.2016.00082). [PubMed: [27843895](https://pubmed.ncbi.nlm.nih.gov/27843895/)]. [PubMed Central: [PMC5087310](https://pubmed.ncbi.nlm.nih.gov/PMC5087310/)].
- Venn RD. Reduction of postsurgical blood-replacement needs with Surgicel hemostasis. *Med Times*. 1965;93(10):1113–6. [PubMed: [5826774](https://pubmed.ncbi.nlm.nih.gov/5826774/)].
- Blau S, Kanof NB, Simonsen L. Absorbable hemostatic gauze Surgicel® in dermabrasion and dermatologic surgery. *Acta Derm Venereol*. 1960;40:358–61.
- Kang BS, Na YC, Jin YW. Comparison of the wound healing effect of cellulose and gelatin: An in vivo study. *Arch Plast Surg*. 2012;39(4):317–21. doi: [10.5999/aps.2012.39.4.317](https://doi.org/10.5999/aps.2012.39.4.317). [PubMed: [22872833](https://pubmed.ncbi.nlm.nih.gov/22872833/)]. [PubMed Central: [PMC3408275](https://pubmed.ncbi.nlm.nih.gov/PMC3408275/)].
- Kantipudi S, Sunkara JR, Rallabhandi M, Thonangi CV, Cholla RD, Kollu P, et al. Enhanced wound healing activity of Ag-ZnO composite NPs in Wistar Albino rats. *IET Nanobiotechnol*. 2018;12(4):473–8. doi: [10.1049/iet-nbt.2017.0087](https://doi.org/10.1049/iet-nbt.2017.0087). [PubMed: [29768232](https://pubmed.ncbi.nlm.nih.gov/29768232/)].