



# Successful Treatment of Heart Failure Due to Simultaneous Poisoning with Aluminum Phosphide and Zinc Phosphide: A Case Report

Aliasghar Manouchehri<sup>1</sup>, Reza Mohseni Ahangar<sup>1</sup>, Pedram Bigvand<sup>1</sup>, Samaneh Nakhaee<sup>2</sup> and Omid Mehrpour<sup>2,\*</sup>

<sup>1</sup>Department of Internal Medicine, School of Medicine, Babol University of Medical Sciences, Babol, Iran

<sup>2</sup>Medical Toxicology and Drug Abuse Research Center (MTDRC), Birjand University of Medical Sciences, Birjand, Iran

\*Corresponding author: Omid Mehrpour, Medical Toxicology and Drug Abuse Research Center (MTDRC), Birjand University of Medical Sciences, Moallem Avenue, Birjand, 9717853577, Iran. Tel: +98-9155598571, E-mail: omid.mehrpour@yahoo.com.au

Received 2017 June 28; Revised 2017 November 29; Accepted 2018 February 14.

## Abstract

**Introduction:** Rodenticides are considered a global challenge to public health. Two major compounds in this category include aluminum phosphide and zinc phosphide. However, the simultaneous use of aluminum phosphide and zinc phosphide has not been reported in the literature.

**Case Presentation:** We present the case of a 20-year-old female, who was poisoned with both a rice tablet and powdered rat poison. She was admitted to a university-affiliated hospital, Babol, Iran in July 2016. Resuscitative and supportive measures were applied, including prophylactic intubation, gastric lavage with a bicarbonate solution, and intravenous administration of N-acetylcysteine (NAC), magnesium sulfate, calcium gluconate, and bicarbonate compounds. In case of a blood sugar level above 100 mg/dL, regular insulin was infused. After the diagnosis of phosphine-induced cardiomyopathy, digitization with digoxin was prescribed for the patient.

**Conclusions:** This case report presents the possible positive effects of digoxin, insulin, and antioxidant therapy on simultaneous poisoning with aluminum phosphide and zinc phosphide.

**Keywords:** Aluminum Phosphide, Antioxidant, Cardiomyopathy, Case Report, Heart Failure, Insulin, Poisoning, Rat Poison, Rodenticides, Zinc Phosphide

## 1. Introduction

Rodenticides are considered a global challenge to public health. Annually, 250,000 to 370,000 people die from deliberate ingestion of pesticides, which is responsible for about one-third of suicidal attempts worldwide (1). Metal phosphide compounds are highly effective insecticides and rodenticides used to protect crops. Poisoning with these compounds is caused either directly through consumption or indirectly through accidental inhalation of the released phosphine gas.

The ingested metal phosphide and phosphine compounds react with the acidic stomach content, thereby releasing the highly toxic phosphine gas (2). Two major compounds in this category include aluminum phosphide (ALP) and zinc phosphide (ZnP). ALP can be found as tablets, pellets, or dark-gray powder. Even 500 mg of this compound can be fatal for humans (3). Today, ALP poisoning, which is associated with a high mortality rate (30% - 100%), has become a major health concern in many poisoning

management centers in Iran (4, 5). On the other hand, ZnP is in powder form. It is more slow-acting than ALP and has a lethal dose of 4 - 8 g (6). Mortality due to ZnP poisoning reportedly ranges from 37% to 100% (6). With respect to the mortality rates, these compounds are associated with high mortality, while no specific antidotes have been yet recommended (6, 7).

The clinical symptoms of poisoning vary depending on the dose, route, and duration of exposure. Symptoms of acute poisoning include gastrointestinal manifestations, refractory hypotension and shock, dysrhythmia, palpitations, cardiovascular collapse, and acute respiratory distress syndrome manifestations (8). Hyperglycemia and electrocardiographic changes are representative of poor prognosis in paraclinical variables (9). Within the first 6 hours, the prominent electrocardiographic changes include sinus tachycardia with altered ST and T-waves. Also, the rhythm changes include tachycardia, ventricular fibrillation, supraventricular tachycardia, atrial fibrillation,

and atrial flutter (10, 11).

Although various treatments have been suggested to decrease toxin absorption, all approaches have been only supportive (12, 13). However, an effective treatment for phosphide poisoning, using intraaortic balloon pump (IABP) and digoxin, has been reported in previous research. In addition, studies have shown that glucagon, digoxin, and antioxidants independently exert beneficial effects on poisoning (5, 13, 14).

To the best of our knowledge, simultaneous ingestion of ALP and ZnP has not been reported in the literature. Therefore, the aim of the current study was to report a case of acute poisoning due to intentional consumption of ALP and ZnP in a young female patient.

## 2. Case Presentation

The patient was a single, high school-graduated, 20-year-old girl, who was primarily admitted to a local private clinic with symptoms, including nausea, vomiting, and abdominal pain. She was treated as an outpatient with the primary diagnosis of viral infection with an unknown origin. After about one hour, following general deterioration and escalation of abdominal pain and severe lethargy, she was referred to Shahid Beheshti Hospital (a poisoning referral center), affiliated to Babol University of Medical Sciences (Babol, Iran) for further treatments in July 2016.

After the initial history-taking in the emergency room, she admitted to the use of a rice pill (i.e., ALP), along with powdered rat poison at home. She did not have any relevant medical history. Data were collected using a questionnaire, and laboratory information were gathered from the medical records. After obtaining the complete medical history and estimating the interval between treatment and rice pill poisoning (about 3- hours), the treatment team applied resuscitative and supportive measures, including prophylactic intubation, gastric lavage with a bicarbonate solution, and intravenous administration of N-acetylcysteine (NAC), magnesium sulfate, calcium gluconate, and bicarbonate compounds.

The results of primary physical examination upon admission were as follows: blood pressure (BP), 110/60 mmHg; pulse rate (PR), 110 beats/min; respiratory rate (RR), 13 per minute; temperature (axillary), 37.1°C; oxygen saturation (O<sub>2</sub>sat), 94%; and body mass index, 21.27 kg/m<sup>2</sup>. Due to deterioration of her general condition and need for intensive care unit (ICU) admission, she was transferred to the hospital ICU after 12 hours. The vital signs of the sedated patient were as follows: BP, 105/50 mmHg (despite receiving 5 µg/min of vasopressor norepinephrine); PR, 120 beats/min; RR during mechanical ventilation, 12 per

minute (ventilation volume, 350; FiO<sub>2</sub>, 60%; PEEP, 8); and axillary body temperature, about 37.1°C.

The oxygen saturation varied between 89% and 92% in the patient. The arterial blood gas (ABG) analysis upon admission was as follows: pH, 7.26; HCO<sub>3</sub>, 20.3; PCO<sub>2</sub>, 48; and lactate level > 15. In addition, the laboratory test results were as follows: hemoglobin level, 9.5; platelet count, 304,000; white blood cell count, 19,800; serum sodium, 150 mEq/mL; serum potassium, 3.9 mEq/mL; serum calcium, 8.5 mg/dL; serum magnesium, 2.6 mg/dL; blood urea nitrogen, 14 mg/dL; blood creatinine, 1.1 mg/dL; blood sugar, 175 mg/dL; and negative troponin I (Table 1).

A central venous catheter was inserted in order to assess the central venous pressure (CVP). The patient underwent treatment with NAC (6 g every 8 hours), calcium gluconate (1 g every 8 hours), magnesium sulfate (1 g every 6 hours), vitamin C (500 mg every 12 hours), and infusion of sodium bicarbonate 7.5% (1 vial per liter of intravenous fluid) with intravenous hydrocortisone (100 mg every 8 hours), infusion therapy, and continuous administration of vasopressors. In case of blood sugar level above 100 mg/dL, regular insulin was infused at 3 units per hour.

During hospitalization, the patient developed hypotension on the second day (85/45 mmHg). The CVP increased to about 18 mmHg. She also experienced tachycardia episodes in form of atrial fibrillation (Figure 1). Considering her condition, atrial fibrillation attacks, portable echocardiography data (i.e., EF 35%, moderate LV enlargement, mild MR, mild TR, and PAP 30 mm/Hg), and diagnosis of phosphine-induced cardiomyopathy, the rapid digitization approach with 0.5 mg of digoxin was used every six hours on the first day, followed by 0.25 mg per day.

At the end of the second day of treatment with digoxin, the patient was hemodynamically stable and had a sinusoidal heart rate pattern. On the fourth day of treatment, echocardiography showed normal left ventricular function, and accordingly, digoxin treatment was terminated. It should be noted that on the second day of hospitalization, the patient's hepatic enzymes were increasingly rising, reaching their peak level on the third day of hospitalization. The enzymes declined after that until the patient was discharged. Also, the coagulation tests were in the normal range during hospitalization.

In order to control acute liver failure, some supportive measures were applied, such as volume control, avoidance of drugs with hepatic metabolism, and NAC treatment until the patient's discharge. Finally, after six days of hospitalization, she regained hemodynamic stability, and use of vasopressor was terminated. Following that, the tracheal tube was removed, and she was discharged from the hospital with a good general condition. The laboratory measures during admission are presented in Table 1.

**Table 1.** The Laboratory Test Results in a Patient with Simultaneous ALP and ZnP Poisoning on Admission and Follow-Ups in Shahid Beheshti Hospital

Laboratory Findings	On Admission	Six Hours After Admission	Twelve Hours After Admission	One Day After Admission	Two Days After Admission	Three Days After Admission	Four Days After Admission	Five Days After Admission
pH	7.26	7.32	7.45	7.40	7.57	7.57	7.50	7.48
PCO <sub>2</sub> , mmHg	48	57	47	50	54	47	45	44
HCO <sub>3</sub> , mEq/L	20.3	25.8	30	30.6	43.6	39.8	36.3	29.8
Lactate, mmol/L	>15	9.3	6.6	4.6	2.6	1.7	1.2	1.3
Na, mEq/L	155	ND	ND	152	145	144	139	140
K, mEq/L	3.9	ND	ND	3.3	3.7	3.6	2.9	3.6
BUN, mg/dL	14	ND	ND	21	18	19	16	15
Cr, mg/dL	1.1	ND	ND	1.25	1.2	1	0.9	0.8
BS	175	ND	ND	135	147	140	136	130
ALT, IU/L	10	ND	ND	83	ND	895	546	395
AST, IU/L	12	ND	ND	140	ND	580	252	75
Alk, IU/L	170	ND	ND	179	ND	768	640	550
INR	1.4	ND	ND	1.5	ND	1.4	1.4	1.3
PTT, s	34	ND	ND	36	ND	33	32	32
CPK, U/L	121	ND	ND	220	ND	3700	2030	950

Abbreviations: Alk, alkaline phosphatase; ALT, alanine aminotransferase; AST, aspartate aminotransferase; BS, blood sugar; BUN, blood urea nitrogen; CPK, creatine phosphokinase; Cr, creatinine; HCO<sub>3</sub>, serum bicarbonate; INR, international normalized ratio; K, potassium; Na, sodium; ND, not determined; PCO<sub>2</sub>, partial pressure of carbon dioxide; PTT, prothrombin time.

### 3. Discussion

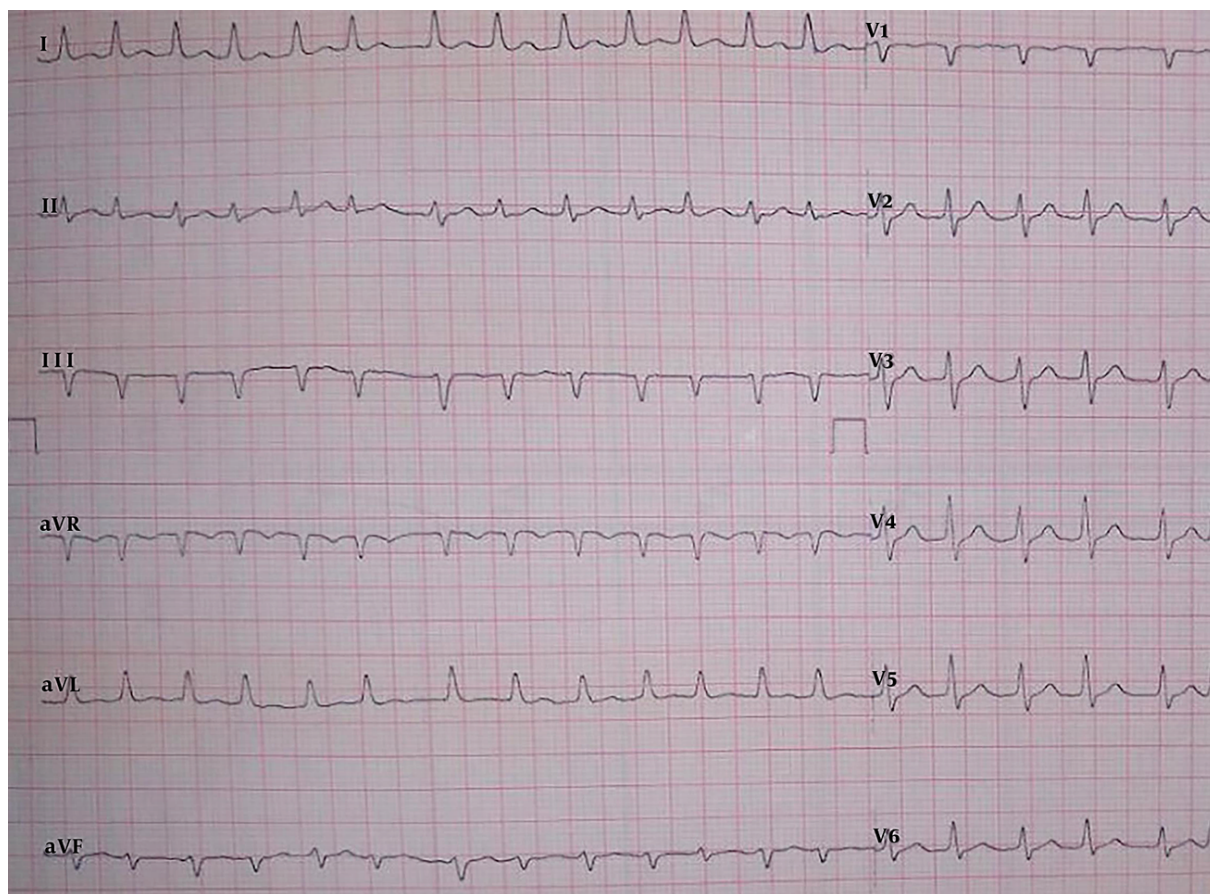
Despite the release of phosphine gas and the related symptoms, ALP and ZnP poisoning may be associated with different symptoms. Consistent with our findings, previous studies have shown that the most common clinical signs of ALP and ZnP poisoning include vomiting, abdominal pain, palpitation, dyspnea, tachypnea, metabolic acidosis, shock, and hypotension. Furthermore, studies have indicated that hepatic enzymes might increase during poisoning (6, 15). The most important dissimilarity of ZnP and ALP poisoning is the relatively longer time of symptom appearance upon poisoning by ZnP. Also, development of acute liver failure has been almost exclusively reported in the first week after ZnP poisoning (16).

Acute ZnP or ALP poisoning produces phosphine gas within 30 minutes of consumption. It is a highly toxic substance, which can be harmful to the respiratory tract and lead to serious systemic poisoning. Cardiogenic shock and cardiovascular collapse in phosphine gas poisoning may be due to the direct effects of poisoning on heart muscle cells, intravascular fluid leakage into the third space, severe metabolic acidosis, and poor tissue perfusion (17). Another significant adverse side effect of poisoning with rice tablet is cardiac arrhythmia (about 36%), besides other fac-

tors such as refractory hypotension, acidosis, kidney failure, multiple organ failure, and respiratory distress syndrome (13). Therefore, in addition to routine supportive care, control of cardiogenic shock and oxidative stress seems necessary.

There is no potent antidote for ALP poisoning. Supportive critical care for balance blood pH, electrolyte, and arterial blood pressure is the main treatment approach. In some cases of severe acidosis and acute renal failure, dialysis for the correction of metabolic acidosis has shown improved outcomes in ALP poisoning (12). High-risk cases include older patients, patients with delayed admission or delayed initial treatment, and patients with abnormal vital signs or electrolyte levels at presentation; accordingly, they should be closely monitored. In addition, shock and mental status changes were prognostic factors in patients (18).

The idea of using digoxin in the treatment of acute heart failure due to phosphide poisoning was first introduced by Sanaei-Zadeh and Farajidana (19) in 2011, when the first report of the positive effects of digoxin on acute heart failure due to phosphide poisoning was published by Mehrpour and colleagues (7). In the present case, treatment with digoxin in combination with other supportive therapies led to improved heart function, which was also



**Figure 1.** The Patient's Electrocardiography (Tachycardia Attacks in Form of Atrial Fibrillation in a Patient with Simultaneous ALP and ZnP Poisoning at Shahid Beheshti Hospital)

approved by echocardiography. In a study by Gupta, patients who survived ALP poisoning regained normal cardiac functioning on echocardiography on the fifth day (20). In our study, the patient's heart rhythm became sinusoidal on the second day after the onset of digoxin treatment (fourth day of hospitalization). Evidence of normal echocardiography was reported on the fourth day after the onset of digoxin treatment (sixth day of hospitalization).

Considering the negative effects of hyperglycemia and hypoinsulinemia on the prognosis of poisoning with phosphide compounds and the positive effects of insulin therapy in form of different regimens (21), we initiated insulin therapy from the first day of hospitalization up to the final day (with accurate control of blood glucose to avoid possible hypoglycemic complications) to contribute to the recovery process. In a recent prospective interventional study, the glucose/insulin/potassium protocol produced better outcomes in ALP poisoning and increased the length of hospital stay (22).

A notable point of the present case was liver damage in form of elevated liver enzymes. Our patient showed some evidence of acute liver failure, which was controlled by supportive therapies as previously mentioned. Hepatotoxicity as a result of poisoning with ALP (more prevalent in ZnP poisoning) has been previously reported. It has been also revealed that ALP poisoning can cause histopathological changes in the human liver, mostly as central venous congestion, degeneration of hepatocytes, and mononuclear infiltration (23).

Blood lactate level is another factor, which is generally considered in the diagnosis and management of patients with signs and symptoms of sepsis or shock, and is recognized as a sign of tissue hypoperfusion. It has been also studied as a prognostic factor in drug and chemical poisoning. The latest studies have indicated that ALP-poisoned patients generally have higher levels of blood lactate within the first hours post-ingestion; therefore, this factor could be a prognostic marker in the evaluation of acute ALP poi-

soning, particularly within 8 to 16 hours post-ingestion (24). In our case, the lactate level was high ( $> 15$  mmol/L), which gradually decreased until the fifth day of admission (1.3 mmol/L).

It has been reported that ZnP can lead to acute liver failure. Under certain circumstances, where standard supportive treatment is not successful and the patient suffers from an irreversible acute liver failure, liver transplantation is the only approach which can save the patient's life. In addition, several studies have shown that the levels of aspartate aminotransferase and alanine aminotransferase, as important liver enzymes, can increase in case of ZnP poisoning. It should be noted that NAC can be used for the treatment of poisoning, especially hepatotoxicity, owing to the mechanisms which can preserve multiple organ functions and decrease liver enzymes. It can be also used to treat hyperbilirubinemia from encephalopathy due to hepatotoxicity.

In addition, it has been revealed that NAC prevents organ toxicities, such as hepatotoxicity by acting as a glutathione precursor or glutathione restorer. It can change into cysteine or mercaptate conjugates in acetaminophen (N-acetyl-p-benzoquinone imine) or poisoning due to mercury consumption. Therefore, many poisoned patients, who are treated with NAC, do not show hepatotoxicity and are only hospitalized for a short period (6, 16).

Based on the findings of the present study, NAC can be an appropriate antidote for the treatment of patients with ZnP poisoning, which protects them against electrolyte defects or even death. NAC and other antioxidants are effective in the treatment of ALP poisoning, inducing cardiovascular toxicity (25). However, few studies have reported the positive effects of NAC on hepatotoxicity from ZnP poisoning. The present study confirmed the effectiveness of this treatment for phosphide poisoning. In addition, because of the antioxidant effects of NAC, it can be considered a valuable option for ALP and ZnP poisoning.

### 3.1. Conclusions

This case report demonstrated the possible positive effects of digoxin therapy on acute heart failure, as well as the positive effects of insulin therapy on simultaneous poisoning with ALP and ZnP. Application of NAC can have positive effects on the treatment of ALP and ZnP poisoning. The current study had certain limitations, including our inability to generalize the findings or establish a cause-effect relationship. Further research is required to investigate the protective mechanisms of these treatments in metal phosphide-induced poisoning.

### Acknowledgments

We express our deepest gratitude to the respected personnel of the intensive care unit of Shahid Beheshti hospital.

### Footnotes

**Authors' Contribution:** All authors contributed equally to the manuscript.

**Conflict of Interests:** It was not declared by the authors.

**Financial Disclosure:** There is no financial disclosure.

**Funding/Support:** None.

### References

- Dawson AH, Eddleston M, Senarathna L, Mohamed F, Gawaramana I, Bowe SJ, et al. Acute human lethal toxicity of agricultural pesticides: a prospective cohort study. *PLoS Med.* 2010;7(10):e1000357. doi: [10.1371/journal.pmed.1000357](https://doi.org/10.1371/journal.pmed.1000357). [PubMed: 21048990].
- Bumbrah GS, Krishan K, Kanchan T, Sharma M, Sodhi GS. Phosphide poisoning: a review of literature. *Forensic Sci Int.* 2012;214(1-3):1-6. doi: [10.1016/j.forsciint.2011.06.018](https://doi.org/10.1016/j.forsciint.2011.06.018). [PubMed: 21763089].
- Mehrpour O, Aghabiklooei A, Abdollahi M, Singh S. Severe hypoglycemia following acute aluminum phosphide (rice tablet) poisoning; a case report and review of the literature. *Acta Med Iran.* 2012;50(8):568-71. [PubMed: 23109032].
- Mehrpour O, Abdollahi M. Poison treatment centers in Iran. *Hum Exp Toxicol.* 2012;31(3):303-4. doi: [10.1177/0960327110392086](https://doi.org/10.1177/0960327110392086). [PubMed: 21138986].
- Oghabian Z, Mehrpour O. Treatment of Aluminium Phosphide Poisoning with a Combination of Intravenous Glucagon, Digoxin and Antioxidant Agents. *Sultan Qaboos Univ Med J.* 2016;16(3):e352-5. doi: [10.18295/squmj.2016.16.03.015](https://doi.org/10.18295/squmj.2016.16.03.015). [PubMed: 27606117].
- Oghabian Z, Afshar A, Rahimi HR. Hepatotoxicity due to zinc phosphide poisoning in two patients: role of N-acetylcysteine. *Clin Case Rep.* 2016;4(8):768-72. doi: [10.1002/ccr3.618](https://doi.org/10.1002/ccr3.618). [PubMed: 27525081].
- Abdollahi M, Mehrpour O, Farzaneh E. Successful Treatment of Aluminum Phosphide Poisoning with Digoxin: A Case Report and Review of Literature. *Intl J Pharmacol.* 2011;7(7):761-4. doi: [10.3923/ijp.2011.761.764](https://doi.org/10.3923/ijp.2011.761.764).
- Gurjar M, Baronia AK, Azim A, Sharma K. Managing aluminum phosphide poisonings. *J Emerg Trauma Shock.* 2011;4(3):378-84. doi: [10.4103/0974-2700.83868](https://doi.org/10.4103/0974-2700.83868). [PubMed: 21887030].
- Mehrpour O, Alfred S, Shadnia S, Keyler DE, Soltaninejad K, Chalaki N, et al. Hyperglycemia in acute aluminum phosphide poisoning as a potential prognostic factor. *Hum Exp Toxicol.* 2008;27(7):591-5. doi: [10.1177/0960327108096382](https://doi.org/10.1177/0960327108096382). [PubMed: 18829736].
- Soltaninejad K, Beyranvand MR, Momenzadeh SA, Shadnia S. Electrocardiographic findings and cardiac manifestations in acute aluminum phosphide poisoning. *J Forensic Leg Med.* 2012;19(5):291-3. doi: [10.1016/j.jflm.2012.02.005](https://doi.org/10.1016/j.jflm.2012.02.005). [PubMed: 22687771].
- Yildiz M, Kocabay G, Ozkan M. Aluminium-induced ventricular tachycardia. *Am J Emerg Med.* 2012;30(1):262 e1-2. doi: [10.1016/j.ajem.2010.11.012](https://doi.org/10.1016/j.ajem.2010.11.012). [PubMed: 21185676].
- Bashardoust B, Farzaneh E, Habibzadeh A, Seyyed Sadeghi MS. Successful treatment of severe metabolic acidosis due to acute aluminum phosphide poisoning with peritoneal dialysis: a report of 2 cases. *Iran J Kidney Dis.* 2017;11(2):165-7. [PubMed: 28270650].

13. Mehrpour O, Amouzesi A, Dadpour B, Oghabian Z, Zamani N, Amini S, et al. Successful treatment of cardiogenic shock with an intraaortic balloon pump following aluminium phosphide poisoning. *Arh Hig Rada Toksikol.* 2014;**65**(1):121-6. doi: [10.2478/10004-1254-65-2014-2393](https://doi.org/10.2478/10004-1254-65-2014-2393). [PubMed: [24445229](https://pubmed.ncbi.nlm.nih.gov/24445229/)].
14. Nakhaee S, Mehrpour O, Balali-Mood M. Does N-acetyl cysteine have protective effects in acute aluminum phosphide poisoning? *Indian J Crit Care Med.* 2017;**21**(8):539-40. doi: [10.4103/ijccm.IJCCM\\_223\\_17](https://doi.org/10.4103/ijccm.IJCCM_223_17). [PubMed: [28904489](https://pubmed.ncbi.nlm.nih.gov/28904489/)].
15. Dogan E, Guzel A, Ciftci T, Aycan I, Celik F, Cetin B, et al. Zinc phosphide poisoning. *Case Rep Crit Care.* 2014;**2014**:589712. doi: [10.1155/2014/589712](https://doi.org/10.1155/2014/589712). [PubMed: [25101186](https://pubmed.ncbi.nlm.nih.gov/25101186/)].
16. Saraf V, Pande S, Gopalakrishnan U, Balakrishnan D, Menon RN, Sudheer OV, et al. Acute liver failure due to zinc phosphide containing rodenticide poisoning: Clinical features and prognostic indicators of need for liver transplantation. *Indian J Gastroenterol.* 2015;**34**(4):325-9. doi: [10.1007/s12664-015-0583-2](https://doi.org/10.1007/s12664-015-0583-2). [PubMed: [26310868](https://pubmed.ncbi.nlm.nih.gov/26310868/)].
17. Louriz M, Dendane T, Abidi K, Madani N, Abouqal R, Zeggwagh AA. Prognostic factors of acute aluminum phosphide poisoning. *Indian J Med Sci.* 2009;**63**(6):227-34. doi: [10.4103/0019-5359.53386](https://doi.org/10.4103/0019-5359.53386). [PubMed: [19602756](https://pubmed.ncbi.nlm.nih.gov/19602756/)].
18. Trakulsrichai S, Kosanyawat N, Atiksawedparit P, Sriapha C, Tongpoo A, Udomsubpayakul U, et al. Clinical characteristics of zinc phosphide poisoning in Thailand. *Ther Clin Risk Manag.* 2017;**13**:335-40. doi: [10.2147/TCRM.S129610](https://doi.org/10.2147/TCRM.S129610). [PubMed: [28352183](https://pubmed.ncbi.nlm.nih.gov/28352183/)].
19. Sanaei-Zadeh H, Farajidana H. Is there a role for digoxin in the management of acute aluminum phosphide poisoning? *Med Hypotheses.* 2011;**76**(5):765-6. doi: [10.1016/j.mehy.2011.02.023](https://doi.org/10.1016/j.mehy.2011.02.023). [PubMed: [21388748](https://pubmed.ncbi.nlm.nih.gov/21388748/)].
20. Gupta MS, Malik A, Sharma VK. Cardiovascular manifestations in aluminium phosphide poisoning with special reference to echocardiographic changes. *J Assoc Physicians India.* 1995;**43**(11):773-4. 779-80. [PubMed: [8773039](https://pubmed.ncbi.nlm.nih.gov/8773039/)].
21. Mehrpour O, Abdollahi M, Sharifi MD. Oxidative stress and hyperglycemia in aluminum phosphide poisoning. *J Res Med Sci.* 2014;**19**(2).
22. Hassanian-Moghaddam H, Zamani N. Therapeutic role of hyperinsulinemia/euglycemia in aluminum phosphide poisoning. *Medicine (Baltimore).* 2016;**95**(31). e4349. doi: [10.1097/MD.0000000000004349](https://doi.org/10.1097/MD.0000000000004349). [PubMed: [27495040](https://pubmed.ncbi.nlm.nih.gov/27495040/)].
23. Mehrpour O, Dolati M, Soltaninejad K, Shadnia S, Nazparvar B. Evaluation of histopathological changes in fatal aluminum phosphide poisoning. *Indian J Forensic Med Toxicol.* 2008;**2**(2):34-6.
24. Erfantalab P, Soltaninejad K, Shadnia S, Zamani N, Hassanian-Moghaddam H, Mahdavinnejad A, et al. Trend of blood lactate level in acute aluminum phosphide poisoning. *World J Emerg Med.* 2017;**8**(2):116-20. doi: [10.5847/wjem.j.1920-8642.2017.02.006](https://doi.org/10.5847/wjem.j.1920-8642.2017.02.006). [PubMed: [28458755](https://pubmed.ncbi.nlm.nih.gov/28458755/)].
25. Taghaddosinejad F, Farzaneh E, Ghazanfari-Nasrabad M, Eizadi-Mood N, Hajhosseini M, Mehrpour O. The effect of N-acetyl cysteine (NAC) on aluminum phosphide poisoning inducing cardiovascular toxicity: a case-control study. *Springerplus.* 2016;**5**(1):1948. doi: [10.1186/s40064-016-3630-2](https://doi.org/10.1186/s40064-016-3630-2). [PubMed: [27917341](https://pubmed.ncbi.nlm.nih.gov/27917341/)].