



# One-Year Follow-Up of Vitiligo Patients Treated with Autologous Non-Cultured Melanocytes

Atefeh Shahbazi<sup>1,2,3</sup>, Mohammad Hasan Naseh<sup>3,4</sup>, Masoud Habibi<sup>5</sup>, Reza Shirazi<sup>6</sup>, Hamid Choobineh<sup>7,\*</sup> and Seyed Mohammad Akrami<sup>3,8,\*\*</sup>

<sup>1</sup>Department of Regenerative Medicine, Cell Science Research Center, Royan Institute for Stem Cell Biology and Technology, ACECR, Tehran, Iran

<sup>2</sup>Department of Cellular and Molecular Biology, School of Biology, College of Science, University of Tehran, Tehran, Iran.

<sup>3</sup>Helal Iran Pharmaceutical and Clinical Complex, Tehran, Iran

<sup>4</sup>Behroooyan Clinic of Dermatology, Tehran, Iran

<sup>5</sup>Department of Genetics, Breast Cancer Research Center, Motamed Cancer Institute (ACECR), Tehran, Iran

<sup>6</sup>Department of Anatomical Sciences, Faculty of Medicine, Iran University of Medical Sciences, Tehran, Iran

<sup>7</sup>Department of Medical Laboratory Sciences, School of Allied Medical Sciences, Tehran University of Medical Sciences, Tehran, Iran

<sup>8</sup>Department of Medical Genetics, School of Medicine, Tehran University of Medical Sciences, Tehran, Iran

\*Corresponding author: Department of Medical Laboratory Sciences, School of Allied Medical Sciences, Tehran University of Medical Sciences, P.O. Box: 1417933331, Tehran, Iran. Tel: +98-217734 9364, Fax: +98-217779 3131, Email: hchoobineh@tums.ac.ir

\*\*Corresponding author: Associate Professor, Medical Genetics Department, Poursina St., Tehran University of Medical Sciences, Postal Code: 14176-13151, Tehran, Iran. Tel/Fax: +98-2188953005, Email: akramism@tums.ac.ir

Received 2018 July 11; Revised 2019 October 06; Accepted 2019 October 08.

## Abstract

**Background:** Vitiligo is a long-term multifactorial polygenic disorder, characterized by the patchy loss of pigments in the skin. Several treatments including therapeutic creams and oral drugs are used to treat vitiligo with varying degrees of success. Some medical treatments can reduce the severity of the disease, but it is difficult to cure the disorder. Autologous non-cultured melanocyte transplantation is an effective method of vitiligo treatment. The utilization of appropriate cell suspension is a safe and efficient strategy to cure such hypopigmentation disorder.

**Objectives:** The aim of this study was to follow up patients suffering from generalized and stable vitiligo who were treated with transplanted cells. Patients with patches in four different parts (forehead, eyelids, trunks, and hands) were selected because skin thickness varied among different body parts. We compared melanin repigmentation in these areas.

**Methods:** We recruited 39 patients with generalized and stable vitiligo who had patches on their forehead, eyelids, trunks, and hands. Partial grafts were taken from the gluteal regions of all patients. Epidermal cells including non-cultured melanocyte and keratinocyte suspensions were enzymatically isolated and found to be of > 98% viability. Cells were injected intraepidernally. After a 12-month follow-up, repigmentation was observed.

**Results:** The mean repigmentation score continued to improve up to 12 months post-transplantation. The obtained results confirmed that the cellular suspension that consisted of a mixture of epidermal cells improved to restore the normal color of the repigmentation rate. The number of received cells per cm<sup>2</sup> positively influenced the repigmentation score. Patches located on the face, neck, and trunk areas showed significantly higher responses to treatment. The pigmentation score was classified as “poor” (1% - 25%), “moderate” (26% - 50%), and “good” (51% - 75%). This study is a research and clinical study with a brief report registered with the Ethics Committee of Avicenna Research Institute, clinical trials (letter number: 93/22/01/89), Tehran, Iran.

**Conclusions:** The application of autologous non-cultured melanocyte-keratinocyte cell suspension could restore the patchy skin color to a near-normal level and the majority of the patients were satisfied with the results.

**Keywords:** Cell Therapy, Melanocyte, Vitiligo

## 1. Background

Vitiligo is a common acquired disorder of pigmentation characterized by the development of well-defined white patches on the skin. Biopsies of skin layers reveal the loss of epidermal melanocytes (1, 2). Melanocytes are specialized pigmented cells responsible for producing skin

pigments. The epidermal melanocytes work together with neighboring keratinocytes.

Melanocytes are specialized cells that are distributed in the skin, other epithelial surfaces, and eyes. Vitiligo is a relatively common pigmentation disorder in which the skin's melanocytes are lost or destroyed. Vitiligo affects 0.1% - 2.0 % of the world population. The Qual-

ity of Life (QOL) in patients affected by vitiligo declines severely and depression increases in these patients (3). In recent years, various treatments such as immunosuppressive drugs, topical agents, and light-based and surgical therapies are increasingly applied to patients suffering from vitiligo for the restoration of damaged skin (4). Despite all progresses made in therapeutic approaches, several disadvantages, including high recurrence, inadequate pigment covering, and patient unsatisfactory, are reported (5). Significant advances in regenerative medicine and cell therapy have introduced melanocyte transplantation as a promising replacement for damaged cells (6). Although both cultured and non-cultured melanocytes are applied to restore pigmentation, in the case of small depigmented patches, autologous non-cultured melanocyte-keratinocyte transplantation may produce better results than cultured melanocyte suspension (7). Melanocytes are the pigmented cells of the skin's basal layer. Keratinocyte growth factor has shown to regulate the proliferation of melanocytes (8). In the last decade, stem cell therapy has gained greater attention than other treatments due to its positive results (6). Stem cell therapy can cure different skin diseases, and replace drugs, cosmetic agents, and other impermanent treatments. However, promising results prompted researchers to extend the newest treatment with less risky techniques (9). Thus, cell-based therapeutics are regarded as suitable substitutes for other expensive and time-consuming methods (10) for treating vitiligo patients. In this study, we report the results of a one-year follow-up of repigmentation using autologous non-cultured melanocyte/keratinocyte transplantation in 39 vitiligo patients. All the patients had used other treatments like Ultraviolet (UV), light therapy, topical corticosteroids, and various cosmetic creams. Patients with stable disease and generalized patterns, who had patches in their faces, trunks, and hands, were enrolled. After the selection of patients, isolated epidermal cells with > 95% viability were injected intraepidernally. One year later, the patch sizes were recorded and photos were taken; also, patient satisfaction, repigmentation area, and physician idea were recorded.

## 2. Methods

### 2.1. Patients' Selection

In total, we selected 39 patients (24 males and 15 females) who had undergone transplantation for vitiligo and had not received other treatments for their disease during the last six months. Before cell therapy, all patients received topical mometasone furoate cream, course of narrowband UV-B irradiation, and wood light examination;


however, no repigmentation occurred. The age of the patients ranged from 20 to 48 years with an average of 34.33. Stable vitiligo was defined as the UN appearance of new lesions or the increased size of the existing lesions over the last six months. Patients who had extensive depigmented patches, suffered from serious systemic disease, had keloid tendencies, and lactating/pregnant women were excluded from the present study. The most critical diagnostic laboratory tests were also done before any procedure, including Fasting Blood Sugar (FBS), thyroids hormones (T3, and T4, anti-TPO: Anti Thyroid Peroxidase), and Laboratory tests for viral infections like Human Immunodeficiency Virus (HIV), Hepatitis C Virus (HCV), and Hepatitis B Surface Antigen (HBsAg). All patients agreed with the study and signed informed consent forms at Helal Iran Pharmaceutical and Medical Complex (Tehran, Iran). All related documents were kept at the dermatology clinic. The Ethics Committee of the Breast Cancer Research Center, Motamed Cancer Institute (ACECR), Tehran, Iran. Checked the patient's selection process and informed consent at Helal Iran Pharmaceutical and Clinical Complex and approved the study as a clinical trial of the second phase. This study is a research and clinical study with a brief report registered with the Ethics Committee of Avicenna Research Institute, Clinical Trials (letter number: 93/22/01/89), Tehran, Iran.

### 2.2. Cell Suspension Preparation

Transplantation of autologous non-cultured epidermal cells was done. Depending on the size of the vitiligo macule, an ultrathin skin biopsy (measuring about  $2 \times 5$  cm<sup>2</sup>) was harvested using a dermatome from the patient's pigmented gluteal region under local epidermal anesthesia. The donor tissue was immediately transferred to 10 mL of Hanks Black Solution Solvent (HBSS) buffer (Sigma Chemicals, St. Louis, Mo, USA). The isolation of epidermal cells was performed as previously described (1, 11). Cell viability was checked by the dye trypan blue and cells were simultaneously counted using a Neuberg's chamber under a light microscope; this would also identify whether the cells were viable as the dead ones stained blue. At the density of around 250 - 450 cells/cm<sup>2</sup>, cells of the recipient area were obtained depending on the depigmented area where cells would be transplanted on (Figure 1).

### 2.3. Transplantation Procedure

Before transplantation, the recipient site was cleaned, treated with betadine and ethanol 70%, and washed thoroughly with normal saline. Subsequently, the melanocyte/keratinocyte suspension was transplanted intraepidernally by an expert dermatologist. Following injection, the patients were allowed to take a short rest



**Figure 1.** The process of cell isolation from the epidermis (first A to end J). 1, The subcutaneous tissue and dermis were removed; 2, the remaining skin was cut into small sections (0.5 mm thick); 3, they were placed in 0.25% neutral Dispase overnight at 4°C to obtain the epidermis; 4, 5, and 6, dermis was removed from epidermis; 6 and 7, immersed in a solution trypsin/EDTA at 37°C for 5 min; this digestion was terminated by the addition of the serum; 8, single cell suspensions were obtained by pipette blowing, filtered through a 200 mesh filter for screening and centrifuged twice at 1,500 rpm for 6 min; 9, cell morphology was observed using inverted microscope.

and leave. Patients who were not provided with any additional therapy during the six-month follow-up period were visited to evaluate the process of therapy. To this, repigmentation was checked and recorded by photography to compare with the baseline photographs at their first follow-up; patients were visited after six months for the evaluation of the process of therapy. The next follow-up was done after 12 months. The dermatologist assessed the repigmentation of the treated patches by measuring the patch surface area before cell transplantation and then

estimating the approximate range of the repigmentation percentage at each follow-up visit. Patients also estimated the approximate range of repigmentation percentage at each follow-up visit. Both dermatologists and patients used a scoring system that consisted of I (1% - 25%), II (25% - 55%), and III (55% - 85%) scores to represent their estimation of repigmentation percentage. However, the curing process was not very obvious in the hand region (about 25%). An overall evaluation of the effect in each of the 39 patients showed the following results after 12 months:

good (85%), moderate (55%), and poor (25%). We evaluated the long-term permanence of the achieved repigmentation and effective factors on achieved repigmentation, in addition to short- and long-term adverse events of the cell transplantation procedure as secondary endpoints (Figure 2).

#### 2.4. Statistical Analysis

Statistical calculations were performed by R (version 3.2.4) and SPSS (version 16.0). We used the binomial test to assess differences between proportions. According to the correlation between observations, the multilevel analysis was used to evaluate the effects of covariates on the response variables. A P value of less than 0.05 was considered statistically significant.

### 3. Results

In this study, 39 hypo-pigmented patients with generalized stable vitiligo were treated with epidermal cell suspensions using an intra-epidermal transplantation method in four separate areas of forehead, eyelid, trunk, and hand. In the present study, the patients' age ranged from 20 to 48 years (with an average of 34.33). The patients' condition was stable for more than six months. All of the patients were asked about concomitant disorders; only one of them suffered from hypothyroidism and 23 patients had vitiligo in their family histories (Table 1).

Table 1. Patients' Information

Parameters	Values
Total patient number	39
Age, y	20 - 48
Gender	
Female	15
Male	24
Previous treatment	39
Family history	16
Specific disease	1
Transplantation area	
Forehead	41.92
Eyelid	43.46
Neck	40.38
Hand	28.85
Final result	50.56
P value	0.01

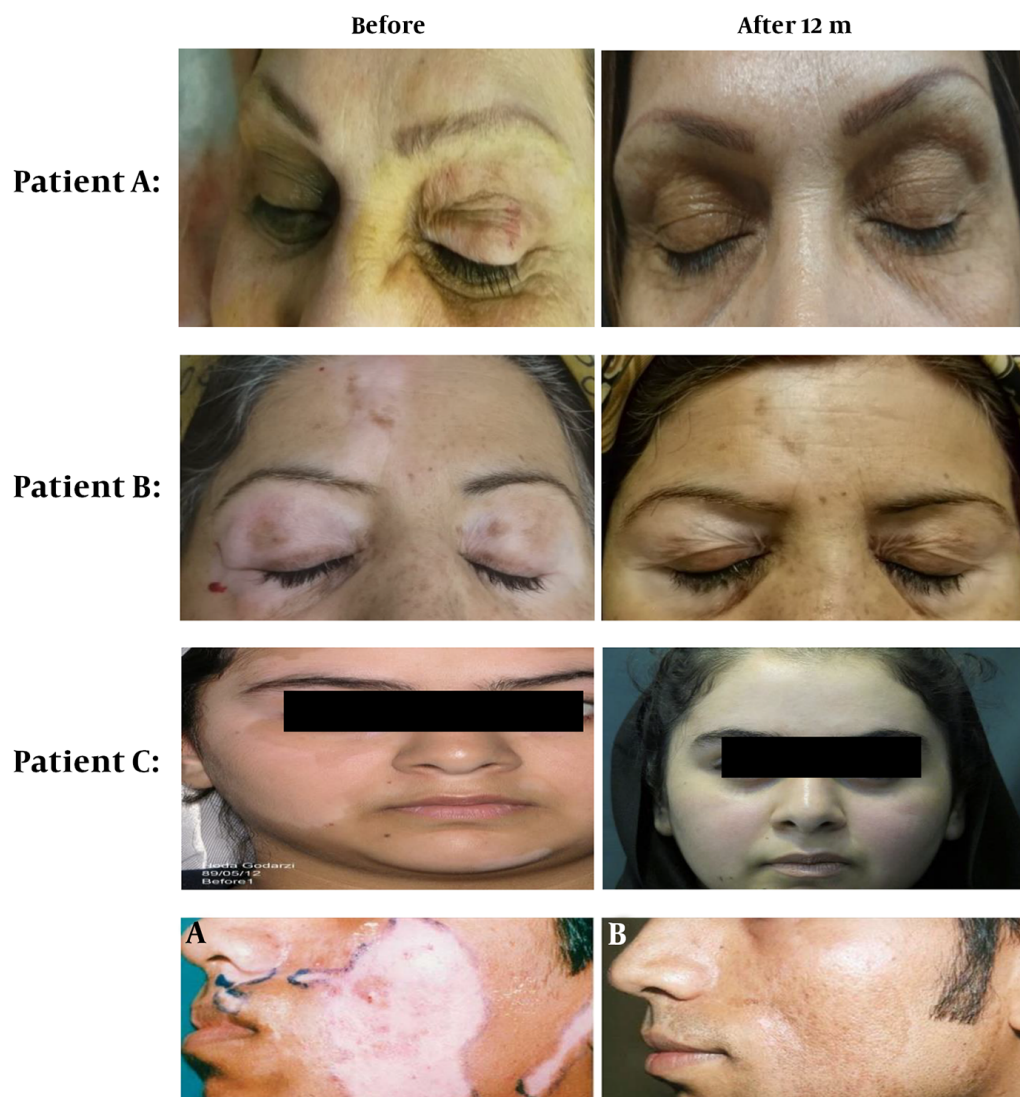The vitiligo areas did not involve more than 10% of the patients' skin. At a one-year follow-up, we observed > 50% repigmentation in the face and trunk. In the dorsal parts of the proximal and distal phalanges of fingers and hands, the pigmentation was often graded as fair or poor, especially over the hand joints. Patients that received the cell suspension on their trunk showed two different results. Two fair results on the trunk were obtained in two patients and one patient generally showed a good to excellent result, which made it possible for her to be exposed to the sun without burning. Hyperpigmentation was also seen especially on the forehead and eyelid in those who displayed white patches. When examined after 14 months, the color was the same as that of the surrounding skin (Figure 3). The results obtained in this study displayed the following repigmentation rates in four different areas: 40.39% in the forehead, 43.46% in the eyelid, 41.92% in the neck, and 28.85% in hands. The highest satisfactory and repigmentation rates were 50.56% for both parameters. The average number of cells was  $9 \times 10^6$  with 98% viability and the volume of cell suspension was 3.5 mL (Figure 4).

### 4. Discussion

Most previous studies showed the feasibility and safety of intraepidermal injection of non-cultured melanocyte-keratinocyte as an effective treatment in vitiligo patients (12). Due to low cost, greater tolerability for patients, higher feasibility to perform on curved surfaces, and lacking risk of scarring or Koebner phenomenon in the recipient sites, this approach is regarded as a suitable method of treatment (13, 14). This study aimed to evaluate the long-term efficacy of a new therapeutic approach in patients with stable vitiligo by transplantation of non-cultured melanocyte in four areas of the body (i.e. forehead, eyelid, neck, and hand (7)).

In this study, we decided to check repigmentation in four areas with varying degrees of skin thickness. This report also evaluated the long-term efficacy of cell therapy in vitiligo patients suffering from generalized vitiligo. Our results demonstrated long-lasting repigmentation of vitiligo patches in most of the patients following the injection of epidermal cell suspension. We did not use any stimulant agents during the study, which enabled us to check the pure effect of cell transplantation on white patches. However, cellular therapy combined with light-based therapies might enhance the achieved repigmentation (15). The results obtained in the present study showed significantly higher repigmentation in patches located on the face, especially eyelid and forehead. Our report also supported the findings of the majority of previous studies that reported a good response of patches in the face but the





**Figure 2.** Repigmentation in four patients after 12 months

resistance of hand patches to other treatment modalities such as surgical interventions and drug therapies. Since 30 years ago, studies have demonstrated that cellular-based therapies used for patients with disfiguring vitiligo, either generalized or stable type, can be another option for subjects who do not respond to conventional treatment approaches (16-18).

Transplantation of melanocyte/keratinocyte suspension allows patients to use cellular therapies for different depigmented parts of the body (19). An unaffected part of the body was selected to take a very thin sample of the skin, called "donor site". Patients' samples

were then transferred to the lab to be processed (19, 20). Pigment-producing cells, melanocytes, and surrounding keratinocytes were separated out (21). After cleaning and numbing the selected vitiliginous area, epidermal cell solutions suspended in normal saline were treated with the patient's serum and were injected into the depigmented areas. The transplantation/injection process in the recipient area is simple, superficial, and safe and there is no risk of hypochromic halo, nor a cobblestone appearance or necrosis. Positive results of using this technique and/or repigmentation induced by non-cultured melanocyte were achieved by different authors (22). For ex-

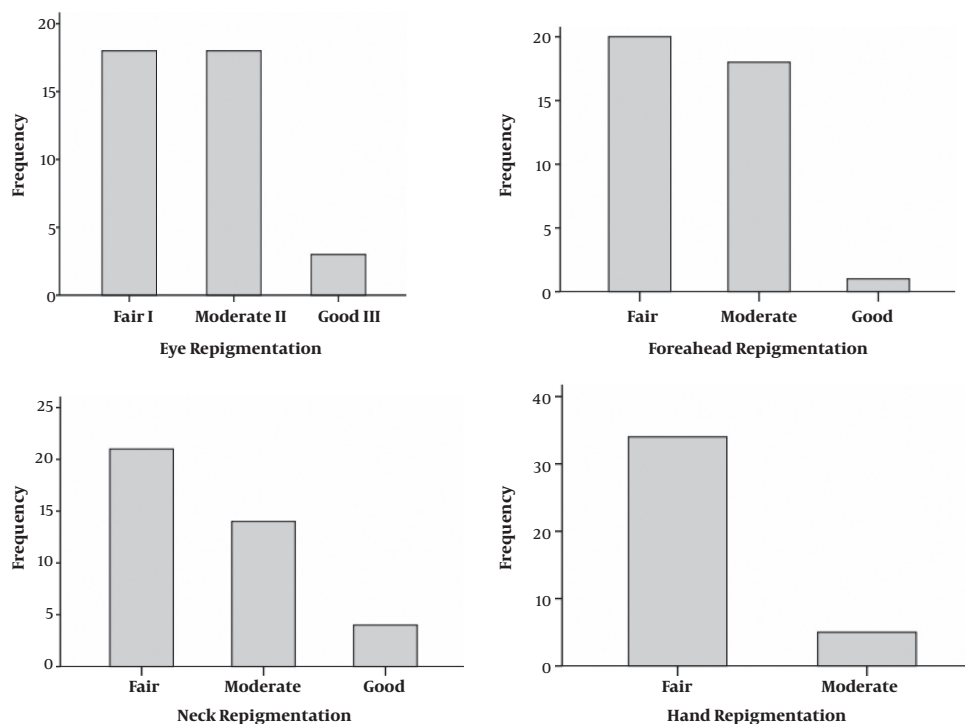


Figure 3. Frequency of repigmentation after applying non-cultured melanocyte in four parts

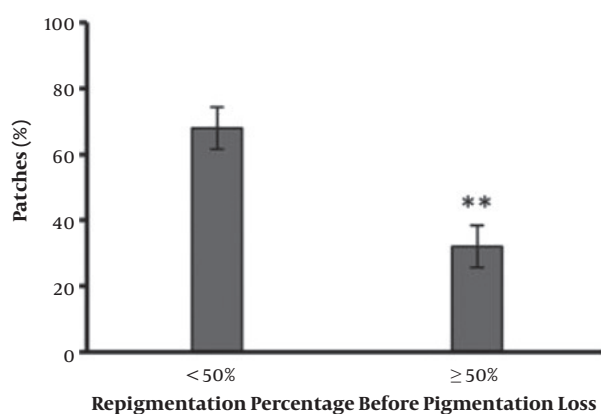


Figure 4. Frequency of repigmentation after applying non-cultured melanocyte in four parts of the body and comparisons among them

ample, Olsson et al. (22) similarly reported 100% repigmentation in three patients with segmental vitiligo and 78% repigmentation in 39 patients with generalized vitiligo. Another report also indicated that the highest repigmentation percentage (95%) was observed in segmental vitiligo patients and the lowest was achieved in generalized vitiligo patients (14). Mulekar et al. examined repigmenta-

tion in patients with segmental and generalized vitiligo and reported that 65% of the patients with segmental vitiligo presented over 90% repigmentation; higher rates of repigmentation were found in patients with segmental vitiligo and lower rates in generalized vitiligo (23). Neves et al. verified progressive repigmentation with 90% improvement in achromatic lesions in the pretibial region after three sessions of melanocyte transplantation using the punch grafting technique (24).

Previous studies indicated that cell transplantation on ablated skin might be a more appropriate therapeutic approach for hand vitiligo patches that usually show a poor response to treatment (25, 26). In the present study, we reported responses in 39 patients aged between 20 and 48 years who had generalized vitiligo with stable and limited patches on forehead, eyelid, neck, and hands. By analyzing the data, we found that > 50% of patients were satisfied with the transplantation outcomes. About 25% of patients achieved poor results. The selection of patients to undergo this procedure should be carefully performed. In our patients, transplantation was carried out without complications before and after surgery. The melanocyte cell suspension transplantation seems to be an important tool for the treatment of vitiligo in patients who do not respond to conventional non-surgical treatments. In most cases,

repigmentation takes place four months after transplantation uniformly and with a similar color to the original skin color. Patients with generalized vitiligo are the ones who would benefit most from this method.

The response to treatment was assessed during regular follow-up visits. The follow-up intervals ranged from 6 to 12 months after a single session of intraepidermal cell transplantation. The primary endpoint was the percentage of repigmentation that was subjectively evaluated by a single dermatologist.

#### 4.1. Conclusions

The application of autologous non-cultured melanocyte-keratinocyte cell suspension could restore patchy skin color to a near-normal level and the majority of the patients were satisfied with the results.

#### Acknowledgments

We are grateful to the staff of the Dermatology Department in Helal Iran Pharmaceutical and Clinical Complex, for their expertise and feedback. We would like to particularly thank the patients and their families for participating in this study.

#### Footnotes

**Authors' Contribution:** Seyed Mohammad Akrami and Mohammad Hasan Naseh conceived and designed the original protocol. All authors were involved in amending the protocol. Atefeh Shahbazi performed cell isolation, culturing process, and in vitro study. Hamid Choobineh and Masoud Habibi were involved in the in vivo experiments. Data entry and analysis were performed by Atefeh Shahbazi and Seyed Mohammad Akrami. Atefeh Shahbazi and Reza Shirazi wrote the first draft of the manuscript. Seyed Mohammad Akrami supervised the study. All authors read and approved the final manuscript.

**Clinical Trial Registration Code:** IRCT201508201031N16.

**Conflict of Interests:** The authors declare no conflict of interest.

**Ethical Approval:** The Ethics Committee of Breast Cancer Research Center, Motamed Cancer Institute (ACECR), Tehran, Iran, checked the patient selection process and informed consent.

**Funding/Support:** This study was funded by a grant from Helal Iran Pharmaceutical and Clinical Complex Tehran, Iran.

**Patient Consent:** All patients agreed and signed the provided informed consent forms at Helal Iran Pharmaceutical and Clinical Complex, Tehran, Iran. All related documents are kept at the dermatology clinic.

#### References

- Orouji Z, Bajouri A, Ghasemi M, Mohammadi P, Fallah N, Shahbazi A, et al. A single-arm open-label clinical trial of autologous epidermal cell transplantation for stable vitiligo: A 30-month follow-up. *J Dermatol Sci*. 2018;**89**(1):52-9. doi: [10.1016/j.jdermsci.2017.10.007](https://doi.org/10.1016/j.jdermsci.2017.10.007). [PubMed: [29103774](https://pubmed.ncbi.nlm.nih.gov/29103774/)].
- Bishnoi A, Parsad D. Clinical and molecular aspects of vitiligo treatments. *Int J Mol Sci*. 2018;**19**(5). doi: [10.3390/ijms19051509](https://doi.org/10.3390/ijms19051509). [PubMed: [29783663](https://pubmed.ncbi.nlm.nih.gov/29783663/)]. [PubMed Central: [PMC5983813](https://pubmed.ncbi.nlm.nih.gov/PMC5983813/)].
- Al-Shobaili HA. Update on the genetics characterization of vitiligo. *Int J Health Sci (Qassim)*. 2011;**5**(2):167-79. [PubMed: [23267294](https://pubmed.ncbi.nlm.nih.gov/23267294/)]. [PubMed Central: [PMC3521835](https://pubmed.ncbi.nlm.nih.gov/PMC3521835/)].
- Taieb A, Alomar A, Bohm M, Dell'anna ML, De Pase A, Eleftheriadou V, et al. Guidelines for the management of vitiligo: The European Dermatology Forum consensus. *Br J Dermatol*. 2013;**168**(1):5-19. doi: [10.1111/j.1365-2133.2012.11197.x](https://doi.org/10.1111/j.1365-2133.2012.11197.x). [PubMed: [22860621](https://pubmed.ncbi.nlm.nih.gov/22860621/)].
- Ramos MG, Ramos DG, Gontijo G, Ramos CG, Rocha TN, Rocha RH. Non-cultured melanocyte/keratinocyte transplantation for the treatment of stable vitiligo on the face: Report of two cases. *An Bras Dermatol*. 2013;**88**(5):811-3. doi: [10.1590/abd1806-4841.20132054](https://doi.org/10.1590/abd1806-4841.20132054). [PubMed: [24173191](https://pubmed.ncbi.nlm.nih.gov/24173191/)]. [PubMed Central: [PMC3798362](https://pubmed.ncbi.nlm.nih.gov/PMC3798362/)].
- Shahbazi A, Safa M, Alikarami F, Kargozar S, Asadi MH, Joghataei MT, et al. Rapid induction of neural differentiation in human umbilical cord matrix mesenchymal stem cells by camp-elevating agents. *Int J Mol Cell Med*. 2016;**5**(3):167-77. [PubMed: [27942503](https://pubmed.ncbi.nlm.nih.gov/27942503/)]. [PubMed Central: [PMC5125369](https://pubmed.ncbi.nlm.nih.gov/PMC5125369/)].
- Mulekar SV. Long-term follow-up study of 142 patients with vitiligo vulgaris treated by autologous, non-cultured melanocyte-keratinocyte cell transplantation. *Int J Dermatol*. 2005;**44**(10):841-5. doi: [10.1111/j.1365-4632.2005.02226.x](https://doi.org/10.1111/j.1365-4632.2005.02226.x). [PubMed: [16207186](https://pubmed.ncbi.nlm.nih.gov/16207186/)].
- Wassef C, Lombardi A, Khokher S, Rao BK. Vitiligo surgical, laser, and alternative therapies: A review and case series. *J Drugs Dermatol*. 2013;**12**(6):685-91. [PubMed: [23839187](https://pubmed.ncbi.nlm.nih.gov/23839187/)].
- Stromberg S, Bjorklund MG, Asplund A, Rimini R, Lundeborg J, Nilsson P, et al. Transcriptional profiling of melanocytes from patients with vitiligo vulgaris. *Pigment Cell Melanoma Res*. 2008;**21**(2):162-71. doi: [10.1111/j.1755-148X.2007.00429.x](https://doi.org/10.1111/j.1755-148X.2007.00429.x). [PubMed: [18426409](https://pubmed.ncbi.nlm.nih.gov/18426409/)].
- Arora T, Mehta AK, Joshi V, Mehta KD, Rathor N, Mediratta PK, et al. Substitute of animals in drug research: An approach towards fulfillment of 4R's. *Indian J Pharm Sci*. 2011;**73**(1):1-6. doi: [10.4103/0250-474X.89750](https://doi.org/10.4103/0250-474X.89750). [PubMed: [22131615](https://pubmed.ncbi.nlm.nih.gov/22131615/)]. [PubMed Central: [PMC3224398](https://pubmed.ncbi.nlm.nih.gov/PMC3224398/)].
- Khodadadi L, Shafieyan S, Sotoudeh M, Dizaj AV, Shahverdi A, Aghdami N, et al. Intraepidermal injection of dissociated epidermal cell suspension improves vitiligo. *Arch Dermatol Res*. 2010;**302**(8):593-9. doi: [10.1007/s00403-010-1034-7](https://doi.org/10.1007/s00403-010-1034-7). [PubMed: [20364383](https://pubmed.ncbi.nlm.nih.gov/20364383/)].
- Huggins RH, Henderson MD, Mulekar SV, Ozog DM, Kerr HA, Jabobson G, et al. Melanocyte-keratinocyte transplantation procedure in the treatment of vitiligo: The experience of an academic medical center in the United States. *J Am Acad Dermatol*. 2012;**66**(5):785-93. doi: [10.1016/j.jaad.2011.05.002](https://doi.org/10.1016/j.jaad.2011.05.002). [PubMed: [21864935](https://pubmed.ncbi.nlm.nih.gov/21864935/)].
- Mulekar SV. Long-term follow-up study of segmental and focal vitiligo treated by autologous, noncultured melanocyte-keratinocyte cell transplantation. *Arch Dermatol*. 2004;**140**(10):1211-5. doi: [10.1001/archderm.140.10.1211](https://doi.org/10.1001/archderm.140.10.1211). [PubMed: [15492183](https://pubmed.ncbi.nlm.nih.gov/15492183/)].
- Mulekar SV, Al Issa A, Al Eisa A, Asaad M. Genital vitiligo treated by autologous, noncultured melanocyte-keratinocyte cell transplantation. *Dermatol Surg*. 2005;**31**(12):1737-9. discussion 1740. doi: [10.2310/6350.2005.31324](https://doi.org/10.2310/6350.2005.31324). [PubMed: [16336903](https://pubmed.ncbi.nlm.nih.gov/16336903/)].

15. Barolet D. Dual effect of photobiomodulation on melasma: Downregulation of hyperpigmentation and enhanced solar resistance-a pilot study. *J Clin Aesthet Dermatol*. 2018;**11**(4):28-34. [PubMed: 29657669]. [PubMed Central: PMC5891084].
16. Yu RX, Hui Y, Li CR. Koebner phenomenon induced by striae distensae in a vitiligo patient. *Ann Dermatol*. 2017;**29**(5):633-4. doi: 10.5021/ad.2017.29.5.633. [PubMed: 28966524]. [PubMed Central: PMC5597661].
17. Mou KH, Han D, Liu WL, Li P. Combination therapy of orally administered glycyrrhizin and UVB improved active-stage generalized vitiligo. *Braz J Med Biol Res*. 2016;**49**(8). doi: 10.1590/1414-431X20165354. [PubMed: 27464024]. [PubMed Central: PMC4964896].
18. Young PP, Schafer R. Cell-based therapies for cardiac disease: A cellular therapist's perspective. *Transfusion*. 2015;**55**(2):441-51. quiz 440. doi: 10.1111/trf.12826. [PubMed: 25145464]. [PubMed Central: PMC5771653].
19. Mulekar SV, Ghwish B, Al Issa A, Al Eisa A. Treatment of vitiligo lesions by ReCell vs. conventional melanocyte-keratinocyte transplantation: A pilot study. *Br J Dermatol*. 2008;**158**(1):45-9. doi: 10.1111/j.1365-2133.2007.08216.x. [PubMed: 17927795].
20. Cichorek M, Wachulska M, Stasiewicz A, Tyminska A. Skin melanocytes: Biology and development. *Postepy Dermatol Alergol*. 2013;**30**(1):30-41. doi: 10.5114/pdia.2013.33376. [PubMed: 24278043]. [PubMed Central: PMC3834696].
21. Van Geel NA, Ongenae K, Vander Haeghen YM, Naeyaert JM. Autologous transplantation techniques for vitiligo: How to evaluate treatment outcome. *Eur J Dermatol*. 2004;**14**(1):46-51. [PubMed: 14965796].
22. Olsson MJ, Juhlin L. Leucoderma treated by transplantation of a basal cell layer enriched suspension. *Br J Dermatol*. 1998;**138**(4):644-8. doi: 10.1046/j.1365-2133.1998.02177.x. [PubMed: 9640371].
23. Mulekar SV. Melanocyte-keratinocyte transplantation procedure: A few insights. *Indian J Dermatol Venereol Leprol*. 2016;**82**(1):13-5. doi: 10.4103/0378-6323.172904. [PubMed: 26728804].
24. Neves DR, Regis Junior JR, Oliveira PJ, Zac RI, Silveira Kde S. Melanocyte transplant in piebaldism: Case report. *An Bras Dermatol*. 2010;**85**(3):384-8. doi: 10.1590/s0365-05962010000300016. [PubMed: 20676476].
25. Vazquez-Martinez OT, Martinez-Rodriguez HG, Velasquez-Arenas L, Banos-Gonzalez D, Ortiz-Lopez R, Padilla-Rivas G, et al. Treatment of vitiligo with a melanocyte-keratinocyte cell suspension versus dermabrasion only: A pilot study with a 12-month follow up. *J Drugs Dermatol*. 2011;**10**(9):1032-6. [PubMed: 22052273].
26. Mulekar SV. Stable vitiligo treated by a combination of low-dose oral pulse betamethasone and autologous, noncultured melanocyte-keratinocyte cell transplantation. *Dermatol Surg*. 2006;**32**(4):536-41. doi: 10.1111/j.1524-4725.2006.32109.x. [PubMed: 16681662].