

## Effects of Echinacea Purpurea on Wound Healing after Arsenic Induced Skin Necrosis

Annahita Rezaie,<sup>\*1</sup> Hossein Najafzadeh,<sup>2</sup> Mahdi Poormahdi-Broojeni,<sup>3</sup> Babak Mohammadian,<sup>1</sup> Marzieh Heidari<sup>4</sup>

1. Department of Pathobiology, Faculty of Veterinary Medicine, Shahid Chamran University, Ahvaz, Iran
2. Department of Basic Sciences, Faculty of Veterinary Medicine, Shahid Chamran University, Ahvaz, Iran
3. Department of Food Hygiene, Faculty of Veterinary Medicine, Shahid Chamran University, Ahvaz, Iran
4. Graduated in Veterinary Medicine, Faculty of Veterinary Medicine, Shahid Chamran University, Ahvaz, Iran

Article information	Abstract
<p>Article history: Received: 19 Jan 2012 Accepted: 3 July 2012 Available online: 26 Jan 2013 ZJRMS 2013; 15(11): 19-23</p> <p>Keywords: Arsenic Necrosis Echinacea purpura Wound healing</p> <p>*Corresponding author at: Department of Pathobiology, Faculty of Veterinary Medicine, Shahid Chamran University, Ahvaz, Iran. E-mail: rezaie20a@yahoo.com</p>	<p><b>Background:</b> Evaluation of healing effects of <i>Echinacea</i> extract in Arsenic induced dermal necrosis in rat is the objective of this study.</p> <p><b>Materials and Methods:</b> In this experimental study 20 male Wistar rats were divided to 2 groups. Dermal necrosis was induced by subcutaneously arsenic injection (4mg/kg) for 10 days. In group 2, after arsenic receiving, Echinacea were injected intraperitoneally (400mg/kg). After last day of injection, rats were euthanized and pathologic samples were collected from dermal ulcers.</p> <p><b>Results:</b> Histopathologic results revealed necrosis of different dermal layers in arsenic group. There were inflammatory exudates instead of impaired structures. In group 2, there were granulation tissue with high cellularity and new vessels.</p> <p><b>Conclusion:</b> According to this research findings arsenic can induce dermal necrosis which is a good animal model for dermatologic researches and also Echinacea has healing effects and can protect and limit the Arsenic effects.</p>

Copyright © 2013 Zahedan University of Medical Sciences. All rights reserved.

### Introduction

Skin damages due to chemicals are one of the most usual complications in users of these common substances. This kind of damage has been reported in many patients, those who use various systemic and injectable drugs, transplant recipients, patients undergoing chemotherapy and radiation therapy, victims of war, photographers, mine workers, and laboratory experts. Here, some of them are described [1-5]. Cutaneous complications of these compounds are common and a reason for discontinuing the drug. They range from a maculopapular rash to Stevens-Johnson syndrome and toxic epidermal necrosis [1]. Some studies had reported cutaneous complications at the injection site of lipiodol; a compound used in patients with iodine deficiency [2]. Another substance that can cause chemical damage is sulfur mustard, a viscant compound which is used as a chemical weapon due to simple technology production, cheapness, and effectivity [3]. Work-related skin diseases are in the second rank of occupational diseases after musculo-skeletal disorders; and contact dermatitis is the most common skin occupational disease. Despite awareness of this issue, contact dermatitis is still an important cause of workers job change [5]. Photographers are also exposed to various hazardous agents during the process of image processing. Mansouri et al. studied the prevalence of skin diseases among photographers of Tehran and found contact dermatitis in 24% of them [4].

Arsenic is a natural element found in organic and inorganic forms in the earth's crust. Skin changes are early signs of acute and chronic toxicity of arsenic and are

one important problem in mine workers. Arsenic cause hyperpigmentation and keratinization of the palms and soles [6], therefore considering a wide range of involved people, finding a way to reduce the problem and the effects of these chemicals seems necessary.

*Echinacea purpurea* is one of the most important medicinal plants used in pharmaceutical industry of developed countries. This plant is not native to Iran and its seed was imported by Omidbeyege from the University of Budapest, Hungary for the first time and was planted in the research garden of Zardband Medicinal Plants Company [7].

Coneflower has multiple effects such as immune modulating, anti-inflammatory, anti-oxidative, anti-bacterial, and reconstructive. Chicoric acid is a derivative of caffeic acid which is present in *Echinacea purpurea* as the main compound and responsible for most of the plant's mentioned effects [8-10]. Regarding to the above issues and considering various effects of this plant, the aim of the present study is to investigate protective and healing effects of *Echinacea purpurea* extract on skin damages resulted from subcutaneous injection of arsenic as a chemical.

### Materials and Methods

For this experimental study, 30 wistar rats were obtained from the Center of Laboratory Animals of Jundi Shapour, Ahvaz. The rats were randomly divided into three 10-member groups and were maintained at 21-23°C in

special cages with a bed of straw in the Animal House of Veterinary School with 12 hours of light and 12 hours of dark. Feeding and maintenance conditions were identical for all rats.

The study began a week after buying the rats to let them get accustomed to the new situation. The first group, as the control group, had received 4 mg/kg normal saline subcutaneously. The second group had daily received 4 mg/kg arsenic (Merck, Germany; obtained from the Chemistry Laboratory, Faculty of Science, University of Shahid Chamran) subcutaneously in the dorsal skin for 10 days [11]. The injection site was marked on the first day with a marker to perform the injection in the same area in the next days. The third group had received 400 mg/kg intraperitoneal hydroalcoholic extract of Echinacea (extracts prepared from plant shoots in Gol Daru Company of Isfahan, Iran) 30 min after administration of arsenic [12].

This period was considered to prepare the drug and the animal. After the last injection, the animals were easily killed at the eleventh day. Skin and underneath tissues of injection area were precisely examined and then a part of the cutaneous lesion along with underneath tissues were removed and put in 10% buffer formalin solution for further histopathologic studies. After the tissue passage steps, paraffin blocks were prepared and their 5 µm thickness sections were put on glass slides and then were stained with hematoxylin-eosin and Masson trichrome. Microscopic examination was performed after mounting the slides.

## Results

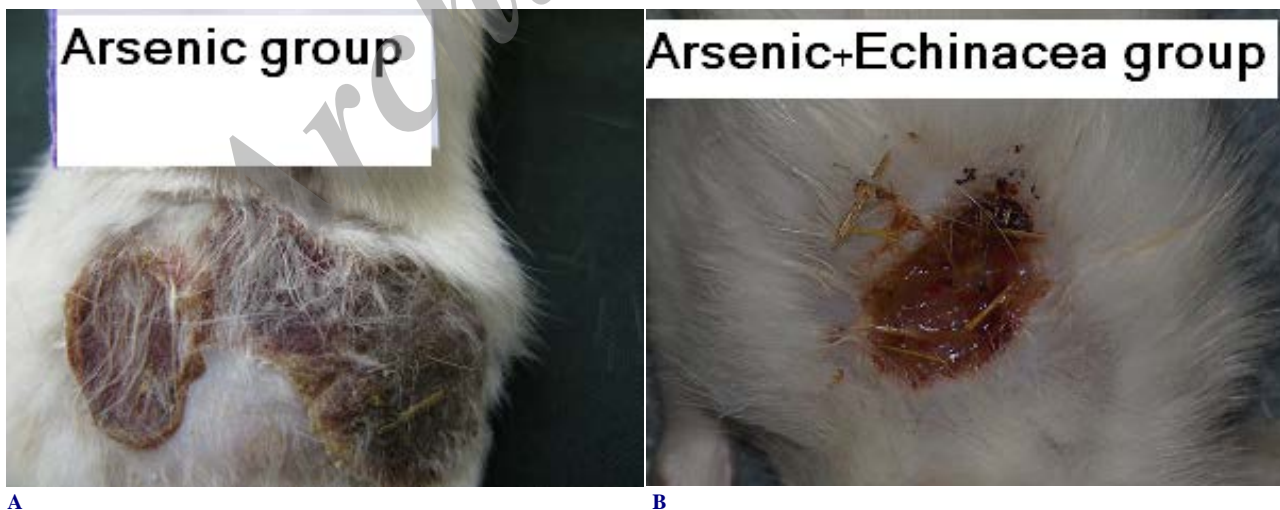Macroscopically, the skin of injection site in arsenic receiving group was darkened after the fourth days and

gradually the hairs on that part were shed. After 10 days, a dark flocculation was visible on the skin surface (Fig. 1A). Subcutaneous muscle was completely pale and edema was observed in subcutaneous and between muscle fibers. In the *echinacea* receiving group, ulcer size was significantly smaller and wound surface was clear (Fig. 1B). Any injury and ulcer was seen in the saline receiving group.

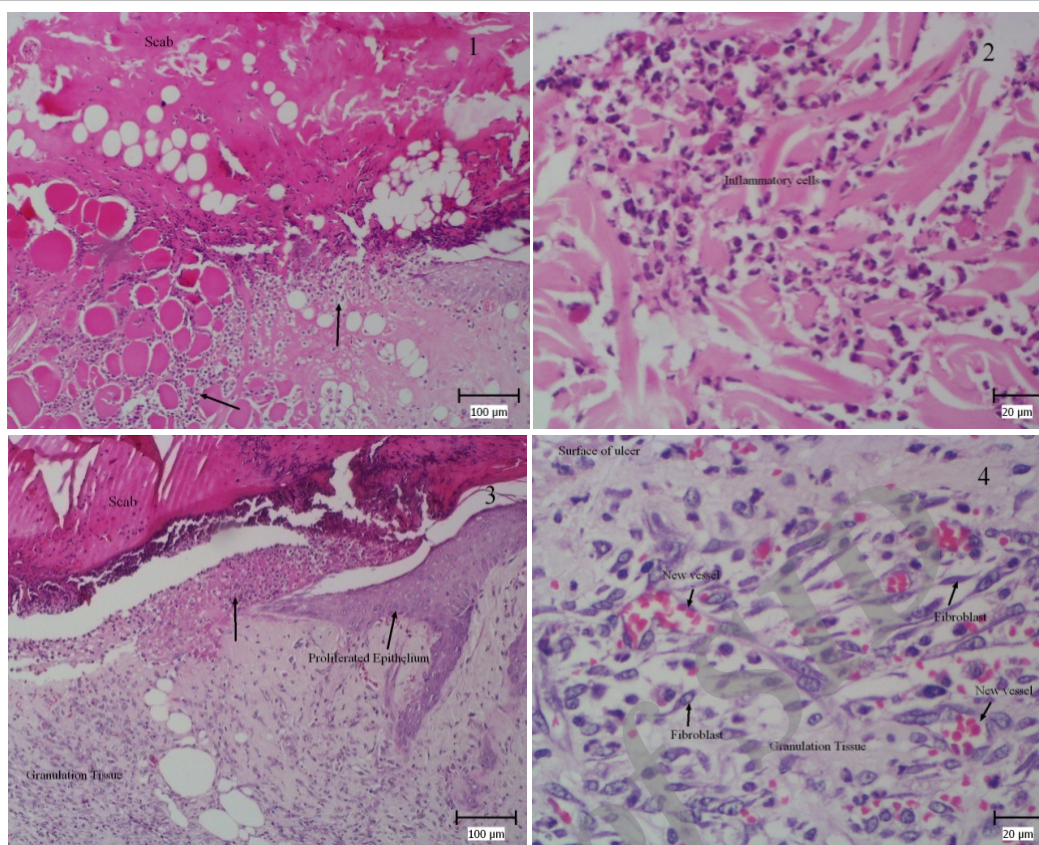
Histopathologic examination of the arsenic receiving group, showed a wide inflammatory exudate in the wound which was made of fibrin fibers, cellular debris, and bacterial colonies. A basophilic line has been formed between normal tissue and the wound, from accumulation of inflammatory cells, particularly neutrophils (Fig. 2.1). Necrosis was observed in the epidermis, dermis, and hypodermis and even in the underlying muscle layer in some cases.

Necrosis was observed in all tissue structures including connective fibers, vessels, nerves, and skeletal muscles. Formation of granulation tissue or proliferation of epidermal fibroblasts and basal cells was not observed at the wound site which means the wound did not enter to the proliferative phase (Fig. 2.2).

In *echinacea* receiving group, exudate and flocculation on the wound was much lower than the previous group, in contrast immature granulation tissue was seen in the wound site (Fig. 2.3). Abundant fibroblasts, pink fibers secreted from cells, and angiogenesis are characteristics of these tissues (Fig. 2.4). Also, the epidermis of wound edges was quite thick, indicating basal cells proliferation there. Masson trichrome, used to identify collagen fibers, revealed high levels of blue fibers which shows secretion of connective fibers from proliferated fibroblasts.



**Figure 1.** A) Brown scab on the ulcer of arsenic received rat is obvious. B) Note to scab color and size of ulcer in arsenic +Echinacea received rat



**Figure 2.** (1) Skin ulcer, arsenic group, note to scab and inflammatory exudates which are located on the ulcer and infiltration of inflammatory cells (arrow). (2) Part of picture 1 with high magnification, inflammatory cells are seen between necrotic tissues. (3) Skin ulcer, arsenic+Echinacea group, note to proliferation of basal cells of ulcer edges, granulation tissue and inflammatory cells beneath scab. (4) Part of picture 3 with high magnification, note to granulation tissue compose of proliferated fibroblasts and secreted fibers and new vessels with red blood vessels (H&E)

## Discussion

The present study showed skin necrosis caused by arsenic in experimental model of rat. This effect not only indicates toxic hazards of this chemical but also may be used as an experimental model to study the drugs effective on wound healing. Also, the study revealed that *Echinacea purpurea* hydroalcoholic extract had a high healing potential and had significantly limited the arsenic impacts.

American Indians used *Echinacea purpurea* since long ago to treat minor wounds and cutaneous infections as well as insect and snakes bites. Several studies have been conducted on the effects of this plant in Iran. Ghaemi et al. studied the impact of alcoholic extract of Coneflower vegetative body on the human herpes simplex virus type I and reported the antiviral effects of this plant. They stated that the extract works through blocking the virus superficial ligands that are responsible for binding to cell surface receptors [13]. Also, Bozorgmehri-Fard et al. examined the plant effects on avian Newcastle virus and ultimately introduced it effective [14]. Hashemi et al. investigated the efficacy of Iranian Coneflower extract on delayed hypersensitivity response and reported that the extract not only had increased proliferation of spleen cells in vitro and in vivo, but also had highly stimulated the delayed hypersensitivity responses [15]. The healing role

of this plant was already investigated by Taqizadeh et al. in order to compare the effects of *Echinacea purpurea* dry shoots extract with zinc oxide on surgical trauma of rats' skin. They expressed that this plant heals open cutaneous lesions faster than zinc oxide [16].

In the present research, the healing effects of this plant were studied on another type of cutaneous lesion and the obtained results were accordant with their reports. Based on the histopathological findings, the wounds of arsenic-echinacea receiving group often showed proliferative phase; also proliferation of fibroblasts and production of collagen fibers was much greater than the arsenic receiving group. This means that the wound had quickly finished the inflammatory phase and entered in the amplification phase. Busing et al. showed that the extract of *Echinacea purpurea* shoots can inhibit hyaluronidase enzyme *in vitro* [8]. The healing effect of coneflower is attributed to echinacin that is known empirically as hyaluronidase enzyme antagonist, which thus indirectly inhibits hyaluronidase enzyme through forming a polysaccharide-hyaluronic acid stable complex. These anti-hyaluronidase compounds prevent the spread of microorganisms within the wound and then accelerate the healing process [17]. Anti-inflammatory effects of the plant have undoubtedly a significant role in promoting the

healing process. As was seen in the slices, the early phase or the inflammatory phase has quickly finished. In 2002, Clifford et al. reported that *Echinacea purpurea* inhibits the secretion of cyclooxygenase 1 and 2 *in vitro* and attributed this effect to isobutylamide compounds called dodecatetraenoic acid.

This plant activates the macrophages as well, which is associated with increased phagocytic activity and increased secretion of macrophage-derived cytokines. These cytokines also affect the fibroblasts and lead to their proliferation and increase, which result in the synthesis of collagen and connective tissue. Differentiation of fibroblasts and angiogenesis are also affected by secreted cytokines. In addition, penetration of abundant new vessels into young granulation tissue accelerates wound healing [19, 20].

*Echinacea purpurea* is proposed to have anti-oxidative effect too [21]. According to many reports arsenic stimulates the production of oxygen free radicals [22, 23]. So it is possible that significant effects seen in the improvement of skin complications may be due to anti-oxidative compounds of the plant.

Taghizadeh et al. used the plant extracts topically, while in this study the drug was injected intraperitoneally. However, the obtained results showed significant impacts which emphasize on this method of use when the wound is painful and the topical application is impossible.

Fallah Hosseini et al. [3] studied the protective effect of silver sulfadiazine cream, pollen cream, and aloe vera cream on sulfur mustard-induced skin lesions. They introduced pollen cream more effective than two others in improving wound healing in a 10 days treatment. They used mustard in their study as the toxic material and reported that epidermal necrosis had occurred and the skin was finally peeled after a few days. In the present study arsenic was used as the toxic substance. Skin histopathological lesions in the arsenic receiving group included necrosis of epidermis, dermis, and in some cases hypodermis and all wounds were in exudative phase. As previously mentioned, skin changes such as hyperpigmentation and keratinization are usual signs of chronic arsenic poisoning. Based on performed research, any report was found about of cutaneous necrosis in the literature, which may be due to neglecting and aiming of the skin. In most research on this drug, the application method was through drinking in order to create chronic hepatotoxicity; some cases were done through subcutaneous injection for similar purpose. So this is the first report of toxic necrosis after arsenic consumption. Based on the findings of this study, arsenic subcutaneous injection can be used as an experimental model for research on the treatment of cutaneous necrosis resulted

from the use of toxic agents such as chemicals. It should also be noted that in the present study, the supportive agent was injected along with stimulation and cutaneous necrosis and regarding to variations in cutaneous wounds of both groups and histopathologic findings, healing and granulation formation are noteworthy in this study.

To study the extracts of three types of *Echinacea* root in wound healing, Speroni et al. topically applied them in short term (24, 48, and 72 hours after the injury) and reported anti-inflammatory and healing effects of this family. They proposed echinacoside isolated from *Echinacea palyda* as the main inhibiting factor of inflammatory mechanisms and accelerating effects in formation of destroyed skin layers. Regarding their pathology reports, *Echinacea purpurea* had extensive anti-inflammatory effects in the first 24 hours after wound creation, while after 72 hours *Echinacea palyda* showed great effects on fibroblasts proliferation [24]. Although the results of *Echinacea purpurea* are consistent with the results of this study, we suggest comparing the effects of both together in another study.

Finally, regarding to mentioned cases about the histopathologic findings, while confirming previous results, this study was the first report on the efficacy of *Echinacea* on subcutaneous injection of arsenic which cause extensive necrosis of skin and *Echinacea purpurea* accelerates wound healing in rats. It seems that *Echinacea* having anti-inflammatory, anti-oxidative, anti-bacterial, and stimulatory effects on fibroblast proliferation can be considered as an appropriate stimulus for healing. Applicability and clinical use of this medicinal plant require more accurate and complete studies, determination of type and percentage of active compounds in the extract, and pharmacological trials.

### Acknowledgements

The authors wish to express their gratitude to the research council of Shahid Chamran University for their financial supports. This article is related to thesis with number 9079750. Also the authors are grateful to Miss. F. Behdarvand and Mr. H. Behdarvand for their technical assistance in pathology laboratory, faculty of Veterinary Medicine, Shahid Chamran University of Ahvaz.

### Authors' Contributions

All authors had equal role in design, work, statistical analysis and manuscript writing.

### Conflict of Interest

The authors declare no conflict of interest.

### Funding/Support

Shahid Chamran University of Ahvaz.

### References

1. Malekafzali B, Najibi F. [Cutaneous reactions of anticonvulsant drugs] Persian. *Dermatol Cosmet* 2011; 2 (1): 30-34.
2. Delfan B, Jembreili R, Mardani M, et al. [Dermal side effects of Lipidol injection in Khoram Abad] Persian. *Yafte* 2003; 5(1): 35-39.
3. Falah-Hosseini H, Kavoli-Haghighi M, Jamshidi AH, et al. The effects of silver sulphadiazine, Bee polen and Aloe vera ointment on dermal injuries due to sulfur mustard] Persian. *Kowsar Med J* 2011; 6(4): 241-7.
4. Mansouri P, Aminian O, Sharifian SA, et al. [Occurance of dermal injured due to developing of photo in

- photographersin Tehran] Persian. Hormozgan Med J 2002; 6(4): 37-43.
5. Wigger AW, Elsner P. Contact dermatitis due to irritation. In: Kanerva L, Elsner P, Wahlberg JE and Maibach HI. Handbook of occupational dermatology. 3<sup>rd</sup>ed. Heidelberg: Springer Press; 2000: 99-111.
  6. Ratnaik RN. Acute and chronic arsenic toxicity. Postgrad Med J 2003; 79(933): 391-396.
  7. Omidbaigi R. [Cultivation and compatibility of Echinacea Purpurea in north of Iran] Persian. Sci Technol Agric Nat Resour 2002; 6(2): 231-240.
  8. Barrett B. Medicinal properties of Echinacea: A critical review. Phytomedicine 2003; 10(1): 66-86.
  9. Wagner H. Search for new plant constituents with potential antiphlogistic and antiallergic activity. Planta Med 1989; 55(3): 235-41.
  10. Muller-Jakic B, Breu W, Probstle A, et al. In vitro inhibition of cyclooxygenase and 5-lipoxygenase by alkamides from Echinacea and Achillea species. Planta Med 1994; 60(1): 37-40.
  11. Santra A, Chowdhury A, Ghatak S, et al. Arsenic induces apoptosis in mouse liver is mitochondria dependent and is abrogated by N-acetylcysteine. Toxicol Appl Pharmacol 2007; 220(2): 146-155.
  12. Khaksary-Mahabady M, Ranjbar R, Arzi A, et al. A comparison study of effects of Echinacea extract and levamisole on phenytoin-induced cleft palate in mice. Regul Toxicol Pharmacol 2006; 46(3): 163-166.
  13. Ghaemi A, Soleimanjahi H, Farshbaf-Moghaddam M, et al. [Evaluation of antiviral activity of aerial part of Echinacea purpurea extract against herpes simplex virus type 1] Persian. Hakim Res J 2007; 9(4): 59-64.
  14. Bozorgmehri-Fard MH, Feizi A, Bijanzad P. [Effect of echinacea purpurea dried extract effect on producing antibody from newcastle disease vaccine in broilers by HI test] Persian. J Vet Res 2010; 65(2): 119-122.
  15. Hashemi SM, Soudi S, Ghaemi A, et al. [Study the Effect of Echinacea purpurea extract on cellular delayed type hypersensitivity and splenocyte proliferation in BALB/c mice] Persian. Cell 2008; 9(4): 254-261.
  16. Taghizadeh-Jahed M, Jarolmasjed SH, Mohamadnejad S, et al. [The effect of Echinacea purpurea aerial organ dried extract vs. zinc oxide on skin wound healing in rat: A morphometric & histopathologic study] Persian. Tehran Univ Med J 2008; 66(9): 625-32.
  17. Bauer R, Wagner H. Echinacea species as potential immunostimulatory drugs. Econ Med Plant Res 1991; 5: 253-321.
  18. Clifford LJ, Nair MG, Rana J and Dewitt DL. Bioactivity of alkamides isolated from Echinacea purpurea (L.) Moench. Phytomedicine 2002; 9(3): 249-53.
  19. Stimpel H, Proksch A, Wagner H, et al. Macrophage activation and induction of macrophage cytotoxicity by purified polysaccharide fractions from the plant Echinacea purpurea. Infect Immun 1984; 46(3): 845-849.
  20. Leuttig B, Steinmuller C, Gifford GE, et al. Macrophage activation by the polysaccharide arabinogalactan isolated from plant cell cultures of Echinacea purpurea. J Natl Cancer Inst 1989; 81(9): 669-675.
  21. Hu C, Kitts DD. Studies on the antioxidant activity of Echinacea root extract. J Agric Food Chem 2000; 48(5): 1466-1472.
  22. Arteel GE, Guo L, Schlierf T, et al. Subhepatotoxic exposure to arsenic enhances lipopolysaccharide- induced liver injury in mice. Toxicol Appl Pharmacol 2008; 226(2): 128-139.
  23. Chen H, Li S, Liu J, et al. Chronic inorganic arsenic exposure induces hepatic global and individual gene hypomethylation: implications for arsenic hepato carcinogenesis. Carcinogenesis 2004; 25(9): 1779-1786.
  24. Speroni E, Govoni P, Guizzardi S, et al. Anti-inflammatory and cicatrizing activity of Echinacea pallida root extract. J Ethnopharmacol 2002; 79(2): 265-272.

**Please cite this article as:** Rezaie A, Najafzadeh H, Poormahdi-Broojeni M, Mohammadian B, Heidari M. Effects of echinacea purpurea on wound healing after arsenic induced skin necrosis. Zahedan J Res Med Sci (ZJRMS) 2013; 15(11): 19-23.