

## Effect of *Vaccinium arctostaphylos* L. Ointment in Contrast of Zinc Oxide in Secondary Healing of Postsurgical Wound

Arvin Tayari,<sup>1</sup> Ali Rezaei,\*<sup>1</sup> Daryoush Mohajeri<sup>2</sup>

1. Department of Clinical Sciences, Veterinary Medicine, Tabriz Branch, Islamic Azad University, Tabriz, Iran
2. Department of Pathobiology, Veterinary Medicine, Tabriz Branch, Islamic Azad University, Tabriz, Iran

Article information	Abstract
<p>Article history: Received: 11 Oct 2013 Accepted: 20 Dec 2013 Available online: 27 Jan 2014 ZJRMS 2014 Oct; 16(10): 7-11</p> <p>Keywords: <i>Vaccinium arctostaphylos</i> Zinc oxide Wounds healing Rats</p> <p>*Corresponding author at: Department of Clinical Sciences Veterinary Medicine, Tabriz Branch, Islamic Azad University, Tabriz, Iran. E-mail: Rezaei.ali14@gmail.com</p>	<p><b>Background:</b> Skin wound healing is very significant physiological procedure. It is quite obvious that promoting this healing is important too. One of the most popular compounds used ever for skin care is <i>Vaccinium arctostaphylos</i> essential oil. In this study we tried to compare the effects of <i>V. arctostaphylos</i> and zinc oxide on secondary intentioned open-wound healing in rats.</p> <p><b>Materials and Methods:</b> In this experimental study, 75 male rats included in 5 groups: eucerin, zinc oxide, <i>Vaccinium</i> extract 10 and 20%, not treated. The whole operation was taking place under general anesthesia circumstances. Took photos continuously 21 days after wound creation and catch biopsy intervals were 3, 7, 14 and 21 days. Wounds areas are measured by Scion Image™ software. At last, all data were analyzed using SPSS-17.</p> <p><b>Results:</b> As a result <i>V. arctostaphylos</i> with dose of 20% has significant healing properties compared to zinc oxide. These data were validating under confidence surface of 99% (<math>p &lt; 0.01</math>).</p> <p><b>Conclusion:</b> Base on earned data it will be suitable to use of zinc oxide ointment for healing reason but there is opportunity to researcher to survey higher dose of this plant extraction in contrast of zinc oxide.</p> <p>Copyright © 2014 Zahedan University of Medical Sciences. All rights reserved.</p>

### Introduction

Wound means any destroying in a normal anatomic structure and its function which can be epithelium or deeper. Delay in the process of wound healing is one of the basic problems especially in the elderly. Therefore, with notice of time factor, 2 kinds of wounds are defined: the acute wound is a kind of fragmentation of body like burning or laceration, but the wound which lasts for long time to heal is transferred to a chronic wound [1, 2].

The wound healing process is a combination of coordinated mechanisms which control the infection; the inflammation is occurred in result of angiogenesis and increase blood flow and the healing is done by deposition of granulation tissue and contraction, finally its maturity [1, 3]. Wound healing has 4 phases, they contain: 1- Coagulation and homeostasis phase which is occurred immediately after wound creation and creates a matrix in wound area. 2- The inflammatory phase which starts after the previous phase and its aim is establishing immunity in the wound area against microorganism. 3- Proliferation phase occurs when the 2 first phases function successfully and acute wound progresses toward wound healing [2, 4-7]. 4- Wound remodeling phase, which is replaced by scar tissue and starts from 21st day and lasts for 1 year and even more than its. Wound healing process is done as primary and secondary approaches. In the primary state, the open wound's gap is closed but in the secondary state, the gap is not closed due to degradation and lasts more than the primary state, it needs more granulated tissue [2-

5, 7, 8]. The medicinal herbs have chemical complex and nutritive compounds in their different parts including root, stem, leaf, flower, or fruit. Nowadays, it is tried to use medicinal herbs for treating diseases [9]. *Vaccinium arctostaphylos* L. has many treating effects of which we can mention to anti-inflammatory, anti-cancer, disinfectant, analgesic, astringent, anti-itch, anti-eczema, stopping bleeding, and anti-oxidants. This plant is available in northern part of Iran which is known as Qaraqat or Cyah-gileh [10-12]. *V. arctostaphylos* has compounds like caffeoylquinic acid, caffeic acid, coumaric acid, derivatives of hydroxyl-cinnamic acid and its most important compound is phenolic acids which include antosianin and flavonoids which are recognized as anti-oxidant, anti-inflammatory, and anti-viral. This plant is used in herbal medicine for treating high blood pressure and diabetes [10, 13, 14].

Zinc acts as a cofactor in multiple transcription factors and enzyme systems including zinc-dependent matrix metalloproteinases that magnify autodebridement and keratinocyte migration during wound repair. Zinc causes resistance to epithelial apoptosis through cytoprotection against reactive oxygen species and bacterial toxins possibly through antioxidant activity of the cysteine-rich metallothioneins.

Zinc oxide in paste bandages protects and soothes inflamed peri-ulcer skin. Zinc is transported through the skin from these formulations, although the systemic effects seem insignificant [15-17].

Lanolin is a natural substance that took sheep wool, also now a day that's produced synthetic. Lanolin or euchring has used for ointments bases and allows that effective materials solve in it likely homogeneous. Euchring is also used lonely for protection of wound [18].

In this study we have intention to explore of geometric and histopathology effect of *V. arctostaphylos* L. extract on the healing of open wound by secondary approaches in contrast of zinc oxide therapy.

## Materials and Methods

In this experimental study, we divided 75 male Wistar rats, weighed  $200 \pm 15$  g, and approximate age of 3 month old to 5 groups of 15 rats, after precise examination regarding their being healthy. They were kept for 1 week in laboratory environment in  $22 \pm 2^\circ\text{C}$  and relative humidity of 70% under 12 h lightening and darkness period to being accustomed to vitro.

After intramuscular anesthesia with 5 mg/kg xylazine and 40 mg/kg hydrochloride examine in all 5 groups, a surgery wound was made by 25 mm diameter template in the back skin of animal with all thickness.

The first group received 20% *V. arctostaphylos* ointment (20 g *V. arctostaphylos* powder in 80 g euchring), the second group received 10% *V. arctostaphylos* ointment, the third group received 20% commercial zinc oxide ointment, the fourth group received eucerin (1.5 g tropical once a day) as a placebo and the fifth group received no drug. During the healing procedure, clinical photos were taken continuously in 21 days, after wound creation, from the mentioned area (skin) by Nikon coolpix P5100 digital camera, (Made in Japan) and then under anesthesia took sampel for histopathological study [19].

Five-hundred grams of *V. arctostaphylos* L. was powdered and was solved in 4 L polar solvents like metanol for 48 h. In duration they were dissolved by rotary in vacuum, so polar extract became ready, the obtained extract was mixed with eucerin. Then 10% and 20% ointments of *V. arctostaphylos* L. were prepared.

In order to morphometric study, the digital photos that took continuously in 21 days, were studied by image analyzing software of Scion Image Beta 4.0.2 software, (Scion, Frederick, MD, USA). The statistical data were analyzed by SPSS-17 statistical software (ANOVA) and Tukey test defined the significance between groups and the test's significance level was defined as ( $p < 0.01$ ). For histopathologic study, histopathologic observations base on healing factors, ranking compared between groups and earned data analyzed by SPSS-17 and Kruskal-Wallis.

## Results

Table 1 show significant difference between the witness (control group) and the 2 treated groups with 20% *V. arctostaphylos* and zinc oxide, though there was no significant difference between the control group and eucerin group ( $p = 0.01$ ). In 7th day, there was no significant difference between treated group with 20% *V. arctostaphylos* and zinc oxide ( $p = 0.01$ ). In 14th day, there was no significant difference between the treated group with 20% *V. arctostaphylos* and zinc oxide ( $p < 0.01$ ). In 21st day, there was significant difference among all groups ( $p < 0.01$ ). According to unilateral variance analysis, there obtained very significant difference ( $p < 0.01$ ) in confidence level of 99%.

Table 2 based on Kruskal-Wallis test in this ranking comparison between the groups during 21 days has significant difference ( $p = 0.004$ ).

Figure 1 geometric photo took continuously in 21 days and in this photo the wounds area and size is visible. It's clear that the wounds size are different in each group, base on the analyze with Scion image software, the best group in contraction wound after 21 day is zinc oxide.

Figure 2 show the histopathologic photos of 5 groups in 21 days after surgery.

All of histopathological photos for 3, 7, 14 and 21 days after surgery of all groups were investigated base on healing factors such as: hemostasis rate, inflammation rate, fibroplasia process, re-epithelialization rate.

**Table 1.** Wound area in the studied groups as scheduling

Groups	Day 0 (Mean±SD) (mm <sup>2</sup> )	Day 3 (Mean±SD) (mm <sup>2</sup> )	Day 7 (Mean±SD) (mm <sup>2</sup> )	Day 14 (Mean±SD) (mm <sup>2</sup> )	Day 21 (Mean±SD) (mm <sup>2</sup> )
Witness (N=3)	446.18±0.00	676.47±5.83 <sup>c</sup>	292.60±3.82 <sup>c</sup>	107.26±2.79 <sup>c</sup>	81.78±1.41 <sup>d</sup>
Eucerin (N=3)	446.18±0.00	674.60±3.93 <sup>c</sup>	348.58±3.94 <sup>d</sup>	150.43±3.18 <sup>d</sup>	98.60±2.1 <sup>e</sup>
<i>V. arctostaphylos</i> 10% (N=3)	446.18±0.00	670.57±5.95 <sup>b,c</sup>	239.69±3.94 <sup>b</sup>	52.29±2.03 <sup>b</sup>	33.15±1.13 <sup>c</sup>
<i>V. arctostaphylos</i> 20% (N=3)	446.18±0.00	655.58±5.12 <sup>a,b</sup>	229.14±4.4 <sup>a,b</sup>	41.42±4.04 <sup>a</sup>	21.48±1.59 <sup>b</sup>
Zinc oxide 20% (N=3)	446.18±0.00	640.49±5.14 <sup>a</sup>	219.71±2.36 <sup>a</sup>	37.48±2.01 <sup>a</sup>	15.57±0.8 <sup>a</sup>

The different letters indicates the significance between groups (a, b, c, d, e)

**Table 2.** Histopathological marks, based on ranking compared for studied groups

	Day 0 (Mean±SD)	Day 3 (Mean±SD)	Day 7 (Mean±SD)	Day 14 (Mean±SD)	Day 21 (Mean±SD)
Witness (N=3)	1.00±0.00	4.0±1.0	6.66±0.57	9.66±0.57	14.66±0.57
Eucerin (N=3)	1.00±0.00	3.66±0.57	6.33±1.15	8.33±1.15	13.33±0.57
<i>V. arctostaphylos</i> 10% (N=3)	1.00±0.00	6.66±0.57	9.00±1.00	11.66±0.57	17.66±0.57
<i>V. arctostaphylos</i> 20% (N=3)	1.00±0.00	7.33±0.57	10.66±0.57	15.66±0.57	18.66±0.57
Zinc oxide 20% (N=3)	1.00±0.00	8.33±0.57	12.66±0.57	16.33±1.15	20.66±0.57

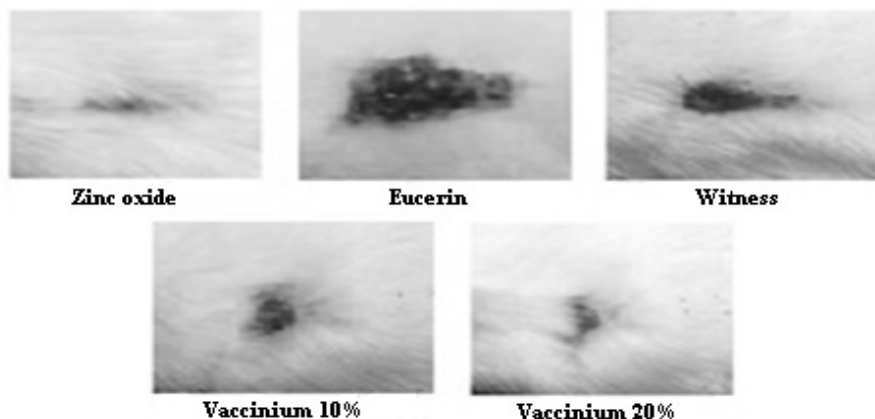


Figure 1. Shows the wounds size in the latest day of experiment

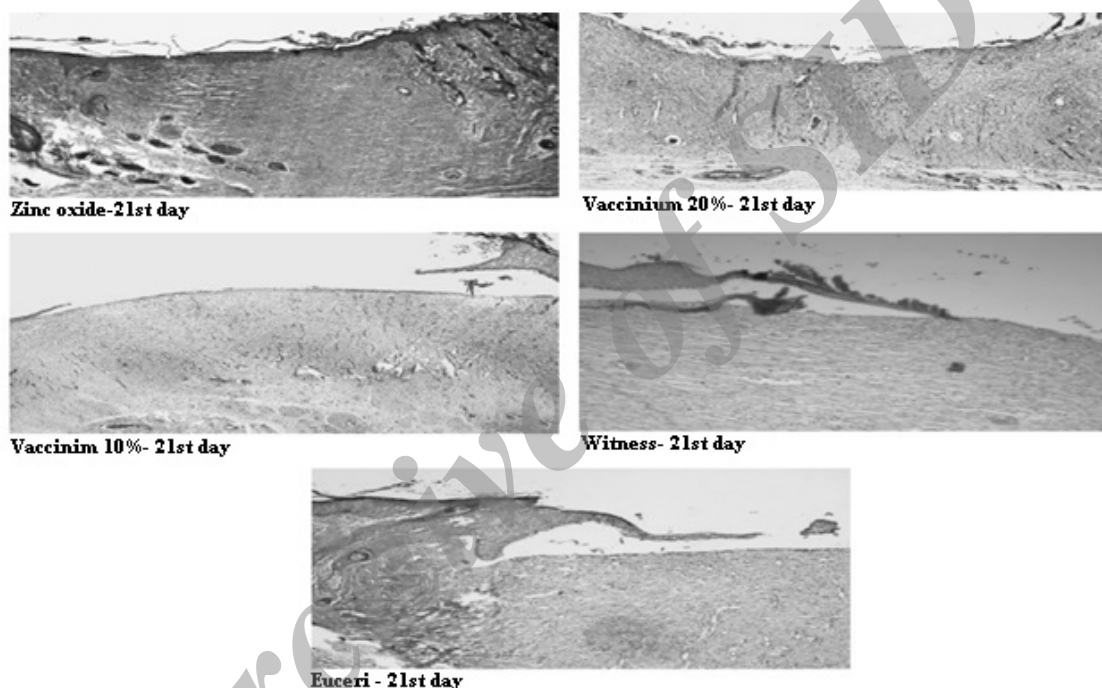


Figure 2. The histopathological images from wound section of 5 groups in 21 days after surgery

## Discussion

Regarding the obtained data and statistical analysis, we can realize from the findings that *V. arctostaphylos* has healing effects on open wounds. In this study, it was defined that 20% *V. arctostaphylos* extract based on eucerin has the most wound collecting effects after zinc oxide, but 10% *V. arctostaphylos* extract acts less than 20% in quickening the process of wound healing. *V. arctostaphylos* have strong anti-fungal and anti-microbial effects. Zinc oxide leads to clotting in open wound very quickly and this property is suitable for using in open wounds. The control group was better in contrast of eucerin. Zinc oxide ointment is one of the most used ointments in treating tropical wounds, which includes 20% zinc oxide powder. Surface protections, being astringent, relative anti-septic and non-toxic are the

remarkable properties which caused that this drug is nowadays used as an effective material in health and pharmaceutical compounds widely. In this research, this ointment is used as a positive control group. Also this plant has salicylic acid and anti prostaglandins, which prevents from bradykinin activity in wound and therefore justifies its analgesic effect. On the whole, there was no difference in geometric results, regarding their coordination with the hypothesis and decreasing the wound size was resulted from decreasing the inflammation and progression of wound healing and as it was presented in results, the best response was related to 20% *V. arctostaphylos* group after zinc oxide. Since *V. arctostaphylos* extract stimulated the activity of fibroblast and macrophages, these 2 cell lines quicken the wound healing which interacting with each other and simulation of new blood vessels to young granulated

tissue. Zinc oxide ointment has the similar effects like 20% *V. arctostaphylos* ointment in 2 first weeks and in the last week, it was better than it. Eucerin shows the least healing in whole of period and the control group had better results than eucerin by the end of period. It seems necessary to do different trials like assessing the histopathological effects and serum level of growth factors in order to introduce the precise mechanism of this herbal extract.

Shivananda-Nayak et al. comparatively studied the effect of kind of *Vaccinium* named as *Vaccinium macrocarpon* with other plant named as *Vitis vinifera* on the wound healing in rats and concluded that both have treating effect on wound healing [20]. Song et al. studied the effect of *Vaccinium myrtillus* L. on tissue culture of epithelial cells of sclera and concluded that the extract of this plant does not have cytotoxic effects and increases the cells livability after 48 h and decreases the number of cells at G0 and G1 phases and increases the number of G2 and M cells. Therefore, it is suitable for renewal of epithelial cells and its homeostasis [21]. Ahmet et al. studied the Blueberry enriched diet protects rat heart from ischemic damage and concluded that *Vacciniums* reduce infarct size following ischemia and reperfusion [22]. Toufektsian et al. studied chronic dietary intake of plant-derived anthocyanins protects the rat heart against ischemia reperfusion injury and concluded that anthocyanin has powerful antioxidant and protection effects [23]. Su

studied about *Vaccinium* L. species and concluded this plant species have many derivatives of anthocyanin and flavonoids that this matters are important in accelerating in wound healing [14]. So base on previous studies we try in this study to get to this aim that *V. arctostaphylos* has significant wound healing properties in skin specially in contrast of zinc oxide, because we wanted to have a standard in wound healing. Since Feshani et al. studied the anti-diabetes effects of a kind of *Vaccinium* named as *V. arctostaphylos* on diabetic rats with alloxan and concluded that this plant has anti-diabetes, so we can suggest that there is a free place of *Vaccinium arctostaphylos* effects on wound healing in diabetics [24]. Also this extract can be used in lotion and shampoo.

### Acknowledgements

This study is part of DVM thesis for Arvin Tayari with number of 10210501902045 and Special thanks to Azad University of Tabriz, faculty of veterinary medicine.

### Authors' Contributions

All authors had equal role in design, work, statistical analysis and manuscript writing.

### Conflict of Interest

The authors declare no conflict of interest.

### Funding/Support

Islamic Azad University, Tabriz.

### References

- Pham C, Middleton P, Maddern G. Vacuum-assisted closure for the management of wounds: An accelerated systematic review. Available from: [http://www.surgeons.org/AM/Template.cfm?Section=ASERNIP\\_S\\_Publications&Template=/TaggedPage/TaggedPageDisplay.cfm&TPLID=17&ContentID=4220](http://www.surgeons.org/AM/Template.cfm?Section=ASERNIP_S_Publications&Template=/TaggedPage/TaggedPageDisplay.cfm&TPLID=17&ContentID=4220); 2003.
- Velnar T, Bailey T, Smrkolj V. The wound healing process: An overview of the cellular and molecular mechanisms. *J Int Med Res.* 2009; 37(5): 1528-42.
- Monaco JL, Lawrence WT. Acute wound healing an overview. *Clin Plast Surg.* 2003; 30(1): 1-12.
- Diegelmann RF, Evans MC. Wound healing: An overview of acute, fibrotic and delayed healing. *Front Biosci.* 2004; 9: 283-9.
- Li J, Chen J, Kirsner R. Pathophysiology of acute wound healing. *Clin Dermatol.* 2007; 25(1): 9-18.
- Werner S. Molecular and cellular mechanisms of tissue repair. *Exp Dermatol.* 2005; 14(10): 786-7.
- Witte MB, Barbul A. General principles of wound healing. *Surg Clin North Am.* 1997; 77(3): 509-28.
- Tsala DE, Nnanga N, Mendimi N, et al. A dermal wound healing effect of water extract of the stem bark of *Alafia multiflora* Stapf. *Phytomedicine.* 2013; 4: 114-122.
- Raina R, Parwez S, Verma P and Pankaj N. Medicinal plants and their role in wound healing. *Online Vet J.* 2008; 3(1): 21.
- Nickavar B, Amin G. Anthocyanins from *Vaccinium arctostaphylos* berries. *Pharm Biol.* 2004; 42(4-5): 289-91.
- Oryan A, Naeini AT, Nikahval B and Gorjian E. Effect of aqueous extract of *Aloe vera* on experimental cutaneous wound healing in rat. *Vet Arh.* 2010; 80(4): 509-22.
- Keast D, Orsted H. The basic principles of wound care. *Ostomy Wound Manage.* 1998; 44(8): 24-8.
- Ayaz FA, Hayirlioglu-Ayaz S, Gruz J, et al. Separation, characterization, and quantitation of phenolic acids in a little-known blueberry (*Vaccinium arctostaphylos* L.) fruit by HPLC-MS. *J Agric Food Chem.* 2005; 53(21): 8116-22.
- SSu Z. Anthocyanins and flavonoids of *Vaccinium* L. *Pharm Crops.* 2012; 3: 7-37.
- Agren MS. Studies on zinc in wound healing. *Acta Derm Venereol Suppl (Stockh).* 1990; 154: 1-36.
- Andrews M, Gallagher-Allred C. The role of zinc in wound healing. *Adv Wound Care.* 1999; 12(3): 137-8.
- Lansdown AB, Mirastschijski U, Stubbs N, et al. Zinc in wound healing: Theoretical, experimental, and clinical aspects. *Wound Repair Regen.* 2007; 15(1): 2-16.
- Kraft E. Lanolin derivatives essentially comprising esters of lanolin alcohol with lactic acid. Google Patents; 1974.
- Rezaie A, Mohajeri D, Valilou M, et al. Geometric and histopathologic assessment of Yarrow extracts (*Achillea millefolium*) and on healing of experimental skin wounds and its comparison with zinc oxide on rats. *Curr Res J Biol Sci.* 2012; 4(1): 90-95.
- Shivananda Nayak B, Dan Ramdath D, Marshall JR, et al. Wound healing properties of the oils of *vitis vinifera* and *Vaccinium macrocarpon*. *Phytother Res.* 2011; 25(8): 1201-8.
- Song J, Li Y, Ge J, et al. Protective effect of bilberry (*Vaccinium myrtillus* L.) extracts on cultured human corneal limbal epithelial cells (HCLEC). *Phytother Res.* 2010; 24(4): 520-4.

22. Ahmet I, Spangler E, Shukitt-Hale B, et al. Blueberry-enriched diet protects rat heart from ischemic damage. *PLoS One*. 2009; 4(6): e5954.
23. Toufektsian MC, de Lorgeril M, Nagy N, et al. Chronic dietary intake of plant-derived anthocyanins protects the rat heart against ischemia-reperfusion injury. *J Nutr*. 2008; 138(4): 747-52.
24. Feshani AM, Kouhsari SM, Mohammadi S. *Vaccinium arctostaphylos*, a common herbal medicine in Iran: Molecular and biochemical study of its antidiabetic effects on alloxan-diabetic Wistar rats. *J Ethnopharmacol*. 2011; 133(1): 67-74.

Archive of SID

*Please cite this article as:* Tayari A, Rezaei A, Mohajeri D. Effect of *Vaccinium arctostaphylos* L. ointment in contrast of zinc oxide in secondary healing of postsurgical wound. *Zahedan J Res Med Sci*. 2014; 16(10): 7-11.