



# The First Case of COVID-19 Reinfection in Duhok City, Kurdistan Region of Iraq: A Case Report

Nawfal Rasheed Hussein<sup>1</sup>, Dildar H Musa<sup>2</sup>, Ibrahim Abdulqader Naqid<sup>1,\*</sup>, Zana Sidiq M. Saleem<sup>2</sup> and Nashwan Ibrahim<sup>2</sup>

<sup>1</sup>Department of Biomedical Science, College of Medicine, University of Zakho, Kurdistan Region, Iraq

<sup>2</sup>Department of Internal Medicine and Surgery, College of Medicine, University of Duhok, Kurdistan Region, Iraq

\*Corresponding author: Department of Biomedical Science, College of Medicine, University of Zakho, Zakho International Road, Kurdistan Region, Iraq. Email: ibrahim.naqid@uoz.edu.krd

Received 2020 November 21; Accepted 2020 November 24.

## Abstract

**Introduction:** Coronavirus disease (COVID-19) causes a severe acute respiratory syndrome and is known as coronavirus 2 (SARS-CoV-2), which was first discovered in December, 2019 in Wuhan, China. The question of whether the COVID-19 patients that recover from the disease acquire immunity or are still susceptible to reinfection remains unanswered.

**Case Presentation:** In this study, we presented the case of a 46-year-old male who recovered from the first round of COVID-19 infection. After symptom resolution, two consecutive negative real-time reverse transcription-polymerase chain reaction (RT-PCR) tests confirmed the negativity of the patient. Seven weeks after the first infection, the patient presented with fever and dry cough, and the infection was confirmed using real-time RT-PCR. The reinfection was associated with more severe symptoms, which required antiviral treatment.

**Conclusions:** Our study indicated the possibility of COVID-19 reinfection. If the occurrence of reinfections is confirmed, it may implicate changes in the vaccine and community-based disease prevention strategies. Further studies are required to confirm the possibility of COVID-19 reinfection.

**Keywords:** COVID-19, Reinfection Case, Duhok City, Kurdistan

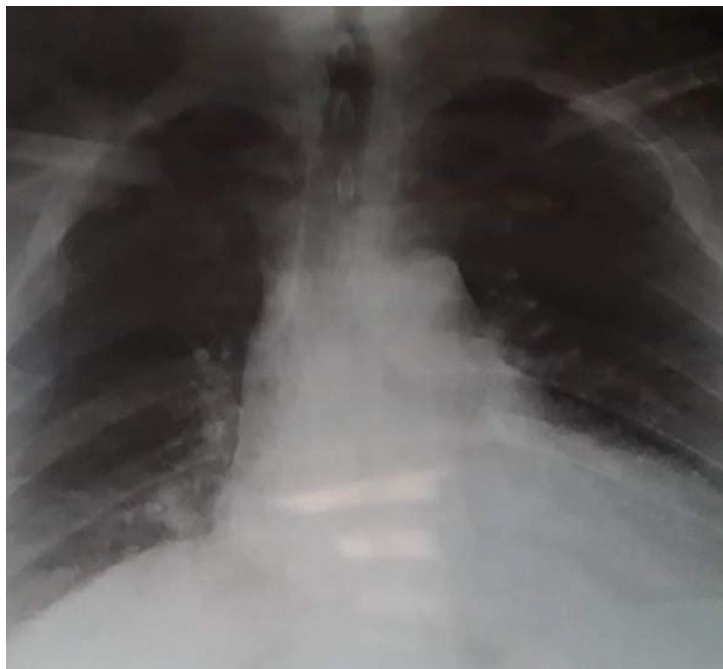## 1. Introduction

The first case of severe acute respiratory syndrome coronavirus 2 (SARS-CoV-2) was discovered in November, 2019 in Wuhan city, China. The infection associated with this novel virus is known as the coronavirus disease (COVID-19), which has become a global pandemic (1). The infection causes various diseases ranging from mild to severe acute respiratory distress syndrome. After the symptom resolution, patients with COVID-19 are considered non-infectious, and two successive negative real-time reverse-transcription polymerase chain reaction (RT-PCR) test results are performed at a 24-hour interval. However, reinfection may be possible after recent reports have shown that recovered patients may test positive after a symptom-free period (2-4).

In this study, we have described the case of a possible SARS-CoV-2 reinfection.

## 2. Case Presentation

A 46-year-old male presented on the 15th of October, 2020 with fever, sore throat, cough, and loss of taste and smell. In the examination, the patient's chest was clear, and he was hemodynamically stable with the temperature of 38.4°C and SpO<sub>2</sub> of 96% without oxygen. The patient tested positive for SARS-CoV-2 in the RT-PCR. Various parameters of the patient were as follows: Hb = 13.6 g/L; platelet count =  $244 \times 10^9$ ; white blood cell count =  $8.5 \times 10^9$ ; C-reactive protein = 23.77 mg/L; D-dimer = 156 ng/mL; ferritin = 447 ng/mL. The chest X-ray of the patient was unremarkable for COVID-19 (Figure 1). After four days, the symptoms persisted, and oxygen saturation decreased to 94%. The patient received treatment with favipiravir (800 mg PO BID) on the first day, followed by 600 mg PO BID for five days. After five days, the patient demonstrated clinical improvement, and on the 6th of November, he was cured after two subsequent negative RT-PCR tests for SARS-CoV-2.



**Figure 1.** Posteroanterior (PA) view of chest radiograph showing normal chest X-ray

The medical records of the patient showed that on the 2nd of August, 2020, he had experienced one day of fever and dry cough. Nevertheless, the patient was hemodynamically stable, non-hypoxic ( $SpO_2$ : 97% without oxygen), and febrile ( $38.5^\circ C$ ). In addition, the patient had a history of contact with positive SARS-CoV-2 cases, and the results of the RT-PCR for SARS-CoV-2 became positive again. As such, treatment was initiated with azithromycin (500 mg qDay), zinc tablets (50 qDay), and vitamin D (5,000 I.U qDay). Clinical improvement was observed in the patient, and two successive RT-PCRs for SARS-CoV-2 showed negative results on the 22nd of August (Figure 2).

### 3. Discussion

In the current report, we presented the first case of COVID-19 reinfection in Iraq. Similar to the case report in the United States, the second infection was associated with increased symptoms, which required antiviral treatment (5). This is in contrast to the case reports in Hong Kong, Belgium, and Netherlands, in which the severity of the cases has been reported to be the same in both rounds of the infection (3, 4). The reinfection in our case could be partially explained by the extremely high dose of the virus, which prompted the high viral load and increased the severity of

the disease. On the other hand, the reinfection might have been caused by the mutated version of the virus. Viral load examination and genetic comparison are required for the confirmation of such cases, both of which are not available in Iraq. Notably, our case had no immunological disorders that may have waned immunity and received no medications that may have weakened the immune function.

Reinfection has several implications for the role of vaccination against COVID-19. If the concept of reinfection is confirmed, the initial infection with the virus might not induce adequate immunity to prevent the second infection. Furthermore, if reinfection occurs due to a wide range of viruses or the mutated strains, the continuous update of the vaccine is required, and the vaccine should encompass more than one strain. Additionally, our findings have implications for the role of herd immunity as a preventative strategy. If reinfection occurs frequently, herd immunity would be rendered ineffective.

The major limitation of the present study was that the immune response after the first infection was not monitored, and it remains unclear whether the immunity of the patient waned over time or it was a weak immune response since the beginning. The second limitation was the unavailability of the first infection sample for the genetic comparison of the viruses that caused both infections.

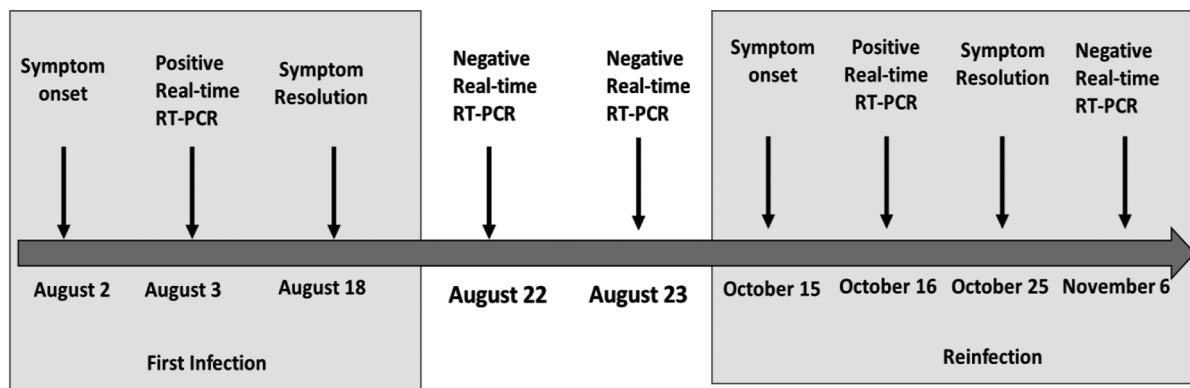


Figure 2. Timeline of symptom onset and molecular diagnosis of possible COVID-19 reinfection (RT-PCR: reverse transcription-polymerase chain reaction)

To conclude, reinfection with SARS-CoV-2 is possible. If confirmed, this concept has several implications for the role of herd immunity as a preventative strategy.

**Footnotes**

**Authors' Contribution:** All the authors were involved in designing the research, conducted research, extracted data and wrote the manuscript. All authors had primary responsibility for the final content of the manuscript and all authors read and approved the final manuscript

**Conflict of Interests:** We wish to confirm that there are no known conflicts of interest associated with this publication.

**Ethical Approval:** The study was approved by the scientific and ethics committee, College of Medicine, University of Zakho, Kurdistan region, Iraq.

**Funding/Support:** No funding or support.

**Informed Consent:** Written informed consent was obtained from participant.

**References**

1. Zhu N, Zhang D, Wang W, Li X, Yang B, Song J, et al. A novel coronavirus from patients with pneumonia in China, 2019. *N Engl J Med*. 2020;**382**(8):727-33. doi: [10.1056/NEJMoa2001017](https://doi.org/10.1056/NEJMoa2001017). [PubMed: [31978945](https://pubmed.ncbi.nlm.nih.gov/31978945/)]. [PubMed Central: [PMC7092803](https://pubmed.ncbi.nlm.nih.gov/PMC7092803/)].
2. Tillett RL, Sevinsky JR, Hartley PD, Kerwin H, Crawford N, Gorzalski A, et al. Genomic evidence for reinfection with SARS-CoV-2: a case study. *Lancet Infect Dis*. 2020.
3. To KK, Hung IF, Ip JD, Chu AW, Chan WM, Tam AR, et al. COVID-19 re-infection by a phylogenetically distinct SARS-coronavirus-2 strain confirmed by whole genome sequencing. *Clin Infect Dis*. 2020. doi: [10.1093/cid/ciaa1275](https://doi.org/10.1093/cid/ciaa1275). [PubMed: [32840608](https://pubmed.ncbi.nlm.nih.gov/32840608/)]. [PubMed Central: [PMC7499500](https://pubmed.ncbi.nlm.nih.gov/PMC7499500/)].
4. Mao R, Qiu Y, He JS, Tan JY, Li XH, Liang J, et al. Manifestations and prognosis of gastrointestinal and liver involvement in patients with COVID-19: a systematic review and meta-analysis. *Lancet Gastroenterol Hepatol*. 2020;**5**(7):667-78. doi: [10.1016/S2468-1253\(20\)30126-6](https://doi.org/10.1016/S2468-1253(20)30126-6). [PubMed: [32405603](https://pubmed.ncbi.nlm.nih.gov/32405603/)]. [PubMed Central: [PMC7217643](https://pubmed.ncbi.nlm.nih.gov/PMC7217643/)].
5. Hussein NR, Naqid IA, Saleem ZSM, Almizori LA, Musa DH, Ibrahim N. A sharp increase in the number of COVID-19 cases and case fatality rates after lifting the lockdown in Kurdistan region of Iraq. *Ann Med Surg (Lond)*. 2020;**57**:140-2. doi: [10.1016/j.amsu.2020.07.030](https://doi.org/10.1016/j.amsu.2020.07.030). [PubMed: [32754314](https://pubmed.ncbi.nlm.nih.gov/32754314/)]. [PubMed Central: [PMC7377994](https://pubmed.ncbi.nlm.nih.gov/PMC7377994/)].