

Polymorphic cutaneous sarcoidosis: A case report

Bhushan Madke, MD¹
 Somshukla Ray, MBBS²
 Mahim Jain, MBBS²
 Chitra Nayak, MD³

1. Assistant Professor, Department of Dermatology, Topiwala National Medical College
2. Resident
3. Professor and Head

Corresponding Author:
 Bhushan Madke, MD
 Assistant Professor, Department of Dermatology, Topiwala National Medical College
 Email: drbhushan81@gmail.com

Conflict of interest : none to declare

Received: December 29, 2011
 Accepted: January 3, 2012

Sarcoidosis (Besnier-Boeck-Schaumann disease) is a multisystem disease of unknown etiology with various cutaneous presentations. It is characterized by the presence of non-caseating 'naked' granulomas in the affected tissue. We report a case of polymorphic cutaneous sarcoid in a 39-year-old immunocompetent male. He was visited at our outpatient department with multiple asymptomatic red colored raised lesions on different parts of the body. His history was significant for smoking and diabetes mellitus of varying duration. Cutaneous examination revealed multiple well-defined erythematous plaques of various shapes and sizes with minimal scaling. His blood investigations were normal except for raised serum angiotensin converting enzyme levels. Radiological investigations showed reticulonodular, fibrotic changes and hilar adenopathy on the chest film. We report this case to apprise clinicians of the fact that cutaneous sarcoid is a great mimicker due to lesional polymorphism and could be mistaken for a common dermatosis like psoriasis in our case.

Keywords: Sarcoidosis, sarcoid, psoriasiform, polymorphic

Iran J Dermatol 2011; 14: 144-148

INTRODUCTION

Sarcoidosis (from sarc meaning flesh, -oid, like, and -osis, process) is a chronic noninfectious granulomatous disease that can present with cutaneous involvement alone or affect many organs such as the lungs, eyes, lymph nodes, kidney, central nervous system, parotid glands and bones.¹ Cutaneous involvement occurs in about 20-30% of the patients with systemic sarcoidosis and skin lesions have been classified into specific and non-specific. Specific cutaneous lesions of systemic sarcoidosis are seen in 9-37% of the cases, and can be further classified as maculopapular, plaque, lupus pernio (LP), scar sarcoidosis, and subcutaneous sarcoidosis.^{2,3} The nonspecific cutaneous lesion of sarcoidosis, Erythema Nodosum (EN), is usually seen in acute forms of the disease and is associated with bilateral hilar lymphadenopathy (Löfgren syndrome).^{4,5} We present a case of a patient who had multiple specific lesions of sarcoidosis with

underlying systemic involvement.

CASE REPORT

A 39-year-old immunocompetent male was visited at our outpatient department with multiple non-itchy red raised lesions on various parts of the body, which were present since seven years ago. Due to the non-troublesome nature of the lesions, the patient did not seek any medical advice and was not currently on any treatment. On detailed inquiry, the patient gave history of intermittent low grade fever, breathlessness on climbing a normal flight of stairs and dry coughs for ten years duration. He also reported development of new lesions at the site of trauma. His past medical history showed that he was diabetic and hypertensive. Personal history was remarkable for cigarette smoking (one pack per day) and occasional alcohol intake for the past 20 years. Family and occupational history were non-contributory in our case. He gave no history

of any ocular or salivary gland involvement in the form of dry eyes or mouth.

Detailed cutaneous examination showed multiple normo-esthetic erythematous papules and plaques of varying sizes ranging from 2-8 cm in diameter. At places, papules were coalescing to form plaques. The extensor aspect of the knees and elbows showed multiple psoriasiform plaques with scaling; however, the borders of the plaques showed infiltration in contrast to plaques of psoriasis vulgaris (Figure 1). The Auspitz sign was negative. Dorsa of both hands showed dusky to brownish annular plaques with central clearing and atrophic wrinkling of the skin. Dorsa of both feet showed brownish plaques extending onto the side of the feet and some of the toes. There were multiple plaques on the forehead which showed a central

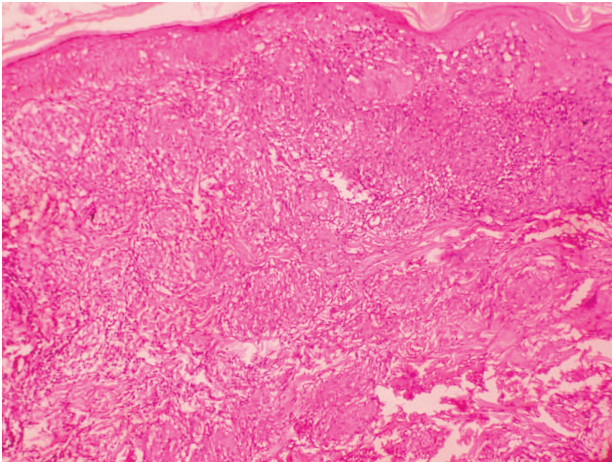


Figure 1. Well-defined erythematous plaques with minimal scaling on knees and elbows resembling plaques of psoriasis.

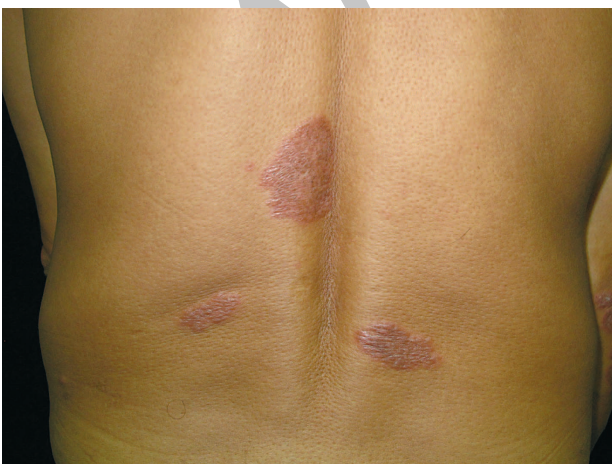

Figure 2. Well defined brown colored infiltrated plaques with 'peau d' orange' appearance.

hypopigmented atrophic zone. Lesions on the lower back showed a granulomatous morphology with a 'peau d' orange' appearance. (Figure 2) The rest of the examination of the oral cavity and genitalia did not show any abnormalities. There was no evidence of any peripheral nerve trunk enlargement or lesional loss of sensation. Deep dermal tenderness (Buschke Ollendorff sign) was not present. We considered a differential diagnosis of psoriasis vulgaris, psoriasiform sarcoidosis, and borderline lepromatous Hansen's disease.

His complete hemogram was normal (hemoglobin-13.7g/dl; total white blood cell count- $4.2 \times 10^3/\mu\text{l}$; platelet- $133 \times 10^6/\mu\text{l}$). Blood biochemistry showed fasting (178mg/dl) and post-prandial hyperglycemia (168mg/dl) and raised delta fraction of serum bilirubin- $3.59 \mu\text{mol/L}$ (normal range: 0.00-3.42), while the rest of the renal and hepatic parameters were within normal limits. Serum calcium was 8.9gm/dl. Serum levels of angiotensin converting enzyme (ACE) were elevated on two occasions: 96.00 U/L (February 2009) and 103.00 U/L (June 2011) with the normal reference value being 8.00-52.00 U/L. Stool and routine urinalysis did not show any abnormalities. Serology for HIV, syphilis, hepatitis A, hepatitis B and hepatitis C was negative. Abdominal ultrasound showed grade II fatty infiltration of the liver and moderate splenomegaly of 13.3 centimeters. Electrocardiogram (ECG) showed a normal sinus rhythm. Chest roentgenogram showed multiple reticulo-nodular opacities and fibrotic changes in the right middle zone and left upper zone (Figure 3). High Resolution

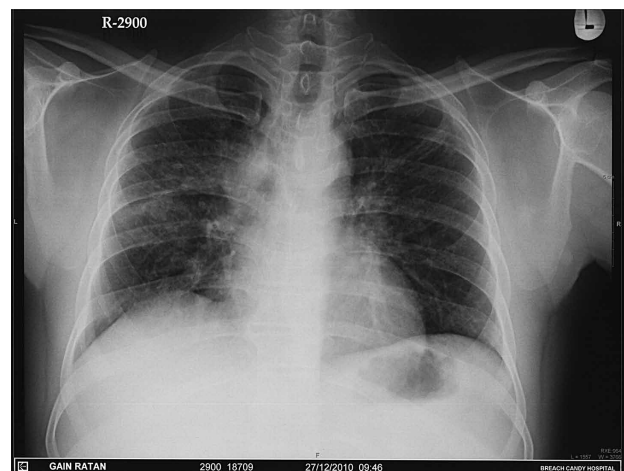


Figure 3. Chest X ray showing reticulonodular opacities in the both the lung fields with fibrosing alveolitis.

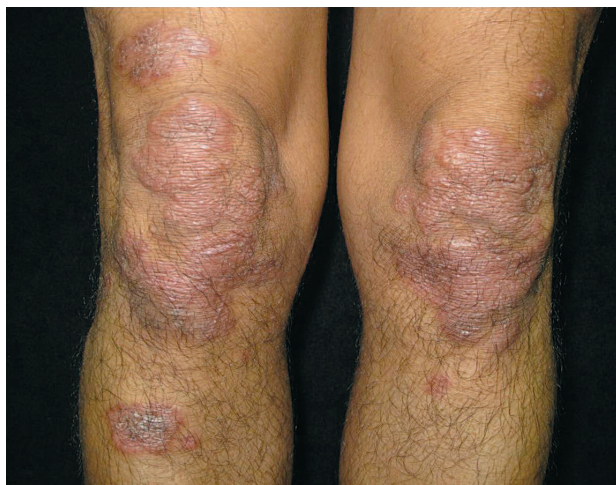

Figure 4. Computed tomography of the chest showing interstitial fibrotic changes in both the lungs fields.

Computed Tomography (HRCT) of the chest showed pretracheal, subcarinal and hilar lymphadenopathy, cystic spaces, reticulonodular opacities and interstitial fibrosis (Figure 4). Pulmonary function test showed a restrictive pattern with reduced Forced Vital Capacity (FVC) and normal FEV 1. Ocular examination did not reveal any signs of uveitis. The patient did not give consent for broncho-alveolar lavage.

A punch biopsy from the lesion stained with haematoxylin and eosin showed multiple non-caseating granulomas in the upper dermis with foci of multinucleated giant cells without any peripheral rim of lymphocytes (Figure 5). Fite-Faraco stain and Gomori-methenamine silver stain was negative for acid-fast bacilli and fungal elements, respectively.

The patient was started on oral steroids (50 mg of prednisolone) and hydroxychloroquine 200 mg twice daily with resolution of the lesions, followed by gradual tapering of steroid. The patient is still on tapering doses of steroid and is in remission.

DISCUSSION

Sarcoidosis may be acute or chronic. Acute sarcoidosis has an abrupt onset, is more frequent in Caucasians, and may present as Löfgren’s syndrome which is characterized by bilateral hilar adenopathy, ankle arthritis, erythema nodosum, and frequently constitutional symptoms including fever, myalgia, malaise and weight loss. The prognosis is good and spontaneous remission usually occurs within two

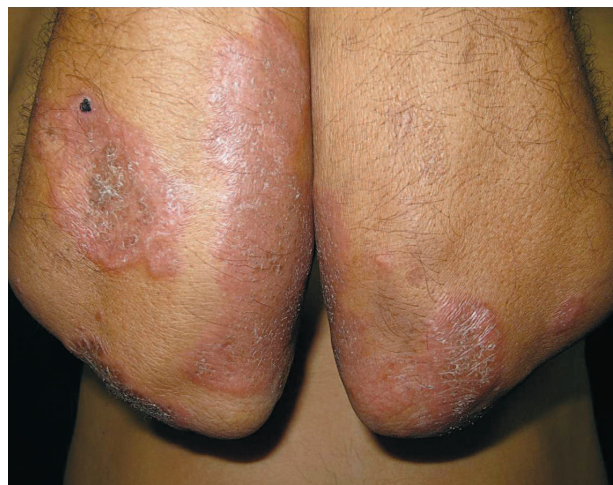

Figure 5. Haematoxylin & Eosin stained section of skin biopsy showing chronic granulomatous infiltrate with multiple non-caseating epithelioid cell granulomas without peripheral rim of lymphocytes in the papillary dermis. (x100)

to three years. Chronic sarcoidosis has an insidious onset. Organ-related symptoms - often related to pulmonary infiltration such as coughs and dyspnea - predominate whereas constitutional symptoms are much rarer as compared to the acute form. Our patient presented with chronic sarcoidosis with a seven-year history of multiple specific lesions of cutaneous sarcoidosis with underlying pulmonary involvement in the form of mediastinal lymphadenopathy and fibrotic changes in the lung parenchyma. Depending upon the morphologic presentations, cutaneous sarcoidosis can be divided in the following types (Table 1).

Our patient had a long-standing history of breathlessness on exertion; however, his breathlessness did not improve on bronchodilator

Table 1. Classification of cutaneous sarcoidosis lesions

Specific lesions	Non specific
Papular sarcoidosis (miliary sarcoid)	Erythema nodosum
Annular sarcoidosis	Prurigo
Hypopigmented sarcoidosis	Calcifications
Ichthyosiform sarcoidosis	Erythema multiforme
Psoriasiform sarcoidosis	
Morpheaform sarcoidosis ⁶	
Subcutaneous sarcoidosis (DarierRoussy sarcoid)	
Scar sarcoid ⁷	
Erythrodermic sarcoidosis ⁸	
Lupus pernio	
Ulcerative sarcoidosis ⁹	
Lichenoid	

therapy. After the appearance of skin lesions and appropriate laboratory work-up (ACE levels, skin biopsy and pulmonary function tests), we made the diagnosis of sarcoidosis. Surprisingly, our patient had not sought any medical advice for his dermatological problem due to its non-troublesome nature. Consistent with other case series,¹⁰ the predominant lesions in our patient were of plaque type. Psoriasiform sarcoidosis occurs when the granulomatous pathology affects the epidermis and clinically resembles psoriatic plaques with scaling. Psoriasiform eruptions are found in 0.9% of cases of sarcoidosis.¹¹ Specific lesions are reported to be associated with multisystem involvement and disease that is more progressive.¹⁰ The diagnosis of sarcoid depends on: (i) clinical evidence of a multisystem disease or a radiological picture or both, (ii) histologic evidence of non-caseating granulomas, and (iii) negative cultures of sputum and tissues.¹²

Sarcoidosis of the lung has been classified radiologically into four stages:

Stage 0: 5-10% of the patients with sarcoidosis have a normal chest X ray.

Stage 1: Bilateral hilar lymphadenopathy in 35-45% of the cases.

Stage 2: Bilateral hilar lymphadenopathy with parenchymal lung involvement of the fluffy and coarse type.

Stage 3: Late stage of pulmonary infiltration with fibrosis and pulmonary insufficiency.

The pathogenesis of sarcoidosis is believed to be a host immune response to an unknown antigenic stimulus. Antigen-capturing by immature dendritic cells (DCs) takes place initially in the epidermis, followed by maturation of DCs. These mature DCs may present the processed environmental antigen to cortical T-lymphocytes that cause dermal granulomas either in the interstitium of the upper dermis, or in or around lymphatic vessels of the lower dermis.¹³ Various microbial

and environmental antigens have been postulated as mentioned in Table 2.¹⁴

Granulomatous inflammation of sarcoidosis is suggestive of heightened immunity but paradoxically, sarcoidosis patients exhibit cutaneous anergy to tuberculin and other intradermal skin tests except for the Kveim-Siltzbach test. This cutaneous anergy could be because of peripheral lymphopenia and decreased activation of T-cells.¹⁸

At present, corticosteroids remain the 'gold standard' therapy for sarcoidosis and are indicated for progressive pulmonary disease, distressing cutaneous involvement and threatening organ involvement such as the eye, central nervous system and cardiac involvement. However, corticosteroid therapy does not provide long-term remission and is associated with many side effects precluding its long term administration.¹⁹ Other drugs which have been tried in sarcoidosis are cyclosporine A,²⁰ methotrexate,²¹ cyclophosphamide, thalidomide,^{22,23} mycophenolate mofetil,²⁴ TNF alpha antagonist²⁵ and allopurinol.²⁶ Recently, Mizoribine, a purine synthesis inhibitor, was used in a single patient at a dose of 150 mg/day; however, the drug is associated with severe adverse effects like nephrotoxicity, gonadal failure and bone marrow suppression.²⁷

To summarize, one should always look for this great mimicker and keep the differential diagnosis of sarcoid in mind even when dealing with common dermatoses showing unusual features.

REFERENCES

- Pandhi D, Sonthalia S, Singal A. Mortimer's Malady revisited: A case of polymorphic cutaneous and systemic sarcoidosis. *Indian J Dermatol Venereol Leprol* 2010;76:448
- English JC III, Patel PJ, Greer KE. Sarcoidosis. *J Am Acad Dermatol* 2001; 44: 725-43.
- Kang MJ, Kim HS, Kim HO, Park YM. Cutaneous sarcoidosis presenting as multiple erythematous macules

Table 2. Microbiological and environmental agents implicated in pathogenesis of sarcoid.

Infectious agents		Environmental agents/drugs
Bacterial	Viral	
<i>Mycobacterium tuberculosis</i>	Human herpes virus (HHV8)	Organic agents (e.g. pollen)
<i>Non tuberculous mycobacteria</i>	Ebstein-Barr virus	Inorganic agents (e.g. soil, aluminium, zirconium, clay,)
<i>Propionibacterium</i>	Hepatitis C virus (HCV)	copper ¹⁵
<i>Chlamydia pneumonia</i>	Rotavirus	Interferon alpha ¹⁶
<i>Borrelia burgdoferi</i>		Adalimumab ¹⁷

- and patches. *Ann Dermatol* 2009; 21:168-170.
4. Marchell RM, Judson MA. Chronic cutaneous lesions of sarcoidosis. *Clin Dermatol*. 2007; 25: 295–302
 5. Yanardag H, Pamuk ON, Karayel T. Cutaneous involvement insarcoidosis: analysis of the features in 170 patients. *Respir Med*. 2003; 97: 978–82.
 6. Choi SC, Kim HJ, Kim CR, Byun JY, Lee DY, Lee JH, et.al. A case of morpheaform sarcoidosis. *Ann Dermatol*. 2010;22:316-8
 7. Mantese SA, Berbert AL, Cesário TS, Silva HB. Sarcoidosis on skin scars: a case report. *An Bras Dermatol*. 2010 ;85:903-5.
 8. Acciai MC, Mori M, Cappugi P. [Erythrodermic sarcoidosis]. *G Ital Dermatol Venereol*. 1990;125:475-7.
 9. Meyersburg D, Schön MP, Bertsch HP, Seitz CS. [Uncommon cutaneous ulcerative and systemic sarcoidosis. Successful treatment with hydroxychloroquine and compression therapy]. *Hautarzt*. 2011;62:691-5
 10. Marcoval J, Mañá J, Rubio M. Specific cutaneous lesions in patients with systemic sarcoidosis: relationship to severity and chronicity of disease. *Clin Exp Dermatol*. 2011;36:739-44.
 11. Sakemi H, Oiwa H. Psoriasiform Plaques of Sarcoidosis. *Intern Med*. 2009;48:391.
 12. Mittal RR, Singh SP, Gill SS. Psoriasiform sarcoidosis associated with depigmentation. *Indian J Dermatol Venereol Leprol* 1996;62:103-5
 13. Kurata A, Terado Y, Izumi M, Fujioka Y, Franke FE. Where does the antigen of cutaneous sarcoidosis come from? *J Cutan Pathol*. 2010;37: 211-21
 14. Ali MM, Atwan AA, Gonzalez ML. Cutaneous sarcoidosis: updates in the pathogenesis. *J Eur Acad Dermatol Venereol*. 2010;24:747-55
 15. Masel G. Copper-induced cutaneous sarcoidosis. *Australas J Dermatol*. 2005;46:38-41.
 16. Lee YB, Lee JI, Park HJ, Cho BK, Oh ST. Interferon-alpha Induced Sarcoidosis with Cutaneous Involvement along the Lines of Venous Drainage. *Ann Dermatol*. 2011;23:239-41
 17. Marcella S, Welsh B, Foley P. Development of sarcoidosis during adalimumab therapy for chronic plaque psoriasis. *Australas J Dermatol*. 2011;52:e8-11.
 18. Noor A, Knox KS. Immunopathogenesis of sarcoidosis. *Clin Dermatol* 2007; 25: 250–258.
 19. Lodha S, Sanchez M, Prystowsky S. Sarcoidosis of the skin: a review for the pulmonologist. *Chest*. 2009;136:583-96.
 20. Wyser CP, van Schalkwyk EM, Alheit B, Bardin PG, Joubert JR. Treatment of progressive pulmonary sarcoidosis with cyclosporin A. A randomized controlled trial. *Am J Respir Crit Care Med* 1997; 156: 1371–1376.
 21. Baughman RP, Winget DB, Lower EE. Methotrexate is steroid sparing in acute sarcoidosis: results of a double blind, randomized trial. *Sarcoidosis Vasc Diffuse Lung Dis*. 2000;17:60–66.
 22. Hammond ER, Kaplin AI, Kerr DA. Thalidomide for acute treatment of neurosarcoidosis. *Spinal Cord*. 2007;45:802-3
 23. Yasui K, Yashiro M, Tsuge M, Manki A, Takemoto K, Yamamoto M, et.al. *Arthritis Rheum*. 2010;62:250-7.
 24. Kouba DJ, Mimouni D, Rencic A, Nousari HC. Mycophenolate mofetil may serve as a steroid-sparing agent for sarcoidosis. *Br J Dermatol* 2003; 148: 147–148.
 25. Ulbricht KU, Stoll M, Bierwirth J, Witte T, Schmidt RE. Successful tumor necrosis factor alpha blockade treatment in therapy-resistant sarcoidosis. *Arthritis Rheum*. 2003 ;48:3542-3.
 26. Gautam M, Patil S, Munde P. Skin as a marker of internal disease: A case of sarcoidosis. *Indian J Dermatol* 2011;56:439-41
 27. Kawakami T, Soma Y. Successful Use of Mizoribine in a Patient with Sarcoidosis and Cutaneous Vasculitis. *Acta Derm Venereol*. 2011;91:582-3.