

Isolated cutaneous Crohn's disease: A case report

Mohammad Javad Zahedi, MD¹
 Alireza Fekri, MD^{2,3}
 Azadeh Rezazadeh, MD²
 Mahmood Moosazadeh, PhD⁴
 Mehran Karvar⁵

1. Department of Internal Medicine, Kerman University of Medical Sciences, Kerman, Iran
2. Department of Dermatology, Kerman University of Medical Sciences, Kerman, Iran
3. Leishmaniasis Research Center, Kerman University of Medical Sciences, Kerman, Iran
4. Health Sciences Research Center, Mazandaran University of Medical Sciences, Sari, Iran
5. School of Medicine, Kerman University of Medical Sciences, Kerman, Iran

Corresponding Author:
 Azadeh Rezazadeh, MD
 Department of Dermatology, Kerman University of Medical Sciences, Kerman, Iran
 Email: azadehrezazadeh1384@gmail.com

Conflict of interests: None to declare

Received: 10 January 2015
 Accepted: 24 February 2015

This case report describes a patient with cutaneous signs in the genital and peri-anal region suspicious of Crohn's disease without any intestinal symptom or sign. Inflammatory bowel disease can be associated with some cutaneous signs. However, in this paper, we report a patient with isolated cutaneous Crohn's disease which is very rare (less than 100 case reports across the world). Our patient presented with inflammatory indurated plaques and sinuses in the genital region since 3 years ago. Colonoscopy showed no findings related to Crohn's disease in the ascending, sigmoid, and descending colon, particularly the terminal ileum. The patient's symptoms were relieved following treatment with infliximab. To the best of our knowledge, this is the first report of isolated cutaneous Crohn's disease in Iran.

Keywords: Crohn's disease, cutaneous, infliximab

Iran J Dermatol 2015; 18: 174-178

INTRODUCTION

Crohn's disease is a granulomatous and inflammatory intestinal disease which can affect any part of the gastro-intestinal tract, especially the terminal ileum (> 80%) or ileocolonic region. Endoscopic imaging and mucosal biopsy are needed for a diagnosis^{1,2}.

It can cause intestinal and extra-intestinal (muco-cutaneous) symptoms and signs. The most common cutaneous sign is the fistula that is mostly found on the perianal region skin³. To evaluate

this common picture, there is an activity index (a functional index) which evaluates the fistula discharge, pain, induration, etc.⁴.

Cutaneous Crohn's disease is a very rare disease which is defined as the cutaneous manifestation of inflammatory bowel disease. It has mucocutaneous manifestations that we will discuss later. It is observed more in women than in men with a mean age of onset of 35 years. However, there are some reports of cutaneous Crohn's disease in children (less than 20 cases). The cutaneous involvement can be either contiguous or non-contiguous (metastatic),

and genital involvement is more common than extra-genital signs⁵.

Metastatic Crohn's disease is more related to cases of intestinal (colonic) involvement but is not actually related to the intestinal disease activity. However, cutaneous Crohn's disease can occur even without gastrointestinal tract manifestations or may even precede it⁶. It has been thought that cutaneous Crohn's disease is due to antigens or immune complexes derived from the gastrointestinal tract due to primary Crohn's disease⁷. Herein, we report a case without any evidence of gastrointestinal tract manifestations.

CASE REPORT

The patient was a 48-year-old woman suffering painful lesions in the pubic area and genitalia since 3 years ago after a hemorrhoidectomy. On physical examination, extensive erythematous skin involvement and indurated polypoid plaques were found in the perineum, labia, bilateral inguinal region, and peri-anal and pubic areas. Some lesions had discharge. A bulging mass with fistulae and discharge was observed in the right side of the inguinal and perianal region. There was a cobblestone plaque on the hard palate, but no ulcerative or aphthous lesions were seen (Figures 1 and 2).

One year prior to be admitted to our hospital, she was hospitalized and was treated with drugs such as oral prednisolone, metronidazole, rifampicin, doxycycline, mesalazine, and azathioprine with a diagnosis of cutaneous Crohn's disease, but her

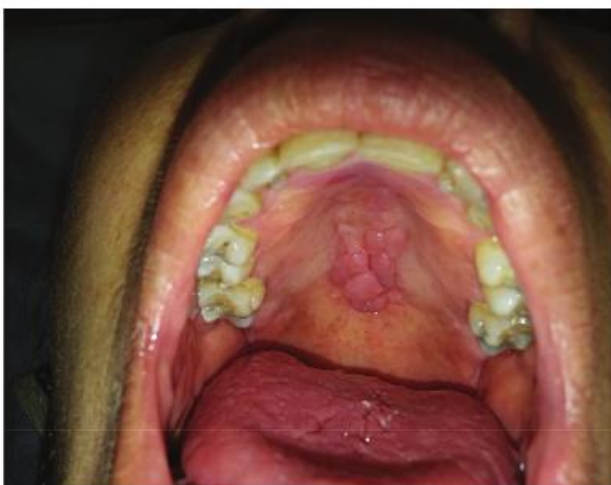

Figure 1. The cobblestone pattern in the mouth.

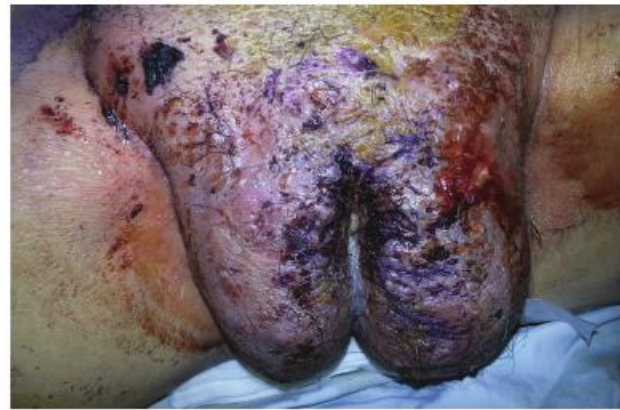

Figure 2. An indurated erythematous plaque in the genitalia.

symptoms did not resolve.

At the time of admission in our hospital, she had a fever and had lost 10 Kg. She had no gastrointestinal or genitourinary tract symptoms.

Her laboratory data were as follows: blood sugar=251 mg/dL, HbA1C=14.2 %, ESR=64 mm/h.

Stool examination results showed: red blood cell (RBC)=20, white blood cell (WBC)=18, and 1+ of blood. Urinalysis result showed: WBC=18, 3+ of sugar, and 3+ of ketones. It was negative for protein. Anti-*Saccharomyces cerevisiae* antibodies (ASCA) was 16.4 U (normal < 16 U).

Renal and liver function tests were unremarkable. Serology for HIV, hepatitis B and C, fluorescent antinuclear antibody (FANA), and anti neutrophil cytoplasmic antibodies (ANCA) were negative.

Differential diagnoses were: cutaneous Crohn's disease, necrobiosis lipoidica, staphylococcal botryomycosis, tuberculosis, deep fungal infection (actinomycosis, blastomycosis, mucormycosis), sarcoidosis, extra mammary Paget's disease, cutaneous B or T cell lymphoma, granuloma inguinale, hidradenitis suppurativa, foreign body reaction, and extra facial seycosis.

To rule out tuberculosis, a chest x-ray, purified protein derivative (PPD) test, sputum smear and culture; and PCR for detecting *Mycobacterium tuberculosis* were ordered and the results of all of them were negative.

To rule out sarcoidosis, a skin biopsy was performed and an angiotension converting enzyme (ACE) titer evaluation was requested; neither of them suggested sarcoidosis. Ultrasound examination of the uterus, ovaries, and abdomen was normal. Pelvic x-ray and MRI were also unremarkable.

Skin culture showed *Staphylococcus A* colonization.

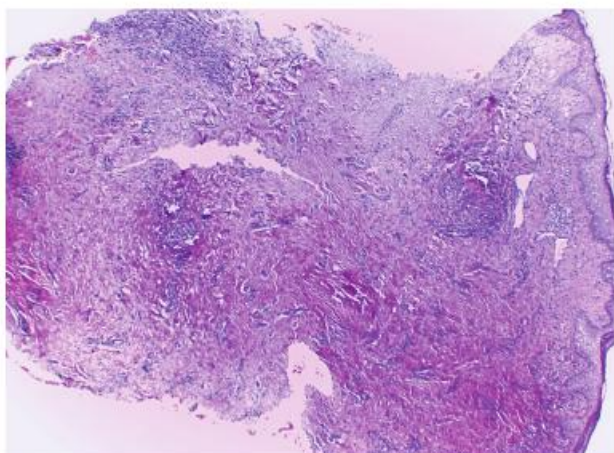


Figure 3. Focal acanthosis of intact epidermis. Upper, mid, and deep dermis show multifocal lymphohistiocytic cell infiltrates (H & E, ×40).

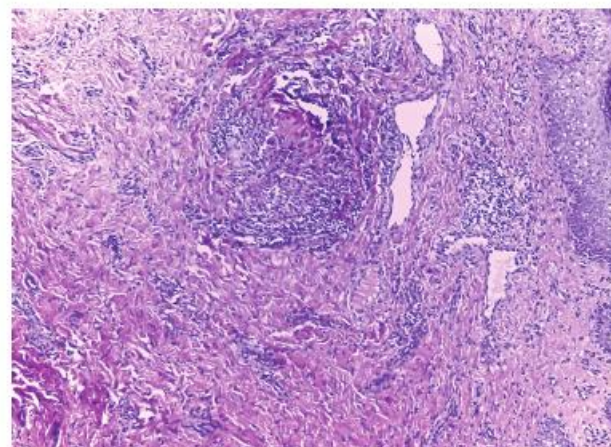


Figure 4. Granuloma collection in upper dermis composed of lymphocytes and histiocytes. Perivascular mononuclear cell infiltrates are noted (H & E, ×100).

Skin biopsy showed evidence of hidradenitis suppurativa, chronic granulomatous dermatitis, and collagen necrobiosis. Biopsy of the oral mucosa showed fibrosis. The biopsies ruled out deep fungal infections, extramammary Paget's disease, foreign body reaction, and cutaneous lymphoma.

Regarding extrafacial seycosis, we administered a treatment course with doxycycline and rifampin which offered no improvement, ruling out this diagnosis.

As hidradenitis suppurative may coexist with Crohn's proctocolitis, it makes the diagnosis and management of the patients complicated. Because neither the personal nor the family history of diabetes mellitus was positive, necrobiosis lipoidica was not considered a relevant diagnosis and her blood glucose elevation was attributed to the side effect of prednisolone. Colonoscopy was done two times

but none showed any findings related to Crohn's disease in the ascending, sigmoid, or descending colon, particularly the terminal ileum; only non specific inflammation was reported on colonoscopy.

By ruling out all the differential diagnoses one by one, the only remaining diagnosis was cutaneous Crohn's disease which matched her clinical symptoms and skin biopsy.

Considering the fact that the patient had not responded to previous treatments, we prescribed infliximab (Remicade®). The symptoms resolved after 4 treatment sessions. The abscesses were also drained by a surgeon.

DISCUSSION

Cutaneous Crohn's disease is a rare condition (fewer than 100 case reports) that can occur

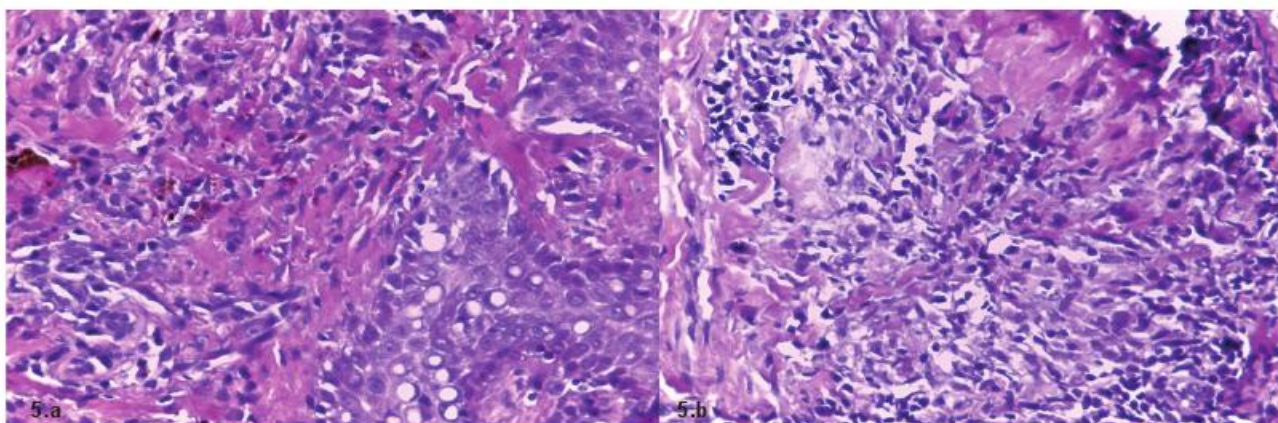


Figure 5. 5.a. Acanthotic epidermis along with perivascular and dermal collections of histiocytes and lymphocytes in the dermis. Hemosiderophages are dispersed between mononuclear cells. 5.b. High power view shows granulomatous infiltrate of histiocytes and lymphocytes in degenerated collagen bundles (H & E, ×400).

simultaneously with primary Crohn's disease or can precede it by about 3 months to 8 years; it means there are clinical cutaneous Crohn's manifestations without gastrointestinal signs and symptoms of Crohn's disease. Genital involvement is more common than extra-genital involvement.

The cutaneous signs in intestinal Crohn's disease are categorized as: (a) perineal and perianal involvement like erythema, edema, sinus, and fissure, (b) cutaneous reactions to intestinal Crohn disease such as pyoderma gangrenosum, pyostomatitis vegetans, erythema multiforme, erythema nodosum, hidradenitis suppurativa, and necrotizing and granulomatous small vessel vasculitis, and (c) metastatic non-caseating granuloma. Cutaneous Crohn's disease presents with erythematous papules and plaques on the trunk and extremities¹.

Oral lesions are more common in the pediatric population. Oral lesions have two types: pathognomonic lesions including cobblestoning of the oral mucosa, linear ulcerations of the oral vestibules, mucosal tags, and non-pathognomonic lesions including facial swelling, perioral erythema, angular cheilitis, aphthous stomatitis, pyostomatitis vegetans, diffuse oral edema, and hyperplastic granular gingivitis⁸.

The most common finding in children is genital involvement such as labial, penile, and scrotal swelling and erythema⁶. Regarding the signs of metastatic Crohn's disease between adults and children, there are some reports of the longer duration of lesions in adults⁹.

As for the etiology of cutaneous Crohn's disease, it is supposed that antigens or immune complexes originating from the gastrointestinal tract are responsible for these reactions; probably because they react to skin antigens of similar structure⁷.

Histologically, there are non-caseating and non-supportive granulomata in the superficial (often papillary) and even in the deep dermis. The granulomata are similar to those found in the bowel. Necrobiotic collagen has been reported in some cases. Perivascular and dermal infiltration such as lymphocytes, plasma cells, and eosinophils can be seen¹⁰.

There are some differences between the histologic findings of primary gastrointestinal and metastatic Crohn's disease. The lymphoplasmacytic infiltration in the mucosa of primary Crohn's disease can be heterogeneous and can be small patches or well-

circumscribed lymphoid aggregates while it has a diffuse pattern in the dermis and subcutis in metastatic Crohn's disease¹¹.

The differential diagnoses of genital lesions are lymphogranuloma venereum, lymphogranuloma inguinale, syphilis, hidradenitis suppurativa, actinomycosis, vulvar tuberculosis, sarcoidosis, local conditions including factitial dermatitis, intertrigo, deep atypical infections (viral, bacterial, or fungal) and Behçet's disease¹².

Oral metronidazole 250 mg three times daily with or without topical or intra-lesional corticosteroid is an effective treatment. Other systemic agents are oral corticosteroids, sulfasalazine, azathioprine, 6-mercaptopurine, and TNF- α inhibitors (e.g. infliximab and adalimumab)⁵.

TNF- α inhibitors are used when other treatments are not efficient. They are the newest method of treatment in cutaneous Crohn's disease. We treated our patient with infliximab because her symptoms did not resolve with the conventional treatments that she received two years ago.

Surgical excision is not advised because of post operative complications like wound dehiscence and disease recurrence⁵.

There are some reports on using hyperbaric oxygen treatment (HBOT) which involves inhaling 100% oxygen at greater than one atmosphere absolute (ATA) in a pressurized chamber. Studies have shown that this method improves symptoms in both human studies and animal models because HBOT decreases the concentration of proinflammatory cytokines, inflammatory biomarkers, and oxidative stress and upregulates the production of antioxidant enzymes¹³.

Also, the use of 0.1% tacrolimus ointment for the treatment of Crohn's disease, particularly perineal disease, has been reported effective although rapid relapses are seen when treatment is not maintained¹⁴.

ACKNOWLEDGEMENTS

We wish to thank Kerman Physiology Research Center for contributing to our investigations.

REFERENCES

1. Carbo AI, Reddy T, Gates T, et al. The most characteristic lesions and radiologic signs of Crohn disease of the small

- bowel: air enteroclysis, MDCT, endoscopy, and pathology. *Abdom Imaging* 2014;39:215-34.
2. Somma V, Ababneh H, Ababneh A, et al. The novel Crohn's disease marker anti-GP2 antibody is associated with ileocolonic location of disease. *Gastroenterol Res Pract* 2013;2013:683824.
 3. Schwartz DA, Loftus EV Jr, Tremaine WJ, et al. The natural history of fistulizing Crohn's disease in Olmsted County, Minnesota. *Gastroenterology* 2002;122:875-80.
 4. Gecse K, Khanna R, Stoker J, et al. Fistulizing Crohn's disease: Diagnosis and management. *United European Gastroenterol J* 2013;1:206-13.
 5. Reisenauer A, White KP, Korcheva V, White CR Jr. Non-infectious granulomas. In: Bologna JL, Jorizzo JL, Schaffer JV, editors. *Dermatology*. 3rd Ed. New York: Elsevier Saunders; 2012:1553-72.
 6. Panackel C, John J, Krishnadas D, et al. Metastatic Crohn's disease of external genitalia. *Indian J Dermatol* 2008;53:146-8.
 7. Siroy A, Wasman J. Metastatic Crohn disease: a rare cutaneous entity. *Arch Pathol Lab Med* 2012;136:329-32.
 8. Fatahzadeh M, Schwartz RA, Kapila R, et al. Orofacial Crohn's disease: an oral enigma. *Acta Dermatovenerol Croat* 2009;17:289-300.
 9. Palamaras I, El-Jabbour J, Pietropaolo N, et al. Metastatic Crohn's disease: a review. *J Eur Acad Dermatol Venereol* 2008;22:1033-43.
 10. Luzar B, Calonje ED. Granulomatous, necrobiotic and perforating dermatoses. In: Calonje ED, Brenn TH, Lazar AL, McKee P, editors. *McKee's pathology of the skin*. 4th Ed. New York: Elsevier; 2012: 309.
 11. Greenson JK, Odze RD. Inflammatory diseases of larger intestine. In: Odze, RD; Goldblum, JR, editors. *Surgical pathology of the GI tract, liver, biliary tract and pancreas*. 2nd Ed. New York: Elsevier; 2009: 364-8.
 12. Corbett SL, Walsh CM, Spitzer RF, et al. Vulvar inflammation as the only clinical manifestation of Crohn disease in an 8-year-old girl. *Pediatrics* 2010;125:e1518-22.
 13. Rossignol DA. Hyperbaric oxygen treatment for inflammatory bowel disease: a systematic review and analysis. *Med Gas Res* 2012;2(1):6.
 14. Rice SA, Woo PN, El-Omar E, et al. Topical tacrolimus 0.1% ointment for treatment of cutaneous Crohn's Disease. *BMC Res Notes* 2013;6:19.