

Conservative Treatment of a Radicular Cyst Associated with a Primary Mandibular Molar

H. Afshar¹, Z. Baniameri²✉

¹ Associate Professor, Department of Pediatric Dentistry, School of Dentistry, Tehran University of Medical Sciences, Tehran, Iran

² Pedodontist, Taleghani Hospital, Gonbad, Iran

Abstract

Introduction: Radicular cysts (RCs) are the most common odontogenic cystic lesions with an inflammatory origin. Radicular cysts originate from epithelial remnants of the periodontal ligament as a result of inflammation, which is generally a consequence of pulp necrosis. Dental caries is the most common etiology of RCs and they are most commonly reported in primary mandibular molars. Treatment options include root canal therapy, extraction and surgery.

Case Presentation: A 10.5 year-old patient presented to the Pediatric Dentistry Department of Tehran University of Medical Sciences (TUMS) with a RC associated with a primary mandibular second molar. We performed non-surgical conservative treatment by extracting the involved tooth. After two years of follow up, the lesion healed and the second premolar erupted.

Key Words: Radicular Cyst, Tooth, Deciduous, Molar, Infection

✉ Corresponding author:
Z. Baniameri, Pedodontist,
Taleghani Hospital, Gonbad,
Golestan

yaldabaniameri@yahoo.com

Received: 25 July 2015

Accepted: 28 Feb 2016

Journal of Islamic Dental Association of IRAN (JIDAI) Autumn 2015 ;27, (4)

Introduction

Radicular cyst is the most common inflammatory odontogenic cyst originating from the epithelial remnants of periodontal ligament (epithelial cell rests of Malassez) following pulp necrosis [1]. Radicular cyst, also known as periapical cyst, dental cyst, apical cyst and apical periodontal cyst [2], is not common in the first decade of life. Instead, it is most frequent in the third decade of life. Its prevalence rate in permanent dentition period is 7 to 54% while it is rare in primary dentition period with a prevalence of 0.5-3.3% [3]. It is more prevalent in males [2]. Dental caries is the most common etiology for development of RC but it may also develop secondary to traumatic

injuries [4]. Primary mandibular molars have the highest prevalence of RC while its occurrence in incisors is extremely rare. In permanent dentition period, maxilla is more commonly affected [5,6]. Radicular cysts are often seen in the periapical region but they can also develop lateral to the roots due to the presence of accessory canals [1]. These cysts contain fibrous connective tissue, fluid and cell residues with an epithelial lining. By desquamation of epithelium in the lumen, its protein content increases. Thus, in order to balance the osmotic pressure, fluids enter into the lumen from the surrounding connective tissue, and the cyst gradually expands with no specific symptom unless secondary infection occurs. If so, signs and

symptoms of infection are detectable depending on its acute or chronic nature [2]. Radicular cyst in primary teeth can cause bone resorption or swelling, displacement of adjacent teeth, root resorption of affected tooth, delayed eruption of permanent teeth, improper positioning of permanent teeth or permanent enamel defects [7]. Treatment for an inflammatory periapical lesion includes root canal treatment or extraction of affected tooth. In case of presence of radicular cyst, enucleation, marsupialization or a combination of both is performed. Selection of each of this approaches depends on the size of lesion, its location, integrity of bone surrounding the lesion and its proximity to critical structures and landmarks. If proper treatment is performed, the lesion is very unlikely to recur [8]. This case report aims to describe a conservative treatment modality for management of a RC associated with a primary mandibular molar tooth.

Case Report

A 10.5 year-old female presented to the Pediatric Dentistry Department of TUMS complaining of pain and swelling in the left side of the mandible. Patient's medical history was unremarkable. Clinical examination revealed extensive caries in the mandibular left primary second molar and swelling of the buccal gingiva and mucosa of the respective area with soft consistency.

Panoramic radiographic examination revealed a well-defined radiolucency apical to the mandibular left primary second molar causing displacement of the second premolar tooth bud towards distal and apical close to the border of the mandible (Figure 1). After consultation with the Pathology and Oral and Maxillofacial Surgery Departments, aspiration was performed from the buccal gingiva of the respective tooth. The buccal bone plate appeared to be thinned up to the buccal bone margin due to the presence of lesion.

A yellow fluid was aspirated. Thus, vascular lesions were ruled out and it was confirmed that the lesion was a cyst. Considering the patient's age, size of lesion and involvement of the unerupted second premolar tooth bud, the left primary second molar tooth was extracted and marsupialization was somehow performed by extracting the tooth. The patient was requested to

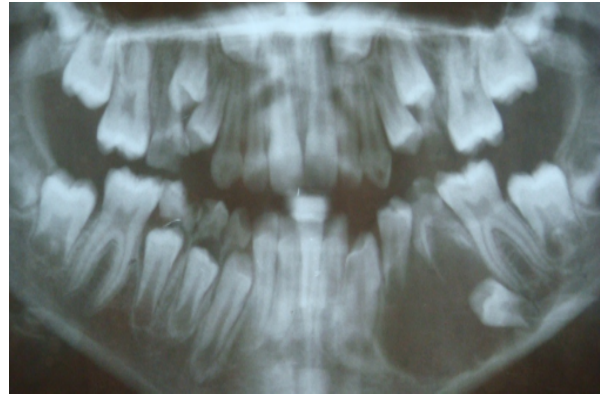


Figure 1. Primary panoramic radiograph

show up every four months for clinical and radiographic examinations. Regular follow ups revealed a reduction in size of the cyst in such a way that enucleation was no longer required. Considering the patient's age, intercuspation of permanent first molars and patient's full compliance to scheduled follow up visits, a space maintainer was not required. As seen in Figure 2, the anterior extension of the cyst decreased from the distal of canine to distal of second premolar. Figure 3 shows occlusal displacement of second premolar tooth bud. Figure 4 shows increased osteogenesis and decreased size of cyst (confined to the tooth bud of second premolar). Figure 5 shows further occlusal displacement of second premolar tooth bud and Figure 6 shows its location in the soft tissue. Eventually, the second premolar tooth erupted in its right path (Figure 7). Parents were informed about the dental treatment needs of their child; however, they did not consent to any further dental treatment due to financial issues.

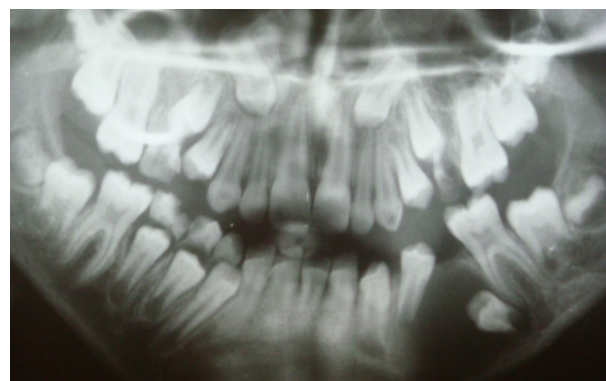

Figure 2. Panoramic radiograph taken four months after extraction of mandibular left primary second molar

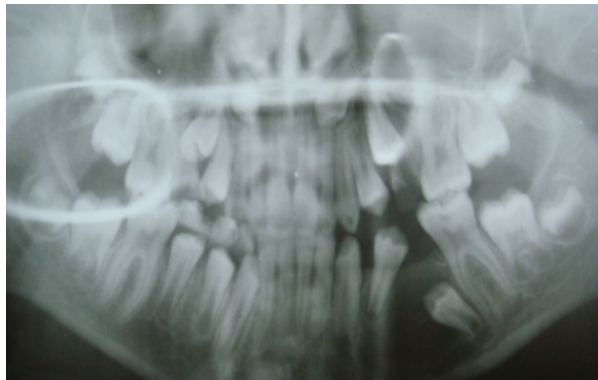


Figure 3. Panoramic radiograph taken eight months after extraction of mandibular left primary second molar

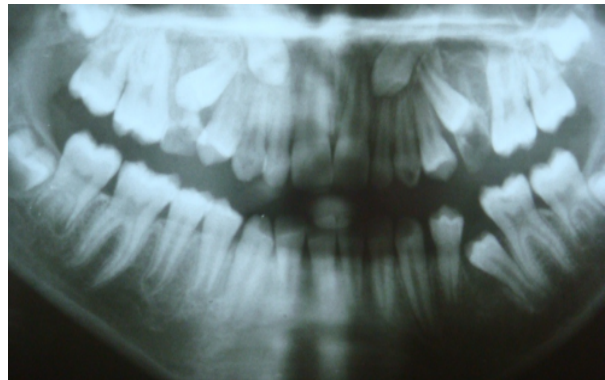


Figure 6. Panoramic radiograph taken 20 months after extraction of mandibular left primary second molar

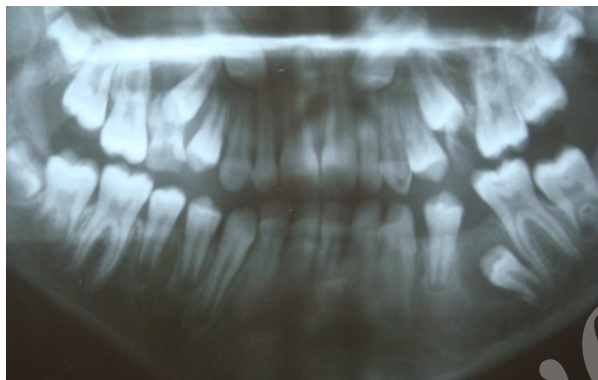


Figure 4. Panoramic radiograph taken 12 months after extraction of mandibular left primary second molar

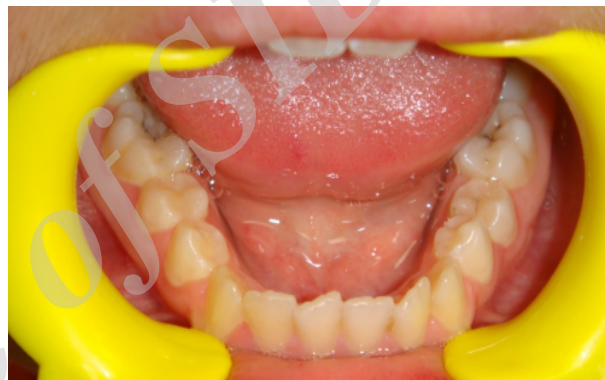

Figure 7. Intraoral clinical view 24 months after extraction of mandibular left primary second molar

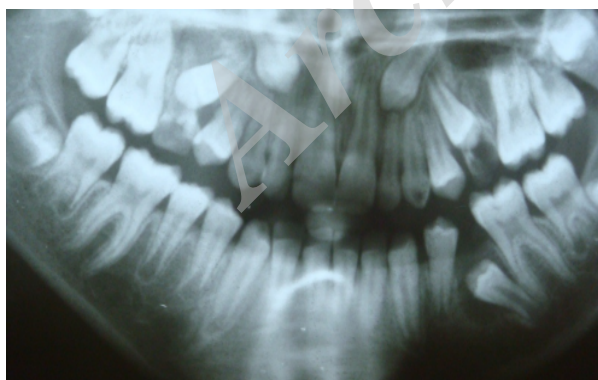

Figure 5. Panoramic radiograph taken 16 months after extraction of mandibular left primary second molar

Discussion

Radicular cyst is rare in primary dentition due to easier drainage compared to permanent teeth [4]. Another reason for low prevalence of RCs in primary dentition in contrast to permanent teeth is the extraction of primary teeth associated with the cyst without histopathological analysis. Most of these cysts are asymptomatic and are only detected radiographically [3]. Pulp therapy of involved teeth does not have a good prognosis [9] and is influenced by several factors including the curvature of root canals, presence of accessory canals and root resorption. In some cases, after pulp treatment, inflammation of the pulp and periradicular tissues continues asymptotically.

Thus, long-term follow up of such cases is necessarily required [10].

Periapical radiolucencies of primary teeth are included in the list of differential diagnoses of periapical granuloma, dentigerous cyst and enlarged follicle with developing permanent tooth bud. Dentigerous cyst is a well-defined unilocular radiolucency in the pericoronal space of an unerupted permanent tooth and its margins extend to the cemento-enamel junction of permanent tooth. Enlarged follicle with developing permanent tooth manifests in the form of a homogenous radiolucency with a thin opaque border at the periphery. However, it carries the risk of cystic changes. Thus, pericoronal space larger than 2.5mm on intraoral radiographs or more than 3mm on panoramic radiographs must be further scrutinized. Common symptoms of RCs include buccal cortex swelling, thinning of wall, well-defined radiolucency and displacement of permanent tooth bud [11,12]. On the other hand, carious lesions often develop in primary molars at the age of four to five years and if left untreated, necrosis of the pulp occurs. If they are not extracted, they may remain in the dental arch for the next five to six years, which appears to be long enough for the formation of RC, which has a growth rate of 5mm per year [13].

In our patient, after ruling out vascular lesions with the help of aspiration and noticing the yellow fluid, periapical and dentigerous cysts were first suspected. Considering the extensive carious lesion of mandibular left primary second molar tooth and the fact that root resorption of the adjacent teeth does not often occur due to dentigerous cyst, the most probable diagnosis was periapical cyst. The treatment plan for both types of cysts is almost the same with the exception that marsupialization followed by enucleation is performed for extensive dentigerous cysts because they carry a risk of ameloblastoma, mucoepidermoid carcinoma and odontogenic keratocyst and must be completely excised [14]. However, enucleation is associated with the risk of damage to permanent tooth buds while marsupialization decreases the pressure of the cyst and does not damage permanent tooth buds [15]. Thus, for our patient, carious primary second molar was extracted and marsupialization was performed as such. The greatest drawback of

marsupialization is the inability to perform histopathological analysis and thus, regular visits are required for irrigation and clinical examination [16]. Our patient had good cooperation and regularly showed up for the follow up visits. Also, the patient regularly used saline as mouthwash at home. Regular follow ups revealed gradual but complete elimination of lesion and the premolar teeth erupted in their correct path and position.

References

1. Shear M, Speight P. Radicular and residual cysts. In Cysts of the oral and maxillofacial regions. 4th ed. John Wiley and sons; 2008:123-43.
2. Varma Penumatsa N, Nallanchakrava S, Muppa R, Dandempally A, Panthula P. Conservative approach in the management of radicular cyst in a child: Case report. Case Rep Dent. 2013; 123-148.
3. Ramakrishna Y, Verma D. Radicular cyst associated with a deciduous molar: A case report with unusual clinical presentation. J Indian Soc Pedod Prev Dent. 2006 Sept; 24(3):158-60.
4. Delbem AC, Cunha RF, Vieira AE, Pugliesi DM. Conservative treatment of radicular cyst in 5 year old child: A case report. Int J Paediat Dent. 2003 Nov; 13(6):447-50.
5. Mass E, Kaplan I, Hirshberg A. A clinical and histopathological study of radicular cysts associated with primary molars. J Oral Pathol Med. 1995 Nov; 24(10):458-461.
6. Smith AT, Cowpe JG. Radicular cyst arising from a traumatized primary incisor: a case report of a rare complication that emphasizes the need for regular follow up. Dent Update. 2005 Mar; 32(2): 109-110.
7. Mc Tighe DJ, Nowak AJ, Fields HW, Casamassimo PS. Pediatric Dentistry: Infancy through Adolescence. 5th ed. Missouri: Elsevier; 2013, 45.
8. Bonder L. Cystic lesions of the jaws in children. Int J Pediatr Otorhinolaryngol. 2002 Jan; 62(1):25-9.
9. Yawaka Y, Kaga M, Osanai M, Fukui A, Oguchi H. Delayed eruption of premolars with periodontitis of primary predecessors and a cystic lesion: A case report. Int J Paediatr Dent. 2002 Jan; 12(1):53-60.
10. Patchett CL, Srinivasan V, Waterhouse PJ. Is there life after buckley's formocresol? Part 2-

Development of a protocol for the management of extensive caries in the primary molar. *Int J Pediat Dent.* 2006 May; 16(3):199-206.

11. Johann AC, Gomes Cde O, Mesquita RA. Radicular cyst: A case report. *J Clin Pediat Dent.* 2006 Fall; 31(1):66-7.

12. Farah CS, Savage NW. Pericoronal radiolucencies and significance of early detection. *Aust Dent J.* 2002 Sept; 47(3):262-265.

13. Lustmann J, Shear M. Radicular cysts arising from deciduous teeth. *Int J Oral Surg.* 1985 Apr;

14(2):153-161.

14. Wood NK, Goaz PW. Differential diagnosis of oral lesions. 5th ed. St. Louis; Mosby; 1997, 274.

15. Lall AB, Arora R. Coincidental Overlapping Cystic Pathological Changes: A Case against Marsupialisation. *J Maxillofac Oral Surg.* 2013 June; 12(2):214-217.

16. Aslan M, Aras MH, Simsek G, Dayi E. Large dentigerous cyst and radicular cyst of the mandible (case report). *Dis Hek Fak Derg Cilt.* 2006 Jan; 16 (1):54-8.