

A Comparative Study of Immunohistochemical Expression of BAX Protein in Radicular Cyst and Keratocystic Odontogenic Tumor

SH. Nafarzadeh¹, AR. Sarrafan², H. Abbaszade Bidokhti³, H. Gholinia⁴.

¹ Assistant Professor, Department of Oral and Maxillofacial Pathology, School of Dentistry, Babul University of Medical Sciences, Babul, Iran

² Dental Student, Member of Research Committee, School of Dentistry, Babul University of Medical Sciences, Babul, Iran

³ Member of Dental Material Research Center, School of Dentistry, Babul University of Medical Sciences, Babul, Iran

⁴ Health Research Institute, Babul University of Medical Sciences, Babul, Iran

Abstract

Background and Aim: Keratocystic odontogenic tumor (KCOT), formerly known as odontogenic keratocyst (OKC), is a developmental odontogenic cyst with an invasive behavior and high recurrence rate. Radicular cyst (RC) is an inflammatory non-invasive dental cyst, with no tendency to recurrence. Bcl2-associated X (BAX) protein acts as an apoptotic activator (pro-apoptotic protein), disrupts the integrity of mitochondrial membrane, and leads to the loss of outer membrane and release of cytochrome c from the inner membrane into the cytosol. Since KCOT is more aggressive and has a greater tendency to recurrence than RC, the aim of this study was to assess the immunohistochemical expression of BAX protein in the epithelial lining of RC and KCOT.

Materials and Methods: In this descriptive analytical study, paraffinized blocks of 17 RCs and 17 KCOTs fixed in 10% formalin were used (all KCOT samples were non-inflammatory and non-syndromic). After confirming the diagnoses by reviewing the slides, tissue specimens with sufficient length of epithelium were stained by immunohistochemistry (IHC) for BAX marker. Then, the stained cells were randomly counted in five high power fields. Analysis of the data was performed using SPSS 21 via Student's t-test and chi-test.

Results: Percentages of staining for BAX marker were 16.4±9.4% and 66.4±12.3% in the epithelial lining of KCOT and RC, respectively and there was a significant difference between them (P<0.001).

Conclusion: According to the findings, lower expression of BAX protein in KCOT justifies its more aggressive behavior and tendency to recurrence compared to RC.

Key Words: BAX protein, human, Odontogenic Cysts, Radicular Cyst, Immunohistochemistry

✉ Corresponding author:

AR. Sarrafan, Dental Student, Member of Research Committee, School of Dentistry, Babul University of Medical Sciences, Babul, Iran

a.sarrafan@mubabol.ac.ir

Received: 1 Dec 2015

Accepted: 7 April 2016

Journal of Islamic Dental Association of IRAN (JIDAI) Autumn 2015 ;27, (4)

Introduction

Odontogenic cysts are among the most important pathological lesions occurring in the oral cavity. Odontogenic keratocyst has a clinically invasive behavior and was first named by Philipsen in 1952 [1]. In the new classification by the World Health Organization in 2005, OKC was renamed as KCOT due to high recurrence rate after surgery (as high as 30%), high epithelial proliferation of this

lesion, its clinically invasive behavior and its correlation with nevoid basal-cell carcinoma syndrome (NBCCS or Gorlin-Goltz syndrome) [2,3].

In general, cysts grow due to increase in osmotic pressure inside their lumen while KCOT probably grows due to innate epithelial factors or enzymatic activity of the fibrous connective tissue of the lumen [4]. Increased expression of matrix

metalloproteinases 2 and 9 and anti-apoptotic proteins such as Bcl2 has been suggested as possible reasons for growth and expansion of KCOT. Also, it has potential for neoplastic changes, epithelial dysplasia and squamous cell carcinoma in rare cases [5]. In rare cases, squamous cell carcinoma has been observed in radicular cyst [4].

Growth rate of tissues is determined by the proliferative activity of cells and cell death [6]. Apoptosis plays a main role in growth and homeostasis of cells [3]. The Bcl2 family plays an inhibitory and stimulatory role in apoptosis. Bcl2, Bcl XI and Bclw are the anti-apoptotic members of this family and BAX, bak and bok are the pro-apoptotic members in this family [7]. Increased expression of Bcl2 has been reported in some tumors and diseases and also during tooth developmental stages [8,9]. A previous study assessed the expression of proliferative and apoptotic markers to recognize the association of histological features and biological behavior of odontogenic cysts by evaluation of their epithelial cells [10].

Considering the effect of apoptosis on growth and neoplastic transformation of tissues, this study aimed to compare immunohistochemical expression of BAX protein in RC and KCOT.

Materials and Methods

This descriptive analytical cross-sectional study was conducted in Babol University of Medical Sciences, School of Dentistry. Paraffinized blocks of 17 RCs and 17 KCOTs were retrieved from the archives of the Department of Oral and Maxillofacial Pathology during 2010-2014 and reviewed. After applying the exclusion criteria namely tissue necrosis, inadequate fixation, inadequate amount of tissue specimen and cases of KCOT associated with NBCCS, suitable tissue blocks were chosen for the study.

Age, gender and location of lesion were extracted from patient files. A 4 μ -thick slice was cut out of each paraffin block and stained with hematoxylin and eosin and was evaluated again by an oral pathologist. Blocks with correct diagnosis with an adequate length of epithelium were selected for the study and a 3 μ -thick slice was cut out of each block. Prior to IHC, this method was tested on 10

paraffinized blocks (ductal carcinoma of the breast, adenocarcinoma of the breast, RC and KCOT) in two groups of five. Primary antibody and different pH values of citrate buffer were tested in different incubation times and eventually, the best conditions for IHC were chosen. Next, IHC was performed on paraffin blocks. First, the slides were subjected to dry heat at 37°C for 24 hours and then at 80°C for 20 minutes. Next, slides were immersed in xylene for deparaffinization and were then placed in graded ethanol (96%, 100%, 70% and 80%, respectively).

For antigen retrieval, the slides were immersed in citrate buffer (10 μ) and autoclaved for 10 minutes (121°C, 2 atmosphere pressure) and were then allowed to cool down to room temperature and deparaffinized. After hydration and irrigation with phosphate buffered saline (PBS), 3% H₂O₂ in PBS was used for 30 minutes to inhibit endogenous peroxidase. The samples were then placed in 50 mM citrate buffer solution at 100°C for 20 minutes for preparation for BAX antibody. For blocking, 10% goat serum and 3% Triton X-100 were applied on samples for 30 minutes.

For IHC, Histostain-Plus Bulk kit (Zymed 2nd Generation, LABSA Detection System, Santiago, Chile) was used. Rabbit anti-human BAX primary antibody with 40 μ g/mL concentration (AV02020, rabbit anti-BAX antibody, Sigma Aldrich, AZ, USA) was diluted 1:50 and applied on samples for 24 hours at room temperature. Next, samples were rinsed with PBS three times for a total duration of 15 minutes. HRP secondary antibody with 1:1000 concentration (HRP-conjugated phosphotyrosine-specific antibody concentrate, Sigma Aldrich, AZ, USA) was applied on samples for two hours. After rinsing with PBS, specimens were incubated for 30 minutes at lab temperature and then diaminobenzidine hydrochloride chromogen was added as enzyme substrate to slides in order for staining to occur. Then, dehydration was done using graded ethanol from low to high concentrations until reaching 100% concentration. Slides were immersed in xylene twice and a protective cover slip was eventually mounted on them. Ductal carcinoma of the breast was used as positive control. All stained slides were observed under a light microscope at x40 magnification (Olympus, Tokyo, Japan).

Next, stained cells were counted randomly in five high power fields. Stained cells in all epithelial layers were counted. Number of positive cells was counted and calculated as a percentage relative to the total number of cells.

The data were analyzed using SPSS version 21. The two groups were compared using Student's t-test at $P < 0.05$ level of significance).

Results

Of 34 specimens evaluated in this study, 17 were RCs occurring in seven males (17.41%) and 10 females (82.58%) and 17 were KCOTs occurring in nine males (52.95%) and eight females (47.05%). Of 17 KCOTs, 12 were inflammatory type and five were non-inflammatory. Patients' age was 5-66 years in RC group and 22-35 years in KCOT group. In terms of anatomical site, six RCs were in the maxilla and 11 were in the mandible. Of 17 KCOTs, 16 were in the mandible and one was in the maxilla. Also, all KCOTs were parakeratinized and non-syndromic. In staining with BAX antibody, immunohistochemical analysis of the slides showed that cytoplasm of epithelial cells in RCs had a brown color. The mean number of BAX positive cells in the epithelial lining of KCOT was 16.4 ± 9.4 cells; this rate was 22.03 ± 11.27 cells in inflammatory and 10.77 ± 3.2 cells in non-inflammatory types. This value was 66.4 ± 12.3 cells in the epithelial lining of radicular cyst. A significant difference was noted in the mean number of epithelial cells with cytoplasm stained for BAX in all layers of epithelial lining of RCs and KCOTs (Figures 1 to 4) ($P = 0.012$). In other words, the mean number of BAX positive cells in the epithelial lining of radicular cyst was higher than that in epithelial lining of KCOT (Diagram 1)

Discussion

Studies evaluating the expression of both BAX and Bcl2 markers in the epithelial lining of odontogenic oral lesions are limited [11]. The current results showed that expression of BAX in the epithelial lining of KCOT was less than that in RC epithelium. The ratio of the expression level of Bcl2 to BAX indicates the path of cells towards apoptosis or proliferation; this ratio was 0.72 in RC and 32.4 in KCOT, which indicates higher

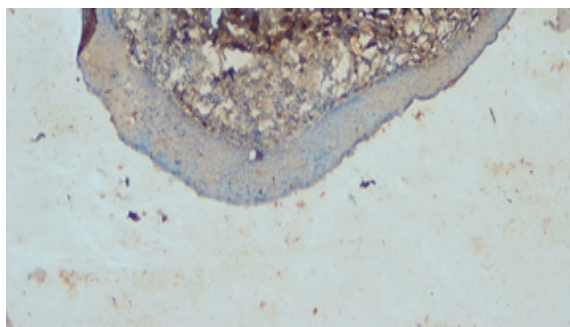


Figure 1. Low expression of BAX in KCOT at x100 magnification (IHC staining)

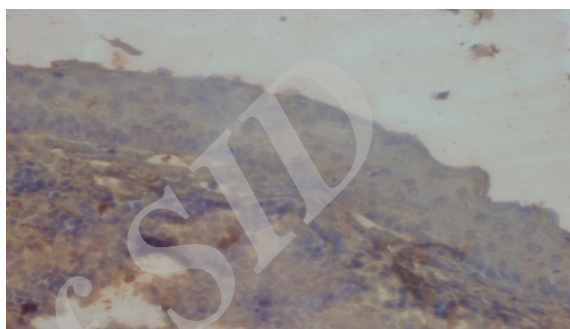


Figure 2. Low expression of BAX in KCOT at x400 magnification (IHC staining)

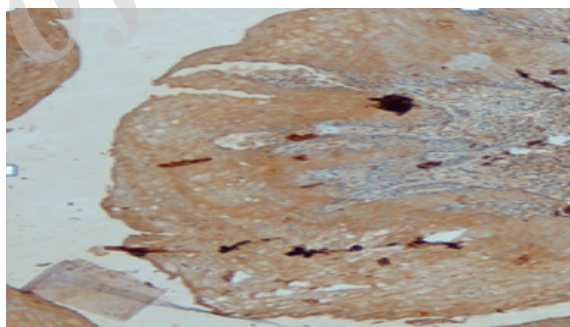


Figure 3. High expression of BAX in RC at x100 magnification (IHC staining)

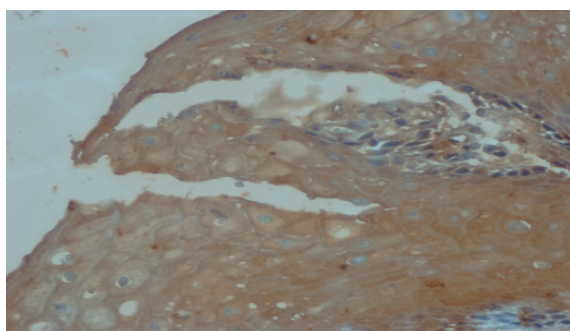


Figure 4. High expression of BAX in RC at x400 magnification (IHC staining)

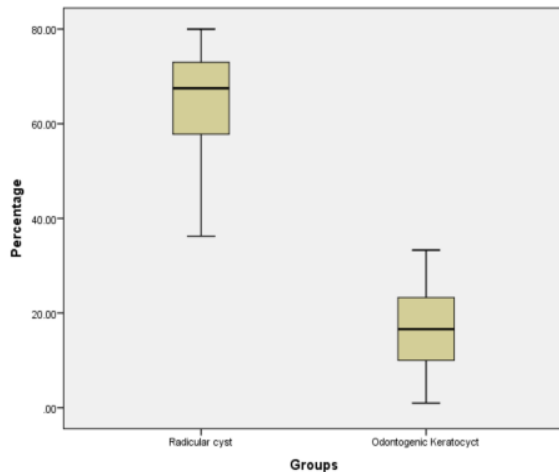


Diagram 1. The mean number of cells positively stained for BAX in the epithelial lining of RC and KCOT

expression of pro-apoptotic compared to anti-apoptotic proteins in RC. This ratio can result in release of cytochrome C from mitochondria and lead to activation of the caspase cascade and eventual cell death [11]. BAX and BAK are pro-apoptotic proteins required for apoptosis. They directly increase the permeability of mitochondria. Their activity is inhibited by anti-apoptotic members of this family such as Bcl2 and Bcl XL. BH3 protein enhances apoptosis by neutralizing the activity of Bcl2 and Bcl XL anti-apoptotic proteins. BAX and BAK are activated and form holes in the mitochondrial membrane. Cytochrome C leaks into the cytosol where it bonds to APAF-1 and activates caspase-9. Caspase-9, similar to caspas

e-8, can cleave executioner caspases and activate them [12]. In addition to the afore-mentioned correlation between BAX and Bcl2, BAX marker is related to other genes such as P53 and RB for apoptosis. P53 is an important pre-apoptotic gene, which induces apoptosis in cells, which are not capable of repairing DNA damage. Activities of P53 are partly mediated by the activation of BAX transcription [12]. The correlation between BAX and RB requires the presence of P53. Activated P53 results in transcription of P21 gene, which inhibits phosphorylation of RB and stops the G1-S phase of cell cycle. This stop in cell cycle enables the cells to repair their DNA. If DNA damage

cannot be repaired, P53 induces apoptosis [12]. Considering the mechanism of action of BAX and its correlation with other apoptotic and proliferative markers, the current findings can be justified such that Tekkesin et al, in their study in Turkey evaluated the expression of Ki67, Bcl2 and BAX in OKC, ameloblastoma and RC and concluded that the expression of apoptotic proteins such as BAX was lower in OKC than in RC. However, expression of anti-apoptotic proteins such as Bcl2 and Ki67 in OKC was higher compared to RC; this indicates invasive behavior of OKC compared to RC [3]. Also, the current results were in line with those of Jahanshahi et al, who evaluated the expression of BAX and Bcl2 in OKC. They concluded that expression of BAX in these lesions was very low and it did not play any important role either [13]. In 2009, Saghravani et al. evaluated the expression of P53 marker (which inhibits cell growth) in RC and concluded that its expression was very low and limited only to the basal area. Also, in their study, expression of MDM2, which is a negative regulator of growth, was evaluated in RC. This marker was expressed in the entire thickness of epithelium in more than half of the specimens and had an expression intensity of moderate to severe in most cases; whereas, expression of P53 in RC was mainly limited to the basal area with weak intensity. Since RC is an inflammatory cyst in nature, possible effect of numerous chronic inflammatory cells in the connective tissue on MDM2 and their penetration into the epithelial lining of the cyst should also be taken into account because it appears that this process is the consequence of release of chemical inflammatory mediators and their effect on the activity of this protein in the epithelium [14].

Piatteli et al. stated that Bcl2 marker aided in differentiation of KCOT from other odontogenic cysts. They attributed the over-expression of Bcl2 in the basal layer of KCOT to abnormal control of cell cycle. In their study, staining of cytoplasm of cells in basal layer of KCOT for Bcl2 indicated absence of apoptosis in basal layer of this lesion [15]. In this regard, Narain et al, in a similar study in 2005 compared the expression of Bcl2 in KCOT and ameloblastoma and concluded that high expression of this protein in both lesions indicates

their invasive behavior, which was in agreement with our findings [16]. Razavi et al, in 2015 evaluated the expression of Bcl2 and epidermal growth factor receptor in KCOT and concluded that high expression of Bcl2 and absence of staining of epidermal growth factor receptor in OKC were the main reasons for invasive and different behavior of this lesion compared to other cysts [17].

Kolar et al, in 2006 evaluated the expression of apoptotic and anti-apoptotic markers in different types of OKC including NBCCS and showed that expression of this marker in syndromic and non-syndromic OKCs was different; this difference was attributed to genetic factors and differences in degree of differentiation of cells in patients with NBCCS [18].

Conclusion

Based on the current results, KCOT cells have high survival potential. Low expression of pro-apoptotic proteins in epithelial lining of this cyst is in accordance with its clinical behavior.

Acknowledgement

This study was part of a thesis for DDS degree submitted to Babol University of Medical Sciences, School of Dentistry (#9338716). The study was financially supported by the Research Deputy of Babol University of Medical Sciences. The authors would like to thank Mrs. Ebrahim Pour for the laboratory work related to this study.

References

1. Oda D, Rivera V, Ghanee N, Kenny E, Dawson K. Odontogenic keratocyst: The northwestern USA experience. *J Contemp Dent Pract.* 2000 Feb; 1(2): 60-74.
2. Reichart PA, Philipsen HP, Sciubba JJ. The new classification of head and neck tumours (WHO)-any changes? *Oral Oncol.* 2006 Sept;42(8):757-8.
3. Soluk Tekkeşin M, Mutlu S, Olgaç V. Expressions of bax, bcl-2 and Ki-67 in odontogenic keratocysts (keratocystic odontogenic tumor) in comparison with ameloblastomas and radicular cysts. *Turk Patoloj Derg.* 2012 Jul; 28 (1):49-55.
4. Neville BW, Damm DD, Allen CM, Bouquot

JE. *Oral & Maxillofacial Pathology.* 3rded. Philadelphia: Saunders; 2009. Chapter:15.

5. Regezzi JA, Sciubba JJ, Jordan RCK: *Oral Pathology: Clinical Pathologic Correlations.* 5th ed. Philadelphia, Elsevier Saunders; 2008, 245.

6. Rangiani A, Motahhary P. Evaluation of bax and bcl-2 expression in odontogenic keratocysts and orthokeratinized odontogenic cysts: A comparison of two cysts. *Oral Oncol.* 2009 July;45(7):41-44.

7. Billen LP, Kokoski CL, Lovell JF, Leber B, Andrews DW. Bcl-XL inhibits membrane permeabilization by competing with Bax. *PLoS Biol.* 2008 Jun;6(6):e147.

8. Baliga BC, Kumar S. Role of bcl-2 family of proteins in malignancy. *Hematol Oncol.* 2002 Jun; 20(2):63-74.

9. Krajewski S, Hugger A, Krajewska M, Reed JC, Mai JK. Development expression patterns of bcl-2, bcl-X, bax and bak in teeth. *Cell Death Diff.* 1998 May; 5(5):408-415.

10. Shear M. The aggressive nature of the odontogenic keratocyst: is it a benign cystic neoplasm? Part 2. Proliferation and genetic studies. *Oral Oncol.* 2002 Jun; 38(4):323-331.

11. Zhang M, Zhang P, Zhang C, Sun J, Wang L, Li J, et al. Prognostic significance of Bcl2 and Bax protein expression in the patients with oral squamous cell carcinoma. *J Oral Pathol Med.* 2009 Mar; 38(3):307-13.

12. Kumar V, Abbas AK, Aster JC. *Robbins basic pathology: Elsevier Health Sciences;* 2012.

13. Jahanshahi Gh, Talebi A, Shirvani A. Expression of Bcl-2 in the epithelial lining of odontogenic keratocysts. *J of Dent Tehran Univ of Med Sci.* 2006 Nov; 3(1):30-35.

14. Saghraevanian N, Habibi A, Mohtasham N, Afzal Aghaie M, Shiva A, Babazadeh S. Evaluation of MDM2 and P53 expression in dentigerous, radicular and residual cysts by immunohistochemistry. *J of Mashhad Dent Sch.* 2009 May;33(2):145-52.

15. Piatelli A, Fomni M, Rubini C. Differentiation of odontogenic keratocyst from other odontogenic cysts by the expression of BCL 2 immunoreactivity. *Oral Oncol.* 1998 Sept; 34(5): 404-407.

16. Narain P, Parihar S, Verma A, Sharma A. Differentiation of ameloblastoma, odontogenic

keratocyst and dentigerous cysts by BCL-2 Protein-an immunohistochemical study. Indian J of Contemp Dent. 2015 Jul; 3(2):54-9.

17. Razavi SM, Torabinia N, Mohajeri MR, Shahriyary S, Ghalegolab S, Nouri S. Expression of Bcl-2 and epithelial growth factor receptor proteins in keratocystic odontogenic tumor in comparison with dentigerous cyst and

ameloblastoma. Dent Res J. 2015 Jul-Aug ; 12 (4):342-7.

18. Kolář Z, Geierová M, Bouchal J, Pazdera J, Zbořil V, Tvrđý P. Immunohistochemical analysis of the biological potential of odontogenic keratocysts. J Oral Pathol Med. 2006 Feb;35(2):75-80.

Archive of SID