

## The frequency of vascular changes in the histopathology of cutaneous leishmaniasis

Farhad Handjani<sup>1</sup> Perika La Kumar<sup>2</sup> Mandana Khosroara<sup>3</sup> Maryam Sadat Sadati<sup>1</sup>

<sup>1</sup> Molecular Dermatology Research Center & Department of Dermatology, Shiraz University of Medical Sciences, Shiraz, Iran.

<sup>2</sup> Department of Pathology, Shiraz University of Medical Sciences, Shiraz, Iran.

<sup>3</sup> Dermatologist, Tehran, Iran.

Received 14 July, 2017

Accepted 18 Nov, 2017

### Original Article

### Abstract

**Introduction:** Cutaneous leishmaniasis (CL) is a parasitic skin infection which can be debilitating. This study was performed to determine the vascular changes in the histopathology of CL.

**Methods:** Thirty-seven patients with CL were included in a prospective study. A 4 mm punch biopsy was obtained from the border of the lesion. After histopathologic processing and H&E staining, it was reviewed by a pathologist. In addition, 285 cases of CL, whose biopsy files were restored at the pathology ward, during a 23 year period, were reviewed for the assessment of vascular changes. Immunoperoxidase staining for IgG and IgA was also performed on paraffin-embedded blocks.

**Results:** Out of the 37 patients with CL, 64.7% were male and 35.3% were female. In this group, 73.5% had chronic and 26.5% had acute CL. The most common type of lesion was an ulcerated plaque. Of the total of 322 biopsy files that were reviewed, 34 (10.5%) had vascular changes in their lesions. The vascular changes included moderate to severe perivascular lymphocytic infiltration and severe perivascular lymphocytic infiltration with obstruction or narrowing of vessels with or without destruction. A few cases showed endothelial proliferation of blood vessels and one case had leukocytoclastic vasculitis.

**Conclusion:** CL should be considered in the differential diagnosis of chronic cutaneous ulcers in endemic areas, which demonstrate vascular changes or vasculitis in their pathology. Severity of the disease may be due to the underlying intense local inflammatory reaction, manifested as lymphocytic vasculitis.

**Key words:** Cutaneous, Leishmaniasis, Vascular Changes, Histopathology

**Citation:** Handjani F, La Kumar P, Khosroara M, Sadati MS. The frequency of vascular changes in the histopathology of cutaneous leishmaniasis. *Hormozgan Medical Journal* 2017;21(3):147-152.

### Introduction:

Leishmaniasis is a zoonotic infection caused by genus leishmania. Its manifestations range from a self-healing cutaneous lesion to visceral forms.

Cutaneous leishmaniasis (CL) is endemic in some geographic locations.

In acute CL the histopathology of a skin lesion shows epidermal hyperkeratosis, an ulcer covered

by cellular debris and live and dead parasites, and even pseudoepitheliomatous hyperplasia. The dermis contains an intense diffuse inflammatory infiltrate, composed of histiocytes, lymphocytes and few plasma cells and leishman bodies (1).

In chronic CL, that does not heal by one year, the histopathologic hallmark is a diffuse dense or nodular infiltration of lymphocytes and epithelioid histiocytes within the superficial and deep dermis. In chronic cases leishman bodies are rare (1-3).

However, there are few reports of lymphocytic vasculitis in cutaneous, mucosal and visceral leishmaniasis (4-8). Veress et al reported vasculitis with or without fibrinoid necrosis and fibrin thrombi in both arteries and veins in cutaneous, mucosal and visceral leishmaniasis (4). Mirejovský et al demonstrated the existence of fibrinoid vasculitis in the histopathology of CL (6). This is important because chronicity and failure of early treatment with antimony has been associated with presence of lymphocytic vasculitis in some cases (9).

In this study, 37 patients with CL were included in a prospective study and their demographic data alongside their clinical presentation was documented. A special look for vascular changes in their histopathological findings was performed. In addition, a retrospective study was undertaken to re-assess the skin biopsies of 285 cases with CL, in order to detect cases with vascular changes in their skin biopsies. The objective of the study was to determine the frequency of vascular changes in the histopathology of CL and attempt to see if any correlation exists with any particular type of clinical presentation.

## Methods:

In this cross sectional study 37 patients new case of Old World CL who referred to Shiraz University of Medical Sciences (SUMS) dermatology ward, were included. A detailed personal and medical history was obtained. The location, size, and morphology of CL, presence or absence of lymphadenopathy and disease duration were documented.

A 4 mm pinch biopsy was obtained from the border of the lesion. After histopathologic

processing and H&E staining, it was reviewed using a microscope by a dermatopathologist.

In addition, 285 cases of CL, whose biopsy files were stored at the pathology department of SUMS, during a 23 year period, were reviewed for the assessment of vascular changes. The demographic data as well as exact clinical presentation for these cases were not available, therefore only vascular changes in the samples were assessed. Immunoperoxidase staining for IgG and IgA was performed on paraffin embedded blocks.

The pathologist reviewed all the pathology slides (H&E staining and immunoperoxidase staining) and looked for any vascular change including perivascular inflammation and vessel wall or lumen changes. The data was analyzed with SPSS.

## Results:

Overall, a total of 322 Old World CL biopsy files were reviewed.

Out of the 37 new cases of CL, 64.7% were male and 35.3% were females. Their ages ranged from 3 to 72 years. The mean age of the patients was  $34.7 \pm 20$  years. 73.5% had acute CL (duration of the disease less than 1 year), and 26.5% had chronic CL (duration of disease more than 1 year or recurrence of new papulonodules at the scarring site of previous healed CL).

Disease duration in acute CL ranged from 21 to 90 days with a mean of  $28.5 \pm 17$  days. The majority of patients had disease duration of 30 days or less (38.2%). The size of CL lesions ranged from 0.5 to 3 cm. In this group, 79.4% had a solitary lesion, 17.6% had two and 2.9% had more than two lesions.

The most common clinical type of CL was an ulcerated plaque in both acute and chronic CL cases (58.5%) and the face was the most common location (35.3%).

Regional lymphadenopathy was present in 20.5% and it was more common in chronic than acute disease (66.7% versus 24%, respectively).

In early acute CL, the biopsies revealed the classic granulomatous infiltration with Leishman bodies. In chronic cases, a spectrum of vascular changes were seen in the majority of cases together with absence of Leishman bodies. In this group, out of 37 cases, only 7 (18.9%) had vascular changes.

Overall, of the total 322 biopsy files which were reviewed, 34 (10.5%) cases had evidence of vasculitis or vascular alterations (Table 1).

**Table 1. Frequency of vascular changes in cutaneous leishmaniasis lesions**

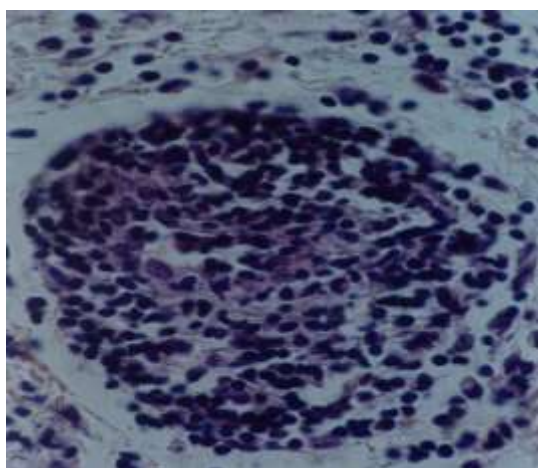
Vascular changes	34	10.5%
No vascular change	288	89.5%
<b>Total</b>	<b>322</b>	<b>100%</b>

The vascular changes include;

A- Moderate to severe perivascular lymphocytic infiltration with open lumens of vessels in the dermis.

B- Severe perivascular lymphocytic infiltration with obstructed and narrow lumens of vessels.

Figure 1.



**Figure 1. Severe perivascular lymphocytic infiltration with obstructed and narrow lumens of vessels (H&E stain)**

C- Moderate perivascular lymphocytic infiltration with destruction of vessel wall.

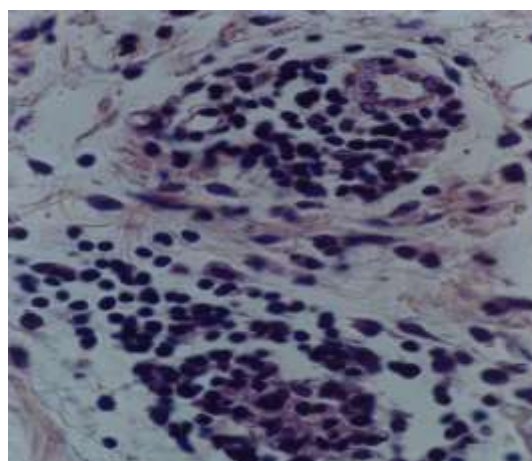
Figure 2.

D- Severe perivascular lymphocytic infiltration with endothelial proliferation.

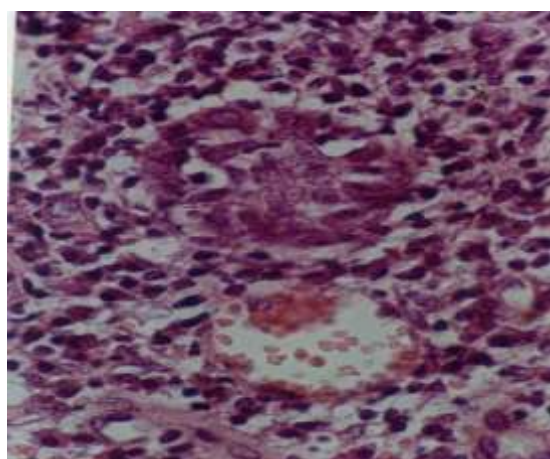
Figure 3.

One case revealed evidence of leukocytoclastic vasculitis and well formed granulomas were rarely noticed.

Immunoperoxidase staining for IgG and IgA was performed on paraffin embedded blocks of specimens which demonstrated vascular changes, but none showed any deposits.



**Figure 2. Perivascular lymphocytic infiltration with destruction of vessel wall (H&E stain)**



**Figure 3. Severe perivascular lymphocytic infiltration with endothelial proliferation (H&E stain)**

**Conclusion:**

CL is one of the most common parasitic skin diseases in Iran, presenting with acute and chronic skin ulcers and resultant disfiguring scars. It is caused by the genus *Leishmania* which is transmitted through the bite of an infected sandfly. The best way to diagnose the disease is by the detection of parasites in the infected tissue histopathology evaluation (10). In our region leishmania major is the most common types.

To date, there are few reports in leishmania literature describing vascular changes and lymphocytic vasculitis in cutaneous, mucosal and visceral forms of the disease.

In experimental models of leishmaniasis in various animals, endothelial proliferation and acute vasculitis with fibrinoid necrosis have been noted (11,12).

In a study from Saudi Arabia, 14 out of 37 cases of CL had vascular changes that included increased vascular permeability and vasculitis with formation of fibrin thrombi. IgG and IgA were noted in the endothelial cells, media, and perivascular spaces. The latter finding might be an evidence of immune complex deposition (4). Essa et al also described alterations with or without fibrinoid necrosis and fibrin thrombi with the presence of IgG and IgA in the same pattern (7).

Ridley et al have shown *in situ* immune complex formation in human CL and suggested that immune complexes stimulate formation of granulomas (5).

Mirejovský et al noted fibrinoid vasculitis in CL lesions (6) and Veress et al showed vascular changes in mucosal leishmaniasis lesions (8).

These vascular changes may have an impact on clinical presentation and response to treatment. In the study by Machado et al, out of the 22 CL patients in the study, 10 developed enlargement and ulceration of lesions, despite early antimonial therapy. Vasculitis was observed in 3 of these patients, although due to the paucity of patients, no correlation was found between histopathology findings and response to therapy (9).

We evaluated the demographic characteristics in the 37 cases of CL patients, as the demographic data from the old cases were not available. We noted a male predominance (1.8/1) and the mean age was  $34.7 \pm 20$  which is older than the study of Machado ( $23 \pm 6$ ). The most common type of lesion encountered, was ulcerated plaque followed by; nodule, non ulcerated plaque and papule. In the present study, we found vascular changes in 10.5 % of the 322 CL patients which were reviewed

We found a variety of histopathological changes which included: in acute CL, granulomatous infiltration and Leishman bodies were noted. In chronic cases, vascular changes were more prominent with absence of Leishman bodies. These observations were similar to previous mentioned studies but our cases were much more. Presence of vasculitis in CL may be due to local immunologic

reactions, because of antibody excess which triggers local immune complex formation.

According to this and previous similar studies, CL should be considered in the differential diagnosis of chronic cutaneous ulcers in endemic areas, where vascular changes or vasculitis is detected in their histopathology findings. Severity of the disease may be due to the underlying intense local inflammatory reaction, manifested as lymphocytic vasculitis. Future studies are recommended to determine this possibility.

## References:

1. Kurban AK, Malak JA, Farah FS, Chaglassian HT. Histopathology of cutaneous leishmaniasis. *Arch Dermatol.* 1966;93(4):396-401.
2. Minard HM, Daniel AK, Pool RR, Snowden KF, Levine GJ. Pathology in Practice. Cutaneous leishmaniasis. *J Am Vet Med Assoc.* 2017;251(1):57-59.
3. Micheletti RG, Dominguez AR, Wanat KA. Bedside diagnostics in dermatology: Parasitic and noninfectious diseases. *J Am Acad Dermatol.* 2017;77(2):221-230.
4. Veress B, el-Hassan AM. Vascular changes in human leishmaniasis: a light microscopic and immunohistological study. *Ann Trop Med Parasitol.* 1986;80(2):183-188.
5. Ridley MJ, Ridley DS. Cutaneous leishmaniasis: immune complex formation and necrosis in the acute phase. *Brit J Exp Pathol.* 1984;65(3):327-336.
6. Mirejovský P, Bednár B, Kodetová D, Stejskal J. Visceral and cutaneous leishmaniasis. *Cesk Patol.* 1996;32(2):70-74.
7. Essa MH, Mangoud AM, Morsy TA, Aly MA, Salama MM. Vascular changes in cutaneous leishmaniasis. *J Egypt Soc Parasitol.* 1989;19(2):683-687.
8. Veress B, Abdalla ER, El Hassan MA. Vascular lesions in mucosal leishmaniasis. *Morphol Igazságügyi Orv Sz.* 1977;17(3):226-230.
9. Machado P, Araujo C, Da Silva AT, Almeida RP, D'Oliveira Jr A, Bittencourt A. Failure of early treatment of cutaneous leishmaniasis in

- preventing the development of an ulcer. *Clin Infect Dis.* 2002;34(12):69-73.
10. Abuzaid AA, Abdoon AM, Aldahan MA, Alzahrani AG, Alhakeem RF, Asiri AM, et al. Cutaneous Leishmaniasis in Saudi Arabia: A Comprehensive Overview. *Vector Borne Zoonotic Dis.* 2017;17(10):673-684.
  11. Meleny HE. The histopathology of Kala-azar in hamster, monkey and man. *Am J Pathol.* 1925;1(2):147-168.
  12. Barygeson ADM, Bray RS, Wolstencroft RA, Dumonde DC. Immunity in cutaneous leishmaniasis of the guinea pig. *Clin Exp Immunol.* 1970;7(3):301-341.

## بررسی تغییرات عروقی در هیستوپاتولوژی لیشمانیای پوستی

فرهاد هنجانی<sup>۱</sup>، پریکا لاکومار<sup>۲</sup>، ماندانا خسروآرا<sup>۳</sup>، مریم سادات ساداتی<sup>۱</sup>  
<sup>۱</sup> مرکز تحقیقات مولکولی پوست، گروه پوست، دانشگاه علوم پزشکی شیراز، شیراز، ایران.  
<sup>۲</sup> گروه پاتولوژی، دانشگاه علوم پزشکی شیراز، شیراز، ایران.  
<sup>۳</sup> متخصص پوست، تهران، ایران.

مجله پزشکی هرمزگان سال بیست و یکم شماره سوم ۹۶ صفحات ۱۵۲-۱۴۷

### چکیده

**مقدمه:** لیشمانیا پوستی عفونت انگلی پوست می باشد که می تواند عوارض ناخوشایند برجای بگذارد. این بررسی جهت بررسی تغییرات عروقی در هیستوپاتولوژی ضایعات لیشمانیای پوستی انجام گرفت.

**روش کار:** از ضایعات ۳۷ بیمار با لیشمانیای پوستی نمونه برداری شد و توسط پاتولوژیست مورد بررسی قرار گرفت. علاوه بر این، پاتولوژی ۲۸۵ بیمار دیگر که در بخش پاتولوژی از ۲۳ سال قبل موجود بود توسط پاتولوژیست از لحاظ تغییرات بررسی عروقی شد.

**نتایج:** از ۳۷ بیمار با بیوپسی جدید ۶۴/۷ درصد مرد و خانم ۳۵/۳ درصد خانم بودند، داشتند. شایع ترین فرم بالینی پلاک زخمی بود از ۳۳۲ مورد کل نمونه برداری، ۱۰/۵ درصد تغییرات پاتولوژیک در عروق داشتند، که شامل ارتشاح لنفوسیت متوسط تا شدید در عروق و در ارتشاح شدید لنفوسیت به علاوه انسداد یا باریک شدن عروق یا تخریب عروقی داشتند یک مورد واسکولیت لکوسیتوکلستیک مشاهده شد.

**نتیجه گیری:** لیشمانیای پوستی می تواند تغییرات عروقی به شکل ارتشاح در عروق یا تخریب عروقی ایجاد کند شدت بیماری می تواند به علت پروسه انتهایی زمینه ای باشد.

**کلیدواژه ها:** لیشمانیا، تغییرات عروقی، هیستوپاتولوژی

نویسنده مسئول:  
 دکتر مریم سادات ساداتی  
 گروه پوست، دانشگاه علوم پزشکی  
 شیراز  
 شیراز-ایران  
 تلفن: +۹۸ ۹۱۷۳۳۷۱۹۴۳  
 پست الکترونیکی:  
 Msadati63@yahoo.com

نوع مقاله: پژوهشی

دریافت مقاله: ۹۶/۴/۲۳ اصلاح نهایی: ۹۶/۸/۲۱ پذیرش مقاله: ۹۶/۸/۲۷

ارجاع: هنجانی فرهاد، لاکومار پریکا، خسروآرا ماندانا، ساداتی مریم سادات. بررسی تغییرات عروقی در هیستوپاتولوژی لیشمانیای پوستی. مجله پزشکی هرمزگان ۹۶(۳): ۱۵۲-۱۴۷.