



Correlation Between Cephalometric and Photographic Results of Determining the Lower Anterior Facial Height

Maryam Nicoo¹, Farnaz Fakhri², Fatemeh Nikou³ and Abdossalam Parastesh^{4,*}

¹Dental Students' Research Committee, Department of Operative School of Dentistry, Isfahan University of Medical Sciences, Isfahan, Iran

²Dental Research Center, Department of Orthodontics, School of Dentistry, Hormozgan University of Medical Sciences, Hormozgan, Iran

³Dental Students' Research Committee, Department of Periodontics, School of Dentistry, Qazvin University of Medical Sciences, Qazvin, Iran

⁴Dental Students' Research Committee, School of Dentistry, Hormozgan University of Medical Sciences, Hormozgan, Iran

*Corresponding author: Graduate, Dental Students' Research Committee, School of Dentistry, Hormozgan University of Medical Sciences, Hormozgan, Iran. Email: parastesh.abdossalam@gmail.com

Received 2018 November 30; Revised 2019 January 29; Accepted 2019 March 02.

Abstract

Background: Today, the most commonly used instrument for determining the inferior face height is lateral cephalometry; however, due to the fact that some lateral cephalometric radiographs are given to the patient while taking radiation, and with regard to the overlaps and distortions of structures in this radiograph.

Objectives: The purpose of this study was to study the inferior height of the face based on the one-third of the face in photography and then compare its correlation with the results of cephalometry.

Methods: This descriptive-analytical study was carried out with photographic and lateral cephalometric radiographs of 75 randomly selected participants (38 women and 37 men) from among patients consulting the orthodontic clinics in Bandar Abbas in 2012 - 2013. All participants had all their permanent teeth (without third molar involvement). Patients signed an informed consent form for participation. There was no history of head and face trauma, orthognathic surgery, previous orthodontic treatment, and congenital anomalies. The anterior height of the face was evaluated based on the one-third of the face on photography according to the results of FMA (Frankfort-mandibular plane angle), Sn-GoGN, Bjork, and Jarabak, and the correlations of these values with each other were determined. Data were analyzed by SPSS software using chi-square test, kappa coefficient, and Pearson coefficient.

Results: No significant correlation was found between the photographic and cephalometric data of face height ($r = -0.03$, $P > 0.05$). There was a significant inverse correlation between the results of FMA and Jarabak index ($r = -0.6$, $P < 0.05$). There were significant direct relationships between the results of FMA and those of Bjork ($r = 0.8$, $P < 0.05$) and Sn-GoGn ($r = 0.7$, $P < 0.05$). There was no statistically significant relationship between the facial form and class I and II skeletal occlusions ($P > 0.05$). There was no meaningful relationship between the results of FMA angle and facial form in class 1 and 2 occlusion subjects ($P > 0.05$). However, this association was found stronger in class I than in class II occlusion.

Conclusions: There is no meaningful correlation between photographic and cephalometric measurements of facial height, and we always need lateral cephalometrics for the correct orthodontic treatment plan and as a golden standard. Cephalometric variables are correlated with each other for determining the vertical growth pattern, and each can be used for diagnosis alternatively.

Keywords: Cephalometry, Photography, Orthodontics

1. Background

The vertical growth pattern of the face plays an important role in achieving facial balance. Changes in vertical growth are prevalent and have some orthodontic sequels (1). One of the fundamental problems in orthodontic management is the growth forecast (2). A long or short face perhaps is the result of the malformation of hard or soft tissues of the face (1).

Photographs have long been used in the anthropometric investigation and orthodontic clinical trials. Nonethe-

less, since the development of the cephalostat and standardization of the radiographic methods, the photography of the face has turned into an auxiliary record for many years. The emphasis was on the objective evaluation of cephalometric radiographs, putting only an objective role for facial photography (3). Cephalometric radiography was innovated by Broadbent and Hofrath in 1931 and thereafter, it has been widely used as a necessary instrument in orthodontic offices for the discussion of malocclusion and vertical skeletal problems, as well as in clinical and research orthodontics by investigators (1, 4). A multifac-

torial malocclusion etiology has generally been assumed, with both genetic and environmental contributions such as ethnicity, functional, and pathologic condition playing a role in the variability of dentocraniofacial growth and development (5). Arne Bjork worked in dentistry from 1937 to 1951 and presented seven structural symptoms to characterize the growth of the mandible swirl. He made a diagram of face to characterize the dispensation of facial pragmatism using the linear and angular measurements. He used the SN plane as the plane of reference (6). Cephalometric analysis was done by Jarabak based on the foundations of the experimental research of Bjork. A diagram of the face (polygon) containing linear and angular configurations determining the extent of facial prognathous made up the Bjork Jarabak's analysis (7). Jarabak's cephalometric analysis mostly assessed vertical intermaxillary relationships and used the base of the skull as a reference (8). In 1946, Tweed introduced the Frankfort-mandibular plane angle (FMA) that, as the name indicated, was formed between the mandibular and Frankfort planes (9). Reliable relationships between overlying of face tissues and skeletal anatomy have been discovered via radiographic analysis. Nonetheless, evaluations including cephalometric and photographic measurements have rarely been carried out, and incompatible results have been reported. Because cephalometric analysis establishes the gold standard for the detection of craniofacial morphology in clinical offices, the feasibility of forecasting cephalometric values through photographs may present a noninvasive diagnostic instrument, particularly for epidemiologic investigations (3).

2. Objectives

The aim of this study was to evaluate the correlation between the results of cephalometric and photographic analyses for determining lower anterior facial height in patients consulting the orthodontic clinics in Bandar Abbas.

3. Methods

This descriptive-analytical study was conducted during 2015 - 2016. The sample included 75 individuals (37 males and 38 females) aged 18 - 25 years. All participants in the study had all their permanent teeth (without third molar involvement). Patients signed an informed consent form for participation. There was no history of head and face trauma, orthognathic surgery, previous orthodontic treatment, and congenital anomalies. Patients eligible to participate in the study were invited to attend the orthodontic clinics on Saturdays, Mondays, and Wednesdays.

Photographs and lateral cephalometric films in the patients' files, prepared at a specific radiography clinic, were used for measurements. In this study, only were photographs and lateral cephalographs taken in the natural head position used. Photographs were made with the camera EOS 5D Mark III with a 200 × 70 mm lens and a 1.5 m distance on a tripod. Then, three points including Glabella, subnasal, and Menton were determined on photography to determine the one-third of faces. The superior height of the face was calculated from the point of Glabella to the subnasal and the inferior height of the face from the subnasal to the menton points. Then, the ratio of the superior height of the face to the inferior height of the face was calculated. The normal value of this ratio is 45.55, which is considered normal to a 10% difference. The subjects were divided into three groups: short, medium, and long face. To eliminate the errors caused by zooming in and aligning the actual size with the size of the radiograph, the image ruler was used in each cephalometric film. All cephalometers were manually traced on matte acetate. This work was done by a single person to prevent inter-examiner errors. Data were recorded at two-time intervals of two weeks to prevent intra-examiner errors. Face elevation was calculated on lateral cephalometric films based on FMA angle (Figure 1A), Sn-GoGn angle (Figure 1B), Jarabak index (Figure 1C), and Bjork angle (Figure 1D).

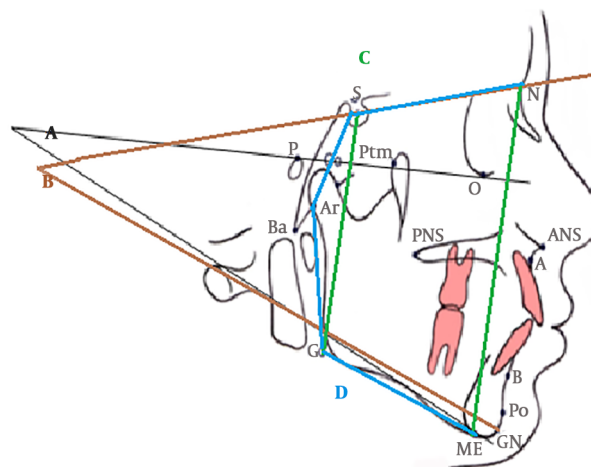


Figure 1. A, FMA angle; B, Sn-GoGn angle, C, Jarabak index; and D, Bjork angle

Finally, the correlation between the results of photographic and lateral cephalometry in class 1 and 2 skeletons was studied separately.

3.1. Statistical Analysis

Data were analyzed by SPSS software using chi-square test, kappa coefficient, and Pearson correlation coefficient.

4. Results

In this study, out of 75 cases, 62 had short faces and 13 had normal faces according to the photographic analysis. From 75 participants, three had mesoprosopic facial forms, 24 had euryprosopic facial forms, and 48 had leptoprosopic facial forms.

Moreover, 42 cases had normal FMA angles, two had FMA angles smaller than normal, and 31 had FMA angles bigger than normal. Thus, according to this angle, 42 had a normal inferior height of the face, two had a short inferior height of the face, and 31 had a long height of the face (Table 1).

Table 1. Results of FMA angle

	Frequency (%)
Normal	42 (56.0)
Short	2 (2.7)
Long	31 (41.3)
Total	75 (100.0)

Abbreviation: FMA, Frankfort-mandibular plane angle.

In addition, 22 subjects had a normal Jarabak index, 29 had a Jarabak index higher than normal, and 24 had a Jarabak index lower than normal. Thus, according to this index, 22 had a normal height of the face, 24 had a short height of the face, and 29 had a long height of the face (Table 2).

Table 2. Results of Jarabak Index

	Frequency (%)
Normal	22 (29.3)
Short	24 (32)
Long	29 (38.7)
Total	75 (100.0)

In addition, seven subjects had a normal Bjork angle, 24 had a Bjork angle higher than normal, and 44 had a Bjork angle lower than normal. Thus, according to this index, seven had a normal height of the face, 44 had a short height of the face, and 24 had a long height of the face (Table 3).

According to the results of Sn-GoGn, seven cases had a normal height of the face, 24 had a short height of the face, and 44 had a long height of the face (Table 4).

Table 3. Results of Bjork Angle

	Frequency (%)
Normal	7 (9.3)
Short	44 (58.7)
Long	24 (32.0)
Total	75 (100.0)

Table 4. Results of Sn-GoGn Angle

	Frequency (%)
Normal	7 (9.3)
Short	24 (32.0)
Long	44 (58.7)
Total	75 (100.0)

Of the 75 patients, 38 had class I occlusion and 37 had class II occlusion. There was no statistically significant correlation between the results of the FMA and the result of the photographic analysis ($P > 0.05$). Moreover, 53% of the subjects with normal facial height according to photographic analysis had also a normal facial height in terms of FMA while 46% of them had a long face in terms of FMA. In addition, 56.5% of the subjects with a short facial height according to photographic analysis had a normal facial height in terms of FMA while 40.3% of them had a long face in terms of FMA.

There was a statistically significant correlation between the results of FMA and Jarbak index, and this relationship was inverse ($r = -0.06, P < 0.05$). The results of FMA showed significant direct correlations with the results of Bjork ($r = 0.08, P < 0.05$) and Sn-GoGn ($r = 0.07, P < 0.05$).

There was no statistically significant correlation between the results of FMA and facial form in class I and II occlusion individuals ($P > 0.05$).

5. Discussion

The aim of this study was to juxtapose standardized facial photography with cephalometric radiography as a method of representing craniofacial morphology. Zhang et al. (10) described only low to moderate relationships between the results of cephalometric and photographic analyses. Analogous photographic and cephalometric LAFH (lower anterior facial height) showed the strongest relationship. Similar to our study, when comparing the results of FMA and cephalometric Sn-GoMe, the researchers did not find a strong correlation coefficient. On the contrary, powerful relationships were seen between the cephalometric and photographic FMA analogous angles in studies

by Bittner and Pancherz (11) and de Carvalho Rosas Gomes et al. (3). This dissimilarity possibly is due to the direction of intracranial SN line, which showed singular alterations (3).

The mean FMA angle in this study was three degrees higher than that of the Tweed study and 1.7 degrees higher than that of the Liliane study, indicating that the specimens had a backward mandibular rotation compared to the two studies mentioned. Perhaps the reason for this difference could be attributed to race (5).

Concerning the relationships between FMA, Jarabak, Bjork, and Sn-GoGn results, there was a significant inverse correlation between the results of FMA angle and Jarabak index. The results of FMA showed significant direct relationships with those of Bjork and Sn-GoGn.

The mean angle of Sn-GoGn in this study was reported to be two degrees higher than the angle reported in Steiner's study, indicating a backward mandibular rotation in the participants of this study.

The mean of the Jarabak index in this study was close to the standard deviations and was 3% lower than the mean value reported by Mayrui (66%). In addition, the average Bjork in this study was one degree lower than the value reported by Bjork and four degrees higher than the value reported by Mayrui.

There were 48 cases with leptoprosopic facial forms, 24 with euryprosopic and shorter forms, and only three with mesoprosopic forms.

There was no statistically significant relationship between the form of the face and the class I and II skeletal occlusions.

There was no significant relationship between the results of the FMA angle and the facial form in class I and II occlusion individuals. However, this association was found stronger in class I than in class II occlusion.

5.1. Limitations

The inaccessibility of computer-aided cephalometric and photographic analysis software was a limitation of the study. Moreover, because of random sampling, class III cases were not examined. It is suggested that class III cases be examined in future studies.

5.2. Conclusions

There is no meaningful correlation between facial height based on photographic and cephalometric measurements, and we always need lateral cephalometric radiographs for the correct orthodontic treatment plan as the golden standard. Cephalometric variables are correlated with each other for determining the vertical growth pattern, and each can be used for diagnosis alternatively.

Supplementary Material

Supplementary material(s) is available [here](#) [To read supplementary materials, please refer to the journal website and open PDF/HTML].

Footnotes

Authors' Contribution: Study concept and design: Maryam Nicoo and Farnaz Fakhri; analysis and interpretation of data: Maryam Nicoo and Abdossalam Parastesh; drafting of the manuscript: Farnaz Fakhri; critical revision of the manuscript for important intellectual content: Fatemeh Nikou; statistical analysis: Maryam Nicoo, Abdossalam Parastesh.

Conflicts of Interests: No financial or other competing interests are declared.

Ethical Considerations: This study was approved by the local research Ethics Committee (IR.HUMS.REC.1397.030).

Funding/Support: This study was supported by the Hormozgan University of Medical Sciences.

Patient Consent: Patients signed an informed consent form for participation.

References

- Ahmed M, Shaikh A, Fida M. Diagnostic performance of various cephalometric parameters for the assessment of vertical growth pattern. *Dental Press J Orthod.* 2016;**21**(4):41-9. doi: [10.1590/2177-6709.21.4.041-049.oar](#). [PubMed: [27653263](#)]. [PubMed Central: [PMC5029315](#)].
- Alshahrani I, Kamran MA, Alhaizaey A, Abumelha N. Evaluation of skeletal variations and establishment of Cephalometric Norms in Saudi Sub Population using Bjork Jarabak's analysis. *Pak J Med Sci.* 2018;**34**(5):1104-9. doi: [10.12669/pjms.345.15556](#). [PubMed: [30344558](#)]. [PubMed Central: [PMC6191777](#)].
- de Carvalho Rosas Gomes L, Horta KO, Gandini LG Jr, Goncalves M, Goncalves JR. Photographic assessment of cephalometric measurements. *Angle Orthod.* 2013;**83**(6):1049-58. doi: [10.2319/120712-925.1](#). [PubMed: [23597034](#)].
- Purmal K, Alam MK, Zam Zam N. Cephalometric norms of Malaysian adult Chinese. *Int Med J.* 2013;**20**(1):87-91.
- Ardani I, Sanjaya ML, Sjamsudin J. Cephalometric characteristic of skeletal class II malocclusion in Javanese population at Universitas Airlangga Dental Hospital. *Contemp Clin Dent.* 2018;**9**(Suppl 2):S342-6. doi: [10.4103/ccd.ccd_465_18](#). [PubMed: [30294169](#)]. [PubMed Central: [PMC6169297](#)].
- Wu JYC, Hagg U, Wong RWK, McGrath C. Comprehensive cephalometric analyses of 10 to 14-year old southern Chinese. *Open Anthropol J.* 2010;**3**(2):85-95. doi: [10.2174/1874912701003020085](#).
- Qamaruddin I, Shahid F, Firzok H, Maryam B, Tanwir A. Beta Angle: a cephalometric analysis performed in a sample of Pakistan population. *J Pak Dent Assoc.* 2012;**21**(4):206-9.
- Rodriguez-Cardenas YA, Arriola-Guillen LE, Flores-Mir C. Bjork-Jarabak cephalometric analysis on CBCT synthesized cephalograms with different dentofacial sagittal skeletal patterns. *Dental Press J Orthod.* 2014;**19**(6):46-53. doi: [10.1590/2176-9451.19.6.046-053.oar](#). [PubMed: [25628079](#)]. [PubMed Central: [PMC4347410](#)].

9. Al-Khawaja NF, Yassir YA, Nahidh M. Wits appraisal and Tweed triangle for a sample of Iraqi adults. *J Baghdad Coll Dent*. 2011;**23**(4):134-40.
10. Zhang X, Hans MG, Graham G, Kirchner HL, Redline S. Correlations between cephalometric and facial photographic measurements of craniofacial form. *Am J Orthod Dentofacial Orthop*. 2007;**131**(1):67-71. doi: [10.1016/j.ajodo.2005.02.033](https://doi.org/10.1016/j.ajodo.2005.02.033). [PubMed: [17208108](https://pubmed.ncbi.nlm.nih.gov/17208108/)].
11. Bittner C, Pancherz H. Facial morphology and malocclusions. *Am J Orthod Dentofacial Orthop*. 1990;**97**(4):308-15. doi: [10.1016/0889-5406\(90\)70103-J](https://doi.org/10.1016/0889-5406(90)70103-J). [PubMed: [2321597](https://pubmed.ncbi.nlm.nih.gov/2321597/)].