

## Endophthalmitis in *Farabi* Eye Hospital: A Review of 223 Cases

Mehdi Nili-AhmadAbadi, MD,<sup>1</sup> Fariba Ghasemi, MD,<sup>2</sup> Reza Karkhaneh, MD<sup>3</sup>  
Ahmad Mirshahi, MD,<sup>1</sup> Mohammad Riazi-Esfahani, MD,<sup>1</sup> Alireza Lashay, MD<sup>3</sup>  
Hooshang Faghihi, MD,<sup>1</sup> Mohammad-Reza Mansouri, MD<sup>4</sup>  
Ahmad Javadian, MD,<sup>3</sup> Morteza Movasat, MD,<sup>1</sup> Seyed-Ali Tabatabaei, MD<sup>4</sup>  
Mohammad-Sadegh Farahvash, MD,<sup>1</sup> Zahra Aalami-Harandi, MD,<sup>1</sup> Hormoz Chams, MD<sup>3</sup>

---

### Abstract

**Purpose:** To investigate etiological factors of endophthalmitis in *Farabi* Eye Hospital.

**Methods:** In a retrospective study, the clinical records of 223 patients admitted to the hospital with final diagnosis of endophthalmitis between March 2002 and March 2004 were reviewed. Analyzed factors included: age, sex, clinical presentation, clinical course, microbiological data, treatment modality, visual outcome, and surgical complications.

**Results:** Two hundred twenty three patients with final diagnosis of endophthalmitis were evaluated. One hundred and fifty patients (67%) were male and 73 (33%) were female. 50.2% of the patients were older than 40 years, 14.3% fall in the range of 17-40 years and 30.5% in the range of 2-16 years, and 4.9% were younger than 2 years of age. 57% of endophthalmitis cases were postoperative, 40.5% were posttraumatic, and 2.5% were endogenous. Overall 15.9% of the cases had positive culture. Wound leakage was noted in 39% and vitreous loss in 22% of postoperative patients. During 3.5–6.5 months (mean 4.5 months) visual acuity was  $20/400$  or better in 69.5% of posttraumatic cases and in 44.5% of postoperative patients. Finally 92.8% of patients required at least one vitrectomy procedure as a part of their management. Evisceration or enucleation was performed in 8.1% as a primary operation or in the course of their treatment.

**Conclusion:** The incidence of postoperative endophthalmitis in this study is similar to other studies. Posttraumatic endophthalmitis incidence is less than the mean incidence of other reports. The rate of positive culture was also less than other studies.

**Keywords:** Postoperative Endophthalmitis, Posttraumatic Endophthalmitis, Positive Culture

*Iranian Journal of Ophthalmology* 2006;19(3):9-13

---

- 
1. Associate Prof. of Ophthalmology, *Farabi* Eye Hospital, *Tehran* University of Medical Sciences
  2. Ophthalmologist
  3. Professor of Ophthalmology, *Farabi* Eye Hospital, *Tehran* University of Medical Sciences
  4. Assistant Prof. of Ophthalmology, *Farabi* Eye Hospital, *Tehran* University of Medical Sciences

Received: April, 3, 2006

Accepted: December 7, 2006

(With Cooperation of Eye Research Center, *Farabi* Eye Hospital, *Tehran* University of Medical Sciences)

---

Correspondence to:  
Mehdi Nili-AhmadAbadi, MD  
*Tehran, Farabi Eye Hospital*  
Tel: 55414941-6  
Email: [ma\\_nili@yahoo.com](mailto:ma_nili@yahoo.com)

## Introduction

Endophthalmitis is one of the catastrophic complications of ocular surgery, penetrating ocular trauma, and systemic infection and is a severe intraocular inflammation, predominantly involving the vitreous cavity and anterior chamber of the eye.<sup>1-4</sup> Contiguous ocular structures such as the retina or the choroid may also be involved.<sup>2-9</sup> Infectious endophthalmitis associated with infectious process is the most common form in which the internal structures of the eye are invaded by replicating microorganisms resulting in an inflammatory response that ultimately may involve all tissues of the eye.

Exogenous endophthalmitis occurs when eye wall has a break as a result of surgical intervention or trauma. Endogenous endophthalmitis is less common and occurs when the microorganisms spread to the eye from a source elsewhere in the body.<sup>10,11</sup> The most causative agents are bacteria, but fungi, parasites and viruses have also been implicated.<sup>10</sup> The majority of endophthalmitis cases occur after surgery and over 90% of all cases are caused by bacteria.<sup>3,6-9</sup>

Despite improved methods of prophylaxis and treatment, postoperative endophthalmitis remains a devastating complication of intraocular surgery.<sup>2-8</sup>

Less often a noninfectious stimulus such as retained lens material or a toxic substance entered into the eye during trauma or intraocular surgery may be responsible for the inflammatory response, resulting in sterile endophthalmitis.<sup>12,13</sup> Current study was undertaken to review the rate of endophthalmitis in different settings such as postoperative cases. Signs and symptoms, treatment modalities, and complications were also evaluated.

## Methods

In this retrospective study, 223 patients with final diagnosis of endophthalmitis from March 2002 to March 2004 were reviewed. Patients were admitted with diagnosis of postoperative, posttraumatic, bleb associated, endogenous, corneal ulcer induced endophthalmitis. All information data about age, sex categorized and cause of endophthalmitis, time of treatment, complications, anatomical and visual outcomes, isolated organisms and treatment modalities were gathered in special

forms. The extracted data were analyzed after being entered in to SPSS software and descriptive statistic measures were calculated.

## Results

In the period of study (March 2002 to March 2004), 223 patients with final diagnosis of endophthalmitis who were hospitalized in *Farabi* Eye Hospital, were enrolled. That of whom 150 (67%) were male and 73 (33%) were female. Of these endophthalmitis cases 128 patients (57%) were postoperative, 89 patients (40.5%) were posttraumatic, 6 patients (2.5%) were endogenous (Table 1). 50.2% of the patients were older than 40 years of age, 14.3% at the range of 17-40, 30.5% at the range of 2-16 and 4.9% were less than two years old. The common causes and the incidence of various types of endophthalmitis are depicted in tables 1, 2 respectively.

**Table 1.** Frequency of various types of endophthalmitis

Endophthalmitis	Frequency
Postoperative	128 (57%)
Posttraumatic	89 (40.5%)
Endogenous	6 (2.5%)

**Table 2.** Incidence of endophthalmitis

Endophthalmitis	Incidence (percentage)
Postoperative	57 in 39210 cases (0.145)
Post cataract surgery	35 in 17914 patients (0.195%)
Posttraumatic	88 in 2629 globe ruptures (3.3%)

The onset of endophthalmitis symptoms with pain was in 52% posttraumatic and with blurred vision in 44.5% of postoperative cases within 4 days. All patients with endophthalmitis received systemic antibiotics including cefazolin, gentamicin, vancomycin and/or amikacin, topical antibiotics and topical cycloplegics. Patients conventionally received intravitreal vancomycin (1 mg), amikacin (400 µg), and cefazolin (2.25 mg) and in 44% of

cases intravitreal dexamethasone was included, immediately after the cultures were obtained. Patients with fungal endophthalmitis received intraocular amphotericin-B (0.005 mg). If inflammation did not appear to be decreasing within two days or if the isolated organism was virulent, a repeated intraocular antibiotic injection was performed at 48 hours after the initial injection.

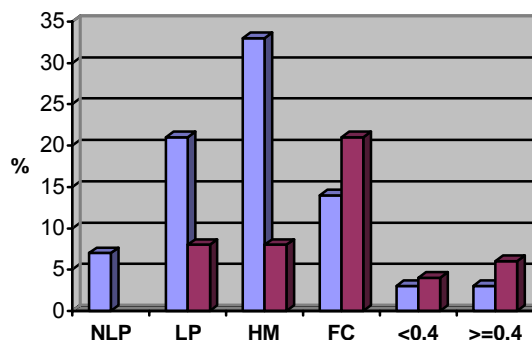
Thirty-five patients (15.7% of the cases) had positive bacterial culture. The microbial isolated result is presented in table 3. Wound leakages were noted at the time of diagnosis of endophthalmitis in 16 of 41 (39%) postcataract surgery cases. Vitreous loss as an intraoperative complication had occurred in 9 of 41 (22%) post cataract surgery endophthalmitis. There were 2 patients who presented infected necrotic wound margins. From 88 cases of posttraumatic patient 49 cases (56%) had corneal laceration and 62 cases (70.4%) had scleral laceration.

According to the examination results and retinal echography, the retina was attached in 53% of the cases. 92.8% of the patients required at least one vitrectomy procedure as a part of their management. Endogenous endophthalmitis that included in our series were due to indwelling devices in the body (2 cases endocarditis and 3 cases urinary system infections). Evisceration or enucleation procedure was performed in 8.1% as a primary operation or in the course of their treatment protocol.

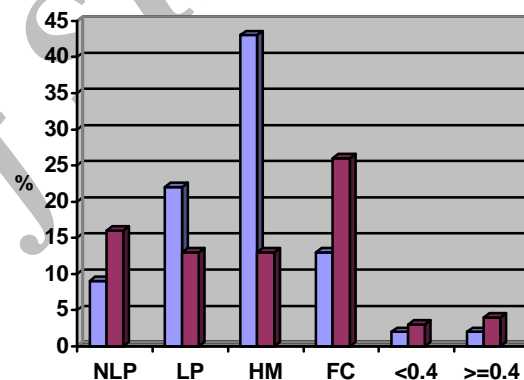
**Table 3.** Microbial isolates in microbial endophthalmitis

Isolates	Frequency
Staphylococcus aureous	8
Streptococcus viridans	8
Bacillus	7
Staphylococcus epidermidis	4
Pseudomonas	2
Staphylococcus spriphilicus	1
Citrobacter	1
Serratia marcesens	1
Enterococcus	1
Klebsiella	1
Pneumococcus	1

Final visual acuity during period of 3.5-6.5 months (mean 4.5 months) was  $20/400$  or better in 69.5% of posttraumatic cases and in 44.5% of postoperative patients [Figures 1, 2].



**Figure 1.** Visual outcome in posttraumatic endophthalmitis before and after treatment



**Figure 2.** Visual acuity in postoperative endophthalmitis before and after treatment

## Discussion

In our study, the onset of endophthalmitis symptoms with blurred vision was within four days postoperatively in 44.5% of cases. Previous studies demonstrate that presenting symptoms begin, in most cases within three days after operation, and blurred vision was the most common complain.<sup>6,14</sup> Endogenous endophthalmitis was the least common and occurred in six of our patient (2.5%), which is in accordance to other studies (2.8%).<sup>10,11</sup> Immunosuppressed patients and those with indwelling devices and drug abusers are susceptible to this type of endophthalmitis.<sup>10,11</sup> The most common etiologic agents were the opportunistic fungi such as *Candida albicans* but other microbiologic agents can be seen according to the inciting site of the infection.<sup>10</sup> Our findings in this study is in accordance with that the most common organism was *Candida albicans*. A striking observation in this study

was the high incidence of associated wound leakage which was observed in 39% of the cases and three of our patients developed endophthalmitis after suture removal highlighting the importance of careful technique in removing sutures. Loose sutures should be cut and removed in such a way that the exposed portion of the suture is not pulled through the wound. In other studies wound problem have been implicated in an increased rate of endophthalmitis.<sup>15-17</sup> In our study 22% had vitreous loss which is contributed to the development of endophthalmitis which is similar to other studies.<sup>18-20</sup> In our study visual acuity was  $20/400$  or better in 69.5% of the posttraumatic patients and 44.5% of the postoperative cases. In endophthalmitis vitrectomy study (EVS) 85% of the postoperative endophthalmitis patients achieved a final visual acuity of  $20/400$  or better; however, in posttraumatic endophthalmitis this visual acuity was obtained in only 22-42% of the cases. In another study, 54% of the traumatic cases achieved visual acuity of  $20/400$  or more.<sup>7</sup>

During the study; we found that 15.7% of the cases were culture positive which was less than other studies<sup>6,7</sup> and might be due to

the laboratory related problems or defected specimen delivery to laboratory. It should be noted that for the negative cultures, using other diagnostic methods such as PCR might be indicated. In our study the rate of posttraumatic endophthalmitis was 3.3% which was less than other studies.<sup>21,22</sup> It was probably due to another research which was done at the same time in *Farabi* Eye Hospital. That study showed that injection of 40 µg clindamycin and 40 µg gentamicin is effective significantly on prevention of endophthalmitis in patients with penetrating ocular trauma.<sup>23</sup>

The limitation of this study is inability to categorize the bacteriologic results with respect to the type of endophthalmitis, which was due to defects in medical records. This shortcomings should be considered in the future studies.

### Conclusion

The incidence of postoperative endophthalmitis was comparable to other studies, however the posttraumatic endophthalmitis incidence was less than the mean incidence of other reports and the rate of positive cultures was also less.

### References

1. Busbee BG. Advances in knowledge and treatment: an update on endophthalmitis. *Curr Opin Ophthalmol*. 2004 Jun;15(3):232-7.
2. Endophthalmitis Vitrectomy Study Group Results of the Endophthalmitis Vitrectomy Study. A randomized trial of immediate vitrectomy and of intravenous antibiotics for the treatment of postoperative bacterial endophthalmitis.. *Arch Ophthalmol*. 1995 Dec;113(12):1479-96.
3. Barza M, Pavan PR, Doff BH, Wisniewski SR, Wilson LA, Han DP, Kelsey SF. Evaluation of microbiological diagnostic techniques in postoperative endophthalmitis in the Endophthalmitis Vitrectomy Study. *Arch Ophthalmol*. 1997 Sep;115(9):1142-50.
4. Kaynak S, Oner FH, Kocak N, Cingil G. Surgical management of postoperative endophthalmitis: comparison of 2 techniques. *J Cataract Refract Surg*. 2003 May;29(5):966-9.
5. Aaberg TM Jr, Flynn HW Jr, Schiffman J, Newton J. Nosocomial acute-onset postoperative endophthalmitis survey. A 10-year review of incidence and outcomes. *Ophthalmology*. 1998 Jun;105(6):1004-10.
6. Allen HF, Mangiaracine AB. Bacterial endophthalmitis after cataract extraction. II. Incidence in 36,000 consecutive operations with special reference to preoperative topical antibiotics. *Arch Ophthalmol*. 1974 Jan;91(1):3-7. No abstract available.
7. Peyman GA. Causes of exogenous endophthalmitis in Peyman endophthalmitis diagnosis and management. I Ed London & New York Taylor & Francis 2004;137-155.
8. Peyman GA. Endogenous endophthalmitis in Peyman endophthalmitis diagnosis and management I Ed London & New York Taylor & Francis 2004;185-203.

9. Johnson MW, Doft BH, Kelsey SF, Barza M, Wilson LA, Barr CC, Wisniewski SR. The Endophthalmitis Vitrectomy Study. Relationship between clinical presentation and microbiologic spectrum. *Ophthalmology*. 1997 Feb;104(2):261-72.
10. Frantz JF, Lemp MA, Font RL, Stone R, Eisner E. Acute endogenous panophthalmitis caused by *Clostridium perfringens*. *Am J Ophthalmol* 1974;78:295-303.
11. Green MT, Font RL, Campbell JV, Marines HM. Endogenous *Clostridium* panophthalmitis. *Ophthalmology*. 1987 Apr;94(4):435-8.
12. Irvine WD, Flynn HW Jr, Murray TG, Rubsamen PE. Retained lens fragments after phacoemulsification manifesting as marked intraocular inflammation with hypopyon. *Am J Ophthalmol*. 1992 Nov 15;114(5):610-4.
13. Meltzer DW. Sterile hypopyon following intraocular lens surgery. *Arch Ophthalmol*. 1980 Jan;98(1):100-4.
14. Rowsey JJ, Jensen H, Sexton DJ. Clinical diagnosis of endophthalmitis. *Int Ophthalmol Clin*. 1987 Summer;27(2):82-8.
15. Gelender H. Bacterial endophthalmitis following cutting of sutures after cataract surgery. *Am J Ophthalmol*. 1982 Oct;94(4):528-33.
16. Stonecipher KG, Parmley VC, Jensen H, Rowsey JJ. Infectious endophthalmitis following sutureless cataract surgery. *Arch Ophthalmol*. 1991 Nov;109(11):1562-3.
17. Confino J, Brown SI. Bacterial endophthalmitis associated with exposed monofilament sutures following corneal transplantation. *Am J Ophthalmol*. 1985 Feb 15;99(2):111-3.
18. Beyer TL, O'Donnell FE, Goncalves V, Singh R. Role of the posterior capsule in the prevention of postoperative bacterial endophthalmitis: experimental primate studies and clinical implications. *Br J Ophthalmol*. 1985 Nov;69(11):841-6.
19. Lindstrom RL, Doughman DJ. Bacterial endophthalmitis associated with vitreous wick. *Ann Ophthalmol*. 1979 Nov;11(11):1775-8.
20. Menikoff JA, Speaker MG, Marmor M, Raskin EM. A case-control study of risk factors for postoperative endophthalmitis. *Ophthalmology*. 1991 Dec;98(12):1761-8.
21. Mieler WF, Ellis MK, Williams DF, Han DP. Retained intraocular foreign bodies and endophthalmitis. *Ophthalmology*. 1990 Nov;97(11):1532-8.
22. Azad R, Ravi K, Talwar D, Rajpal, Kumar N. Pars plana vitrectomy with or without silicone oil endotamponade in post-traumatic endophthalmitis. *Graefes Arch Clin Exp Ophthalmol*. 2003 Jun;41(6):478-83. Epub 2003 May 14.
23. Nili-AhmadAbadi M, Piri N, Movasat M, Fahghi H, Karkhaneh R, Lashay AR, et al. Prophylactic intraocular gentamicin and clindamycin in prevention of acute posttraumatic endophthalmitis after penetrating ocular injuries; A double masked randomized clinical trial. *Iranian Journal of Ophthalmology* 17(1), 2004;5-12.