

Scanning Laser Ophthalmoscopic Imaging of Acridine Orange-Stained Leukocytes in the Blood Vessels and Tissues of Neovascularized Rat Corneas

Bahram Khoobehi, PhD¹ • Hosam-A Ibrahim-Elzembely, MD¹ • Robert-L Grinstead, MPH¹

Abstract

Purpose: To image leukocyte adherence to the vascular endothelium and extravasation into surrounding tissues in neovascularized corneas using acridine orange, a selective DNA stain, in rats

Methods: Corneal neovascularization was induced by placing two sutures in the cornea of one eye of 12 Long-Evans rats. One week later, acridine orange (4 mg/kg) was injected via the tail vein and the eyes were evaluated using a scanning laser ophthalmoscope (SLO) 3-5 minutes, 20 minutes, and one hour after injection. Images were recorded on videotape for further analysis.

Results: Acridine orange staining showed adherent leukocytes in corneal vessels at 3-5 minutes post-injection. After 20 minutes, leukocytes were seen in the corneal vessels and in the surrounding tissues. At 1 hour post-injection, decreased number of leukocytes were visible in the tissues, but none were seen in the corneal vessels.

Conclusion: Acridine orange effectively demonstrate the leukocyte/endothelial interactions (leukocyte adherence) in the blood vessel, as well as leukocyte infiltration of surrounding tissues in neovascularized corneas. This technique may have prognostic value in corneal disease in which neovascularization is the pathologic component.

Keywords: Acridine Orange, Cornea, Imaging, leukocyte Staining, Neovascularization

Iranian Journal of Ophthalmology 2009;21(2):46-50 © 2009 by the Iranian Society of Ophthalmology

Introduction

Corneal neovascularization is a feature of a variety of corneal diseases. Inflammatory, traumatic, degenerative, and dystrophic corneal diseases are among the major causes of corneal neovascularization. Corneal neovascularization on the ocular surface may

impair vision and play a causative role in graft rejection.¹

Over the past 50 years, numerous investigators have studied the process of neovascularization using the cornea as a model.

1. LSU Eye Center, Louisiana State University Health Sciences Center, New Orleans, Louisiana

Received: January 12, 2009

Accepted: May 7, 2009

Correspondence to: Bahram Khoobehi, PhD

LSU Eye Center, Louisiana State University Health Sciences Center, New Orleans, Louisiana, Tel:+1 504-568-2405,

Email: bkhoob@lsuhsc.edu

In these studies, various methods were used to induce new blood vessel growth, including compacting tissue, anoxia, elimination of protease inhibitor activity, and manipulation of the immune system.²⁻⁸

In 1975, Fromer et al⁶ showed that polymorphonuclear leukocyte infiltration in the corneal stroma invariably precedes corneal neovascularization. The initial site of neovascular growth is linked to the location of leukocyte tissue infiltration (extravasation), preceding the formation of the neovessels.⁹ The quantity of leukocyte infiltration correlates with the degree of neovascular growth, which implies the causative relationship between PMNs and angiogenesis.⁶⁻⁸ Assessment of the amount of cellular infiltration may, therefore, be of prognostic value in corneal graft rejection in high-risk patients.

Becker et al¹ imaged corneal neovascularization using in vivo fluorescence microscopy in combination with Rhodamine 6G, a mitochondrial stain, for visualization of leukocytes and thrombocytes. In our study, we used a nucleic acid stain, acridine orange, to image infiltrating leukocytes during the corneal neovascularization process. Acridine orange is a DNA-specific nuclear stain. It has been shown useful in quantitative analysis and evaluation of behavior in retinal vessels by selectively staining of leukocytes,^{10,11} including increased adhesion of leukocytes in the retinal vessels of diabetic rats.¹² The purpose of our study was to visualize leukocytes adherent to the blood vessels of neovascularized corneas using acridine orange and the scanning laser ophthalmoscope (SLO), and also to confirm that this approach could be used to quantify leukocytes in neovascular vessels as a modality for use in further studies of the leukocyte-neovascularization relationship.

Methods

Animals

Twelve pigmented Long-Evans rats (2-3 grams body weight) were used. All animals were treated in accordance with the Association for Research in Vision and Ophthalmology Guidelines for the Use of Animals in Ophthalmic and Vision Research. For all procedures, the rats were anesthetized with an intramuscular injection of ketamine hydrochloride (50 mg/kg). The pupils were dilated with topically applied 2.5%

phenylephrine and 0.5% tropicamide. Topical anesthesia was achieved with 0.5% proparacaine hydrochloride. Euthanasia was performed with an intravenous dose of sodium pentobarbital (100 mg/kg).

Induction of corneal neovascularization

Baseline slit lamp biomicroscopic examinations were performed on all eyes. No central or peripheral corneal defects were found in any of the eyes used in the experiment. Corneal neovascularization was induced by placing two radially oriented, interrupted 10-0 polypropylene (Prolene) sutures in the upper 180° para-central zone of the cornea. Each suture was approximately 2 mm in length and at a depth of approximately three-quarters of the corneal thickness.

Corneal scanning laser ophthalmoscopic imaging

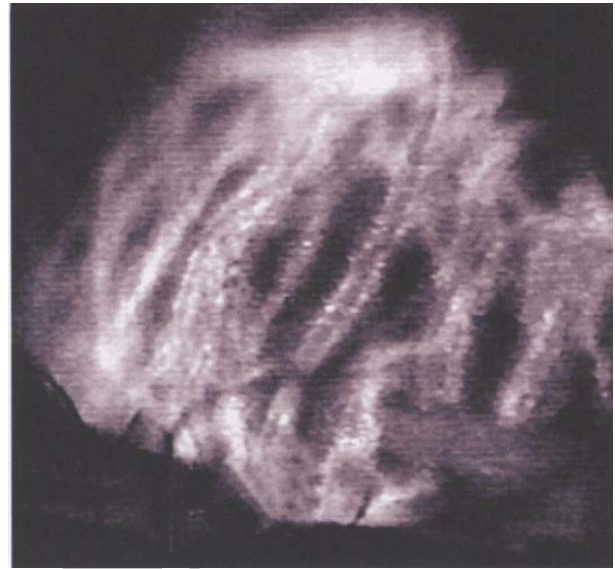
Acridine orange fluorescein angiography was performed at various intervals on 7, 11, and 14 days after the sutures were placed. On these days, granular acridine orange (Sigma Chemicals, St. Louis, MO) was dissolved in buffered saline solution at a concentration of 1 mg/ml, and injected into the tail vein of each rat at a dosage of 4 mg/kg and a rate of 1 mg/min. A SLO (Rodentstock Model 101, Ottobrun, Reimerling, Germany) with a fluorescein filter was used to obtain images of the cornea 3-5 minutes, 20 minutes, and 1 hour after the injection. To obtain the images, the rat was placed in front of an apparatus holding a 90-diopter lens (Volk; Designs for Vision Pty Ltd, Camperdown, NSW, Australia) mounted to an X, Y (translational and rotational) stage. The lens was oriented in front of the SLO so that the laser beam was focused on the cornea. Afterwards, the rat's eye was placed in a distance approximately 6 to 10 mm in front of the lens. The apparatus holding the lens and the animal were adjusted to provide the best possible focus. It was necessary to manually maneuver the head of the rat to bring the eye into focus and create a linear 90° angle to image the leukocytes in the area under observation. All images were videotaped for further analysis using a digital video recorder (GV-D300, Sony Corporation, Tokyo, Japan).

Results

Images of the corneal blood vessels and the surrounding tissues were recorded during the early (3-5 minutes post-injection) (Figure 1) and late (20 minutes and 1 hour post-injection) (Figure 2 and 3) phases of circulation of fluorescent leukocytes stained with acridine orange. Fluorescent cells, which initially appeared as hyperfluorescent points, were seen in the blood vessels after the initiation of the injection. Over the next 3 to 5 minutes, the numbers of fluorescent cells in the neovascular network increased markedly. After 20 minutes, static leukocytes were observed adherent to the vessel walls, and fluorescent cells were seen in the surrounding tissues. At 1 hour, a few extravasated leukocytes persisted in the tissues, but no fluorescent cells were seen in the corneal vessels.

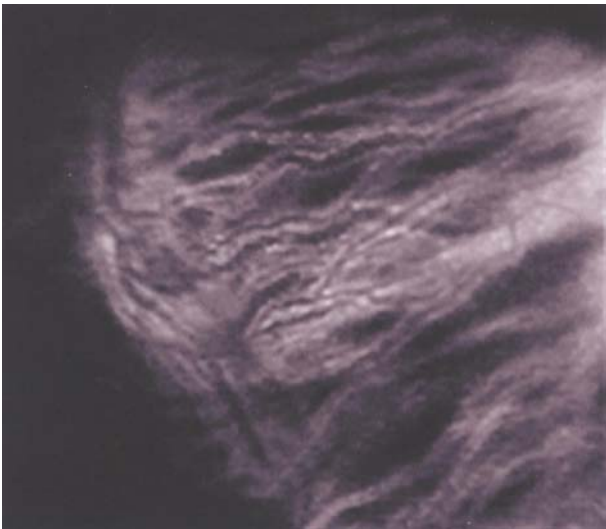

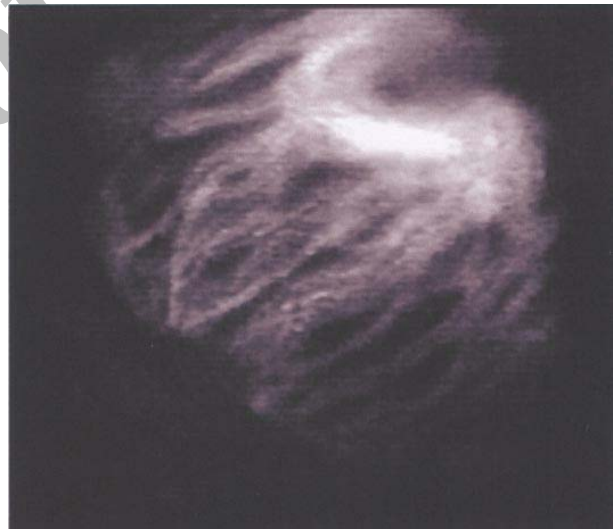Figure 1. Scanning laser ophthalmoscopy of the neovascularized cornea 3 to 5 minutes after intravenous injection of acridine orange (4 mg/kg body weight). Rodenstock scanning laser ophthalmoscope (SLO), 20° filed



A

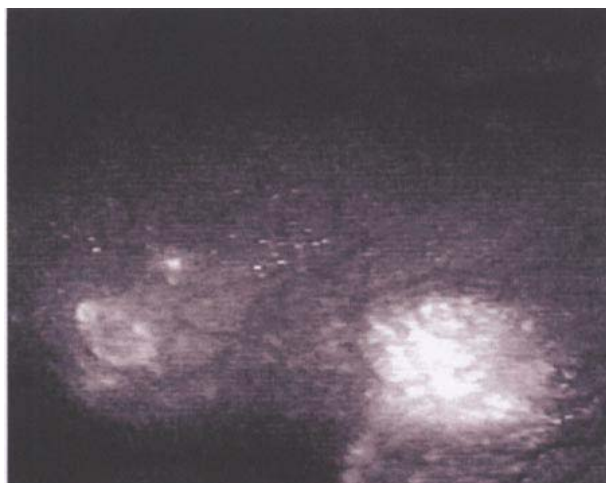


B

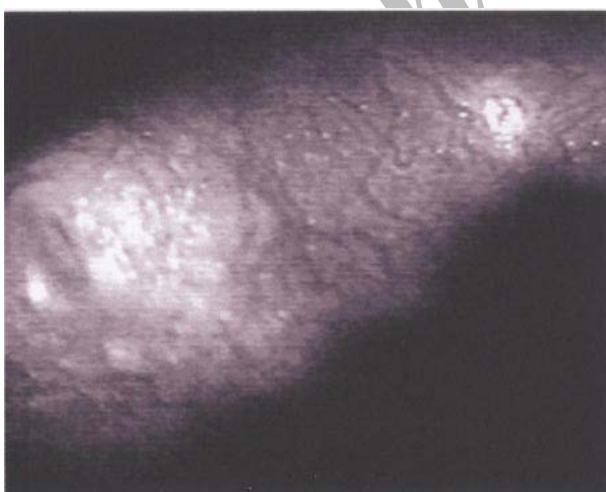
Figure 2. Scanning laser ophthalmoscopic image of the neovascularized cornea 20 minutes after intravenous injection of acridine orange (4 mg/kg body weight)
A. 7 days after placement of corneal sutures
B. 14 days after placement of corneal sutures



A



B



C

Figure 3. Scanning laser ophthalmoscopic image of the neovascularized cornea, one hour after intravenous injection of acridine orange (4 mg/kg body weight)
A. 7 days after placement of corneal sutures
B. 11 days after placement of corneal sutures
C. 14 days after placement of corneal sutures
Rodentstock scanning laser ophthalmoscope (SLO), 20° field

Discussion

This study demonstrates that acridine orange-stained leukocytes can be clearly seen as hyperfluorescent spots in the blood vessels and surrounding tissues of neovascularized corneas for up to 1 hour after injection of the dye. Thus, this technique may be useful to quantify and compare areas of corneal neovascularization in experimental studies and possibly in the clinical setting.

Images obtained at a specific time after injection could provide standard (control) values for numbers of leukocytes in the vessels (leukostasis density) and in the surrounding tissues (extravasation). Subsequently, such standards could be compared with similar data acquired in experimental subjects undergoing treatment for the prevention of neovascularization in various corneal disorders and conditions. In addition, the dynamics of the stained leukocytes in the blood vessels of the vascularized corneas could be examined with this technique. Hence, two types of parameters could be assessed: 1) leukostasis (number of stationary stained cells/unit area) and 2) hemodynamic parameters such as speed and blood flow to the area.

The ability to assess the neovascular area and the number of adherent leukocytes may also have prognostic application in corneal diseases. The effect of treatment for corneal inflammatory diseases could be investigated as well. In addition, corneal changes in various diseases causing leukopenia, leukocytosis, and even leukemia, and in response to the inflammatory agents used to treat these diseases could be assessed. Finally, graft rejection in previously vascularized, high-risk corneas could be evaluated for graft infiltration and vascularization. This would provide a sensitive prognostic tool for the potential survival of a corneal graft.

Conclusion

One limitation of the model is that the laser beam should be oriented perpendicular to the lens and corneal plane in order to minimize astigmatism and optical aberrations. For that reason, the technique would be most effective in subjects with flatter corneal curvatures and larger corneas, such as rabbits, monkeys, and humans. For routine use in studies employing

smaller animals, such as the rat, a modified optical system involving cylindrical or toric lenses may be more effective.

References

1. Becker MD, Kruse FE, Jousseaume AM, et al. In vivo fluorescence microscopy of corneal neovascularization. *Graefes Arch Clin Exp Ophthalmol* 1998;236(5):390-8.
2. Campbell FW, Michaelson IC. Blood vessel formation in the cornea. *Br J Ophthalmol* 1949;33(4):248-55.
3. Eliason JA. Leukocytes and experimental corneal vascularization. *Invest Ophthalmol Vis Sci* 1978;17(11):1087-95.
4. Friedlaender MH, Howes EL Jr, Hall JM, et al. Histopathology of delayed hypersensitivity reactions in the guinea pig uveal tract. *Invest Ophthalmol Vis Sci* 1978;17(4):327-35.
5. Schanzlin DJ, Cyr RJ, Friedlaender MH. Histopathology of corneal neovascularization. *Arch Ophthalmol* 1983;101(3):472-4.
6. Fromer CH, Klintworth GK. An evaluation of the role of leukocytes in the pathogenesis of experimentally induced corneal vascularization. I. Comparison of experimental models of corneal vascularization. *Am J Pathol* 1975;79(3):537-54.
7. Fromer CH, Klintworth GK. An evaluation of the role of leukocytes in the pathogenesis of experimentally induced corneal vascularization. II. Studies on the effect of leukocytic elimination on corneal vascularization. *Am J Pathol* 1975;81(3):531-44.
8. Fromer CH, Klintworth GK. An evaluation of the role of leukocytes in the pathogenesis of experimentally induced corneal vascularization. III. Studies related to the vasoproliferative capability of polymorphonuclear leukocytes and lymphocytes. *Am J Pathol* 1976;82(1):157-70.
9. Becker MD, Kruse FE, Azzam L, et al. In vivo significance of ICAM-1--dependent leukocyte adhesion in early corneal angiogenesis. *Invest Ophthalmol Vis Sci* 1999;40(3):612-8.
10. Nishiwaki H, Ogura Y, Kimura H, et al. Quantitative evaluation of leukocyte dynamics in retinal microcirculation. *Invest Ophthalmol Vis Sci* 1995;36(1):123-30.
11. Nishiwaki H, Ogura Y, Kimura H, et al. Visualization and quantitative analysis of leukocyte dynamics in retinal microcirculation of rats. *Invest Ophthalmol Vis Sci* 1996;37(7):1341-7.
12. Miyamoto K, Khosrof S, Bursell SE, et al. Prevention of leukostasis and vascular leakage in streptozotocin-induced diabetic retinopathy via intercellular adhesion molecule-1 inhibition. *Proc Natl Acad Sci* 1999;96(19):10836-41.