

# Sphenoid Sinus Mucocele: Report of a Unique Presentation and Partial Improvement of Vision from No Light Perception to Counting Fingers after Treatment

Mohammad Etezzad Razavi, MD<sup>1</sup> • Mohammad Khalifeh, MD<sup>2</sup>  
Mohammad Reza Ansari Astaneh, MD<sup>2</sup> • Marjan Mazuchi, MD<sup>2</sup>

---

## Abstract

**Purpose:** To report a patient with sphenoid sinus mucocele (SSM)

**Case report:** The patient is a 19-year-old man who was referred to Khatam-al-Anbia eye center as retrobulbar optic neuritis. Brain and orbital CT scan and MRI revealed SSM. The patient underwent endoscopic sinus surgery and visual acuity (VA) improved from no light perception (NLP) to 2 meter counting fingers.

**Conclusion:** SSM may have unique presenting symptoms. Even it may be considered as a differential diagnosis of optic neuritis and VA may be reversible after surgery.

**Keywords:** Sphenoid Sinus Mucocele, Paranasal Sinus Disease, Endoscopic Sinus Surgery, Sphenoid Sinus

*Iranian Journal of Ophthalmology 2010;22(2):77-80 © 2010 by the Iranian Society of Ophthalmology*

---

## Introduction

Since sphenoid sinus mucocele's first description in 1889, less than 150 cases have been reported in the literature.<sup>1,2</sup> Mucoceles are benign cyst like lesions lined with respiratory epithelium and encapsulated masses that may lead to destruction of bony structure surrounding it. Most prevalent location of sinus mucocele is frontal sinus and only 1% occurs in sphenoid sinus.<sup>2-4</sup>

Headache, orbital pain, decreased visual acuity (VA), visual loss, visual field defects, diplopia, oculomotor palsies, unilateral exophthalmia and endocrine disorders have been the clinical manifestations of sphenoid mucoceles in the previous case reports.

Sphenoid mucoceles causing altered vision have been rarely reported in ophthalmic literature. Herein we present a rare case of sphenoid sinus mucocele (SSM) causing unilateral visual loss in a patient with immediate partial recovery after surgery.

## Case report

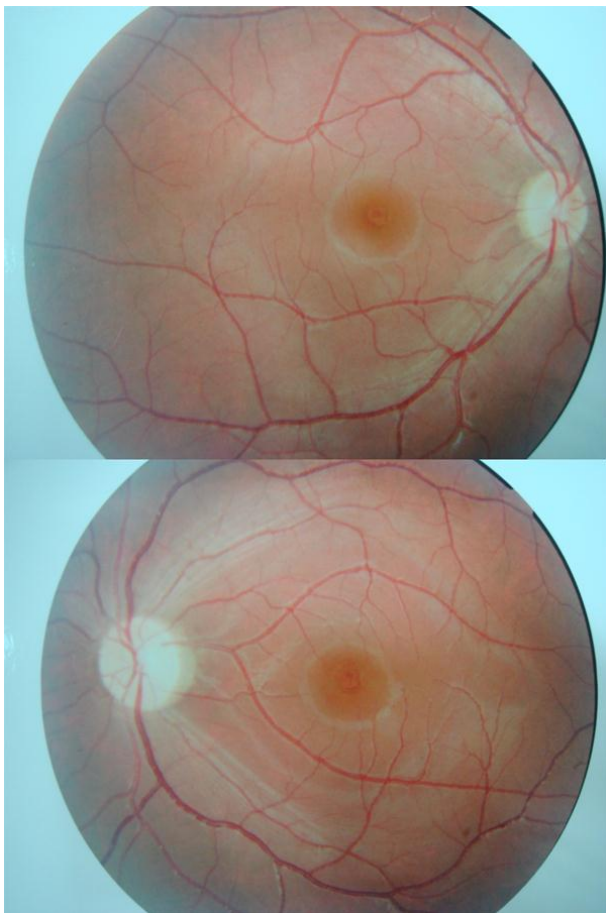
A 19 years old man was referred to khatam-al-Anbia eye center as a case of retrobulbar optic neuritis by a general ophthalmologist. The patient's symptoms had been started with headache and gradually decreased vision in his left eye since three months ago.

- 
1. Associate Professor of Ophthalmology, Eye Research Center, Khatam-al-Anbia Eye Hospital, Mashhad University of Medical Sciences
  2. Resident in Ophthalmology, Eye Research Center, Khatam-al-Anbia Eye Hospital, Mashhad University of Medical Sciences

Received: August 16, 2009  
Accepted: January 26, 2010

Correspondence to: Mohammad Reza Ansari Astaneh, MD  
Eye Research Center, Khatam-al-Anbia Eye Hospital, Mashhad, Iran, Tel:+98 511 7281401, Email: ansariamr851@mums.ac.ir

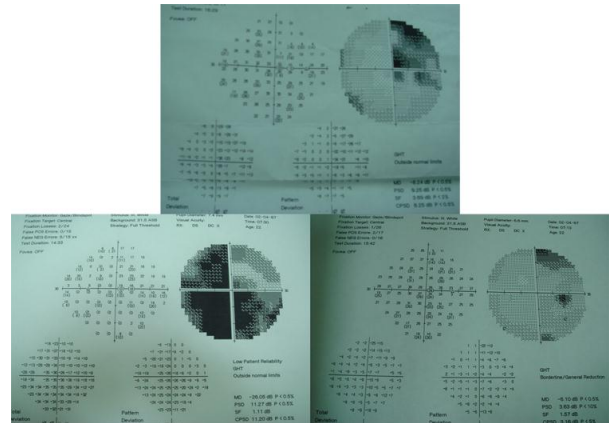
At presentation he was still suffering from headache; VA was  $10/10$  in the right eye and no light perception (NLP) in the left eye with nearly complete afferent pupillary defect of the affected eye. Other important findings were normal. Eye movements, painless palpation around left orbit, painless eye movements and no proptosis. Fundoscopy revealed complete optic nerve head paleness in the left eye and slight optic nerve head pallor in the right eye (Figure 1).



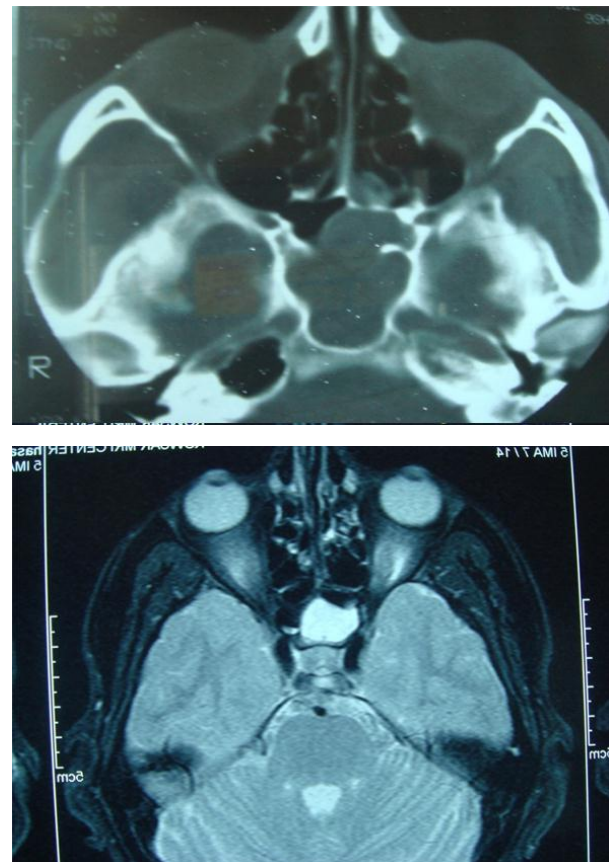
**Figure 1.** Fundus photograph of both eyes demonstrating a significant pale disc in the left eye

Automatic static quantitative perimetry (Octopus-500E) was taken and a right eye supra temporal field defect with respecting of vertical meridian was reported. The left eye could not plot perimetry (Figure 2). Because of the typical findings of perimetry, suggesting a chiasmatic lesion axial and coronal brain and orbital CT scan and MRI were demanded. On imaging slides (both CT and MRI) sphenoid sinus was filled with secretions which was clearly hyperintense in the T2 weighted MRI.

The lesion had an obvious compressive effect over anterior left visual pathways and mild effect on right visual pathways. No bone erosion observed and no intracranial or intraorbital extension was seen (Figure 3).



**Figure 2.** Perimetry 30-2 of right eye before surgery (up) and both eyes after surgery (down) Left eye did not plot before surgery and right eye demonstrated a supratemporal field defect. Improvement occurred after surgery in both eyes.



**Figure 3.** Brain CT scan and MRI of the patient There is a fullness of sphenoid sinus in CT scan and a high signal mass in T2 weighted MRI with compressive effect over adjacent tissues.

The patient was referred to an otolaryngologist due to SSM suspicion. A plan of trans-nasal surgical evacuation of the lesion was set and performed and pathology approval of previous SSM diagnosis was achieved. Ciliated columnar cells of the sphenoid sinus were replaced by cuboidal cells and the mucocele wall was composed of fibrous connective tissue. One day later, headache regressed markedly and VA of the left eye improved to CF 2 m. Central 30° perimetry was repeated and significant decrease in visual field defect of the right eye and mild improvement of the left eye was seen. No postoperative complications were observed. Postoperation brain and orbital MRI pointed out the empty sphenoid sinus space.

## Discussion

The total number of all reported sphenoid sinus lesions is now well more than 600.<sup>5</sup> SSM as an etiology is rare, and descriptions in the literature have appeared largely as case reports. Mucoceles of the sphenoid sinus represent 1–2% of all paranasal sinus mucoceles.<sup>2-4</sup>

Since the first report of SSM by Berg in 1889, nearly 130 cases of SSM have been documented, which included 69 (53%) males and 61 (47%) females ranging from 8 to 83 years old, but 48% of all cases have been 30 to 60 years old with no age or sex predominance. The state of the visual field has been mentioned in 84 cases and, it was restricted in 49 of them. The third cranial nerve has been one of the most commonly affected cranial nerves (<sup>40</sup>/<sub>130</sub> cases), while the IV nerve has been rarely involved (<sup>6</sup>/<sub>130</sub> cases). Exophthalmia has been reported in 25% and optical atrophy in 29% of the Cases.<sup>2</sup>

Progression of mucoceles is chronic without any specific symptoms that result from mechanical pressure on neighboring structures and/or involvement of nerves in the inflammatory process. The most common presenting features are headache, visual loss and palsies of the III and VI cranial nerves.<sup>2,6-8</sup> Although benign and rare, SSMs have been reported to involve the orbit and to cause visual loss, rarely including a bitemporal hemianopsia; therefore they are frequently

misdiagnosed as pituitary adenomas or chordoma.<sup>9</sup>

Clinical manifestation of optic nerve dysfunction include: decreased vision, afferent pupillary defect, pain on extraocular movements, central, centrocaecal or altitudinal field defect and disc changes such as pallor/edema. In general, the diagnosis of this disease tends to be delayed because patients seek examination only when they have subjective ophthalmologic symptoms.<sup>10</sup>

Diagnosis is based on history and on physical and imaging examinations (CT and MRI). On computed tomography and MRI, the lesion is frequently smooth, well-defined, usually hyperintense on T2- weighted MRI, and shows only peripheral contrast enhancement in the area of the hyper-vascular inflammatory tissue that lines the sinusal cavity. There is usually no intralesional enhancement and no calcification. Several cases of SSM showed low-intensity signal on both T1- and T2- weighted MRI. This is caused by dehydration of the inner contents.<sup>11,12</sup> The treatment of choice is the endonasal sphenoidotomy and drainage of the mucocele.<sup>6,13,14</sup>

The important differential diagnosis is primary necrotic adenoma in cases with significant intrasellar extension, craniopharyngioma, and chordoma. Infection, plasmacytoma, osteoma, osteoblastoma, basal cell and squamous cell carcinoma, rhinolith, polyps, and fibrous dysplasia should be also considered in the differential diagnosis of SSM.<sup>2,15</sup>

## Conclusion

The reversibility of visual loss in SSM has been reported in the literature as case reports. Early diagnosis and prompt surgical intervention enabled the vision to be restored.<sup>16,17</sup> The SSM as a differential diagnosis of optic neuritis has been reported in the literature only once.<sup>18</sup> The specific presentation of our patient with a severe visual loss and the form of visual field defects and very good and dramatic response to the treatment after surgery makes it a special case of sphenoid sinus mucocele.

**References**

---

1. Righini CA, Darouassi Y, Boubagra K, et al. [Sphenoid sinus mucocele of unusual aetiology and location]. *Rev Laryngol Otol Rhinol (Bord)* 2006;127(3):165-70.
2. Hejazi N, Witzmann A, Hassler W. Ocular manifestations of sphenoid mucoceles: clinical features and neurosurgical management of three cases and review of the literature. *Surg Neurol* 2001;56(5):338-43.
3. Close LG, O'Conner WE. Sphenoethmoidal mucoceles with intracranial extension. *Otolaryngol Head Neck Surg* 1983;91(4):350-7.
4. Roufail E, Briggs R, Tress B, Kaye AH. Sphenoid sinus mucocele presenting as complete ophthalmoplegia. *J Clin Neurosci* 2001;8(4):372-4.
5. Giovannetti F, Filiaci F, Ramieri V, Ungari C. Isolated sphenoid sinus mucocele: etiology and management. *J Craniofac Surg* 2008;19(5):1381-4.
6. Moriyama H, Hesaka H, Tachibana T, Honda Y. Mucoceles of ethmoid and sphenoid sinus with visual disturbance. *Arch Otolaryngol Head Neck Surg* 1992;118(2):142-6.
7. Moriyama H, Nakajima T, Honda Y. Studies on mucoceles of the ethmoid and sphenoid sinuses: analysis of 47 cases. *J Laryngol Otol* 1992;106(1):23-7.
8. Sethi DS. Isolated sphenoid lesions: diagnosis and management. *Otolaryngol Head Neck Surg* 1999;120(5):730-6.
9. Osborn AG, Johnson L, Roberts TS. Sphenoidal mucoceles with intracranial extension. *J Comput Assist Tomogr* 1979;3(3):335-8.
10. Kösling S, Hintner M, Brandt S, et al. Mucoceles of the sphenoid sinus. *European J of Radiol* 2004;51(1):1-5.
11. Yokoyama T, Inoue S, Imamura J, et al. Sphenoethmoidal mucoceles with intracranial extension-three case reports. *Neurol Med Chir (Tokyo)* 1996;36(11):822-8.
12. Lim CC, Dillon WP, McDermott MW. Mucocele involving the anterior clinoid process: MR and CT findings. *AJNR Am J Neuroradiol* 1999;20(2):287-90.
13. Benninger MS, Marks S. The endoscopic management of sphenoid and ethmoid mucoceles with orbital and intranasal extension. *Rhinology* 1995;33(3):157-61.
14. Gilain L, Aidan D, Coste A, Peynegre R. Functional endoscopic sinus surgery for isolated sinus disease. *Head Neck* 1994;16(5): 433-7.
15. Mewes T, Mann W. [Arachnoid cyst of sphenoid sinus]. *Laryngorhinootologie* 1998;77(2):107-10.
16. Nerurkar NK, Bradoo R, Muranjan S, Khare M. Sphenoid sinus mucocele with unilateral blindness. *Ann Otol Rhinol Laryngol* 2004;113(4):294-6.
17. Levy J, Monos T, Puterman M. Bilateral consecutive blindness due to sphenoid sinus mucocele with unilateral partial recovery. *Can J Ophthalmol* 2005;40(4):506-8.
18. Yasuda Y, Akiguchi I, Kimura J, Kameyama M. [Sphenoid sinus mucocele with recurrent visual disturbance]. *Rinsho Shinkeigaku* 1992;32(2):220-2.