

# Therapeutic Effect of Posterior Sub-Tenon Methyl Prednisolone in Anterior Ischemic Optic Neuropathy: A Randomized Clinical Trial

Hamid Fesharaki, MD<sup>1</sup> • Farzan Kianersi, MD<sup>1</sup> • Shahin Shoyoukhi, MD<sup>2</sup>

---

## Abstract

**Purpose:** To evaluate the therapeutic effect of posterior sub-tenon methyl prednisolone in anterior ischemic optic neuropathy, No class 1 study has shown any conclusive medical or surgical treatment for non-arteritic anterior ischemic optic neuropathy (NAION). Efficacy of systemic or intravitreal steroids was suggested by some studies. This study was performed to evaluate the efficacy and safety of posterior sub-tenon injection of methyl prednisolone in eyes with acute NAION.

**Methods:** In a double blind randomized clinical trial, forty patients with a recent onset NAION were randomly assigned into case and control groups. The case group received a single posterior sub-tenon injection of 40 mg methyl prednisolone; the control group received a sham injection. The patients had complete eye examination including visual field measurement and fluorescein angiography and systemic evaluation at the beginning. Eye examination was repeated at 2, 4, 6 and 8 week steps of the follow-up. Visual field was rechecked at the end of the follow-up. Statistical analysis used: SPSS 11.5 system, paired sample t-test; independent sample t-test,  $\chi^2$ , and ANOVA.

**Results:** Visual acuity (VA) improved 0.3 logMAR (three lines of Snellen chart) in the case group ( $P < 0.030$ ), no visual improvement was observed in the control group ( $P < 0.589$ ). Comparison between the two groups showed improvement in VA ( $P = 0.021$  at two weeks, and  $P = 0.053$  at 8 weeks), visual field pattern standard deviation (PSD), ( $P = 0.034$ ) and optic disc edema, ( $P = 0.000$ ) in the treatment group. No case of globe perforation or severe intraocular pressure (IOP) rise was detected.

**Conclusion:** Posterior sub-tenon injection of methyl prednisolone was preferred to observation in acute NAION.

**Keywords:** Non-Arthritic Anterior Ischemic Optic Neuropathy, Methyl Prednisolone, Posterior Sub-Tenon Injection

*Iranian Journal of Ophthalmology 2011;23(3):50-56 © 2011 by the Iranian Society of Ophthalmology*

---

- 
1. Associate Professor of Ophthalmology, Eye Research Center, Feiz Hospital, Isfahan University of Medical Sciences, Isfahan, Iran
  2. Ophthalmologist, Eye Research Center, Feiz Hospital, Isfahan University of Medical Sciences, Isfahan, Iran

Received: November 4, 2010

Accepted: August 15, 2011

Correspondence to: Hamid Fesharaki, MD

Associate Professor of Ophthalmology, Eye Research Center, Feiz Hospital, Isfahan University of Medical Sciences, Isfahan, Iran,  
Tel: +98 311 4450016, Email: h\_fesharaki@med.mui.ac.ir

## Introduction

No class 1 study has shown a conclusive medical or surgical treatment for non-arteritic anterior ischemic optic neuropathy (NAION).<sup>1,2</sup> Systemic use of corticosteroid was suggested by some authors for the treatment of NAION.<sup>3-5</sup> There are some studies on intravitreal injection of triamcinolone in small sample of patients with acute NAION,<sup>6-9</sup> relative improvement in vision and relative faster resolution of optic disc edema was claimed by few of these reports.<sup>6-8</sup> Sub-tenon injection of depot steroids has been safely used for the treatment of diabetic macular edema and macular edema secondary to retinal vein occlusion.<sup>10-15</sup> This study was performed to evaluate the efficacy and safety of posterior sub-tenon injection of methyl prednisolone in eyes with acute NAION.

## Methods

This randomized double masked clinical trial was performed on 42 patients with acute NAION. The patients were selected from the outpatient department of Feiz hospital, Esfahan, Iran during 2004-2006, and were randomly assigned in case and control groups.

The selected patients had a primary ocular and systemic evaluation including Snellen acuity, applanation tonometry, visual field measurement [Zeiss-Humphery], fluorescein angiography, Medical consultation, measurement of erythrocyte sedimentation rate (ESR), and measurement C reactive protein (CRP). The included patients had acute visual loss in one eye of within one week duration, optic disc edema, afferent pupillary defect, and optic discs leakage in fluorescein angiography. Patients with intraocular pressure (IOP) of more than 21 mmHg, a history of glaucoma, abnormal visual field in the sound eye, high ESR, high CRP, diabetic retinopathy, and any systemic or neurologic disease being related to the acute visual loss were not included. The exclusion criteria were considered for loss of follow-up or additional intervention during the follow-up period.

The course of the disease and its treatment modalities were explained for the patients. All included cases signed the informed consent after being informed about the possible risk

and benefits of the treatment mode in this study. The included patients were randomized into case and control groups. Simple randomization was performed according to the random allocation software.<sup>16</sup> The case group received a single posterior sub-tenon injection of 40 mg (1 cc) methyl prednisolone (Abooreyhan Company, Tehran, Iran) and the control group received a sham injection. The sham injection simulated the injection process of the case group; it included instillation of topical anesthetic drops, putting the patient behind the slit-lamp, insertion of lid speculum, aspiration of normal saline by syringe, and conducting the syringe toward the patient's eye without any material being actually injected.

All posterior sub-tenon and sham injections were performed by the second author. Posterior sub-tenon injections were performed according to the technique recommended by Nozik RA,<sup>17</sup> in the inferotemporal Quadrant.

After topical anesthesia by tetracain drops and insertion of the lid speculum, the patient was instructed to look up and nasally. A cotton swab soaked in tetracaine was applied over the conjunctiva at the site of injection, then the injection needle was inserted bevel-up against the sclera and advanced through the conjunctiva and tenon's capsule using a side-to-side movement to determine whether the needle has entered the sclera or not. As long as the globe did not torque with the side-to-side movement of the needle and once the needle was advanced to the hub the methyl prednisolone was injected into the sub-tenon's space.

Optic disc edema was diagnosed by slit-lamp ophthalmoscopy using +78 D lens. Preinjection and postinjection patient evaluations including the measurement of visual acuity (VA) was performed by the first author without having any information about the patient's group. Complete eye examination including VA, IOP, and ophthalmoscopic evaluation of optic disc was repeated at 2, 4, 6 and 8 week steps of follow-up. Visual field was rechecked at the end of the follow-up.

Primary values of VA were compared with its corresponding values during the follow-up inside each group and between the two groups. Primary and final values of visual field including mean deviation (MD), and pattern

standard deviation (PSD) were compared inside each group and between the two groups. Statistical analysis was performed by SPSS 11.5 system; independent sample t-test was performed to compare age, VA and visual field values before and after treatment between groups. Paired t-test was used to compare VA and visual field values before and after treatment inside each group.  $\chi^2$  was used to compare sex distribution. ANOVA was used to compare the improvement of VA and visual field between the two groups. P-values less than 0.05 (95% CI) were considered significant.

## Results

Forty patients completed the study course. Demographic characteristics of the patients are shown in table 1. The mean of VA improved 0.3 logMAR (three lines of snellen chart) from  $1.0 \pm 0.70$  logMAR [ $^{22}/_{200}$  (CF at 1 meter -  $^{20}/_{30}$ )] to  $0.7 \pm 0.55$  logMAR [ $^{42}/_{200}$  (CF at 1 meter -  $^{20}/_{25}$ )] in the treatment group ( $P < 0.030$ ), the mean of VA did not have a sensible change in the observation group, it changed from  $0.90 \pm 0.6$  [ $^{26}/_{200}$  (CF at 0.5 meter -  $^{20}/_{30}$ )] to  $0.9 \pm 0.6$  logMAR [ $^{25.5}/_{200}$  (CF 1 meter -  $^{20}/_{25}$ )] ( $P < 0.589$ ).

The mean values of VA in the case and control groups at all of the follow-up steps are shown in figure 1. The visual improvement in the treatment group was mainly obtained within the first two weeks of follow-up with no statistically significant further improvement from 2 to 8 weeks. Comparison between the two groups showed improvement of VA in the case group (ANOVA,  $P < 0.021$  at two weeks,

and ANOVA,  $P < 0.053$  at 8 weeks).

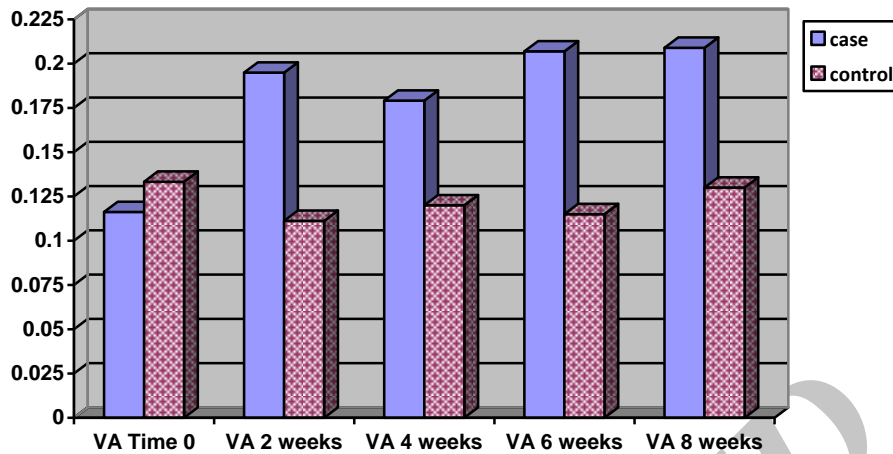
The visual field MD improved from  $-24.48 \pm 4.45$  (-17.03 to -30.78) dB to  $-22.02 \pm 4.41$  (-16.06 to -29.81) dB in the case group ( $P = 0.04$ ). The visual field MD did not show a sensible change in the sham group, it changed from  $-22.74 \pm 5.34$  (-15.52 to -29.98) dB to  $-22.63 \pm 4.04$  (-13.01 to -28.76) dB ( $P < 0.457$ ). Comparison between the two groups for the MD was not statistically significant (ANOVA,  $P < 0.110$ ). PSD improved from  $12.29 \pm 4.59$  (4.72-18.62) dB to  $11.09 \pm 4.48$  (5.93-20.12) dB in the case group which was not statistically significant ( $P < 0.140$ ). PSD deteriorated significantly from  $10.38 \pm 3.76$  (4.00-15.71) dB to  $12.87 \pm 4.00$  (4.83-15.78) dB in the control group ( $P < 0.049$ ). Comparison between the two groups for the PSD was found to be statistically significant (ANOVA,  $P < 0.034$ ). MD and PSD mean values of the two groups are shown in figure 2.

The mean time for the resolution of optic disc edema was  $2.8 \pm 1.00$  (2-4) weeks in the case group and  $6.5 \pm 1.27$  (4-8) weeks in the control group ( $P < 0.000$ ). Ophthalmoscopic evaluation at the 2 weeks step of follow-up showed marked reduction in optic disc edema in 50% of the case group and none of the control group. 55.5% of the case group and 16.6% of the control group expressed a subjective improvement in their vision at the end of this study ( $P < 0.000$ ). IOP rise exceeding 21 mmHg was observed in two patients in the case group which was controlled by antiglaucoma drops. No case of globe perforation was detected.

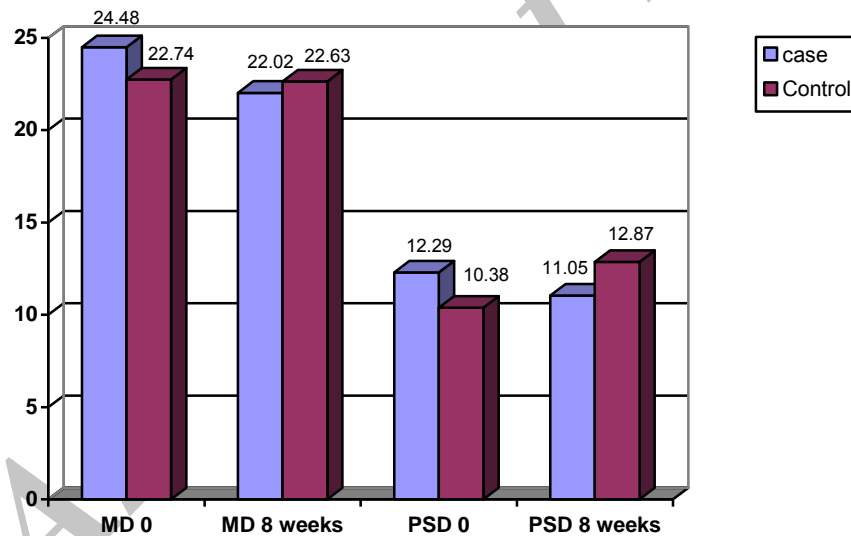
**Table 1.** Baseline demographic characteristics of the study groups

	Case (20 patients)	Control (20 patients)	P
Number of Females	11	9	0.33
Number of Males	9	11	0.33
Age	$59.77 \pm 8.78$ (43-75)	$57.00 \pm 9.38$ (37-73)	0.183
Duration of NAION (days)	$3.350 \pm 1.59$ (1-7)	$3.450 \pm 1.46$ (1-7)	0.837
Hypertensive	70%	80%	0.500
Diabetic	25%	20%	0.705
Snellen acuity at time 0	$1.0 \pm 0.7$ logMAR (22/200, CF at 1 meter-20/30)	$0.90 \pm 0.6$ logMAR (26/200, CF at 0.5 meter-20/30)	0.162
Mean deviation at time 0	$-24.48 \pm 4.45$ (17.03-30.78) dB	$-22.74 \pm 5.34$ (15.52-29.98) dB	0.145
Pattern standard deviation at time 0	$12.29 \pm 4.59$ (4.72-18.62) dB	$10.38 \pm 3.76$ (4.00-15.71) dB	0.06

NAION: Non-arteritic anterior ischemic optic neuropathy



**Figure 1.** Mean values of visual acuity in case and control at the beginning and at the follow-up steps of this study



**Figure 2.** Mean decibel values of mean deviation and pattern standard deviation in case and control groups

## Discussion

The results of this study showed that posterior sub-tenon injection of methyl prednisolone improved VA, visual field PSD, and optic disc edema in eyes with acute NAION. The mean of visual improvement in the treatment group was 0.3 logMAR (three lines of Snellen chart) which was mainly obtained at 2 weeks after injection and had no significant change then after. On the other hand no sensible change in VA was observed in the sham group. VA in

the sham group showed a mean deterioration of 0.1 logMAR at the two week step of follow-up and then returned back to its base during the following weeks. Statistical comparison for the extent of visual improvement between the two groups at the end of the study showed a marginal significance (ANOVA,  $P < 0.053$ ) which could have probably turned significant if larger number of cases were studied. Indeed 3 line

difference in Snellen acuity improvement between the two groups can be considered to be clinically significant<sup>2,5</sup> by the way significantly higher rate of subjective visual improvement was expressed by the case group of this study.

Improvement in VA was obtained after using systemic steroids for the treatment of NAION.<sup>3-5</sup> Hayreh et al found that NAION eyes treated during the acute phase (within two weeks) with systemic corticosteroids resulted in a significantly higher probability of improvement in VA.<sup>5</sup> Visual improvement was obtained in three previous reports employing intravitreal injection of triamcinolone in acute NAION.<sup>6-8</sup> Kaderli et al used intravitreal triamcinolone in acute NAION and found its maximum treatment effect at 3 weeks postinjection, with no further significant visual improvement from 3 weeks to 12 months.

Scanning laser polarimetry documented progressive loss of nerve fiber layer tissue during the first 3 weeks in a patient with NAION.<sup>18</sup> Study on animal models suggested that apoptosis of retinal ganglion cells occurs maximally in the second to third week after infarct.<sup>19</sup>

There was a statistically significant difference between the two groups in regard to the visual field PSD showing some improvement in the case and deterioration in the control group, could it be in correlation with the segmental involvement of the optic nerve in NAION. Visual field MD showed statistically significant improvement inside the case group. The clinical value of these statistical differences is not exactly clear.

Visual field improvement was reported by Hayreh et al using systemic corticosteroids for acute NAION, they found improvement of visual field in both groups of systemic steroid therapy and observation but significantly more improvement was found in their treated group.<sup>5</sup>

One objective finding of this study was faster resolution of optic disc edema in the treatment group. According to Hayreh et al optic disc edema is an initial sign of NAION, and corticosteroid therapy is required only for the duration of optic disc edema.<sup>20</sup> Faster resolution of optic disc edema was also found by other authors using intravitreal steroids for the treatment of NAION.<sup>6-8</sup>

Reduction of optic disc edema may slow down the vicious cycle of ischemia, and compartment syndrome and therefore prevent from further optic nerve damage. The extent of visual recovery after corticosteroid therapy in NAION might depend on the severity of tissue infarction at the time of therapy. A recent study utilizing optical coherence tomography in eyes with NAION demonstrated that 8 of 76 patients examined within 4 weeks of visual loss had subfoveal fluid, likely responsible for some of the reversible visual loss.<sup>21</sup>

Improvement of VA and reduction of disc edema in the case group along with deterioration of VA in the sham group at the two weeks follow-up step of this study can be attributed to the therapeutic effect of sub-tenon methyl prednisolone, this also confirms the previous clinical finding of progressive visual loss over 2 weeks following NAION and indeed the importance of early treatment in NAION.

No visual improvement in the observation group of this study has some conflict with the results of two prospective large studies showing spontaneous VA improvement in eyes with NAION.<sup>22-23</sup> Spontaneous recovery of three Snellen VA lines has been reported by ischemic optic neuropathy decompression trial (IONDT) in 31% of patients after 2 years.<sup>22</sup> By the way some factors like shorter follow-up period, smaller study population, and the initial VA of  $\leq 20/200$  in 60% of the patients could have affected the results of this study. On the other hand it is believed that after stabilization of vision, usually within two month, recurrence or progressive visual loss in an affected eye is extremely unusual.<sup>24</sup> As mentioned in the literature optic disc becomes visibly atrophic within 4-8 weeks; persistence of edema past this point suggests an alternative diagnosis, and untreated NAION generally remains stable after reaching the low point of visual function.<sup>25</sup>

Posterior sub-tenon injection of depot steroids have been safely used for the treatment of diabetic macular edema and macular edema secondary to retinal vein occlusion,<sup>10-15</sup> its main complication was reported to be intraocular pressure rise. IOP rise after sub-tenon injection of triamcinolone in eyes with diabetic macular edema was reported as -15.5%.<sup>10-13</sup>

Posterior sub-tenon injection may be found to be difficult by some surgeons, and there may be a fear from damage to the globe. On the other hand intravitreal injection carries the danger of endophthalmitis and cataract development. Systemic use of corticosteroids is accompanied by systemic side effects.

### **Conclusion**

According to the results of this study posterior sub-tenon injection of methyl prednisolone

was safe, and was preferred to observation in regard to the recovery of vision, indeed the extent of visual improvement in the case group of this study may be considered to be mild from the clinical point of view.

### **Acknowledgment**

From Mehdi Tazhibi, PhD, department of statistics, Isfahan university of medical sciences

### **References**

1. Atkins EJ, Bruce BB, Newman NJ, Biousse V. Treatment of nonarteritic anterior ischemic optic neuropathy. *Surv Ophthalmol* 2010;55(1):47-63.
2. Lin MC, Hsu FM, Sheu SJ. Nonarteritic ischemic optic neuropathy. *J Chin Med Assoc* 2007;70(2):61-4.
3. Hayreh SS. Anterior ischaemic optic neuropathy. III. Treatment, prophylaxis, and differential diagnosis. *Br J Ophthalmol* 1974;58(12):981-9.
4. Nicoară S, Macarie S, Vulpe V, Pop R. [Anterior ischemic optic neuropathy. The experience of 71 cases]. *Oftalmologia* 1995;39(2):125-9.
5. Hayreh SS, Zimmerman MB. Non-arteritic anterior ischemic optic neuropathy: role of systemic corticosteroid therapy. *Graefes Arch Clin Exp Ophthalmol* 2008;246(7):1029-46.
6. Kaderli B, Avci R, Yucel A, et al. Intravitreal triamcinolone improves recovery of visual acuity in nonarteritic anterior ischemic optic neuropathy. *J Neuroophthalmol* 2007;27(3):164-8.
7. Sohn BJ, Chun BY, Kwon JY. The effect of an intravitreal triamcinolone acetonide injection for acute nonarteritic anterior ischemic optic neuropathy. *Korean J Ophthalmol* 2009;23(1):59-61.
8. Yaman A, Selver OB, Saatci AO, Soylev MF. Intravitreal triamcinolone acetonide injection for acute non-arteritic anterior ischaemic optic neuropathy. *Clin Exp Optom* 2008;91(6):561-4.
9. Jonas JB, Spandau UH, Harder B, Sauder G. Intravitreal triamcinolone acetonide for treatment of acute nonarteritic anterior ischemic optic neuropathy. *Graefes Arch Clin Exp Ophthalmol* 2007;245(5):749-50.
10. Cellini M, Pazzaglia A, Zamparini E, et al. Intravitreal vs. subtenon triamcinolone acetonide for the treatment of diabetic cystoid macular edema. *BMC Ophthalmol* 2008;8:5.
11. Bakri SJ, Kaiser PK. Posterior subtenon triamcinolone acetonide for refractory diabetic macular edema. *Am J Ophthalmol* 2005;139(2):290-4.
12. Diabetic Retinopathy Clinical Research Network, Chew E, Strauber S, et al. Randomized trial of peribulbar triamcinolone acetonide with and without focal photocoagulation for mild diabetic macular edema: a pilot study. *Ophthalmology* 2007;114(6):1190-6.
13. Dahr SS, Rosenthal J, Gilmer W, et al. Anterior subtenon's triamcinolone acetonide (ASTA) injection for the treatment of diabetic macular edema: 4 to 6 month clinical followup. *Invest Ophthalmol Vis Sci* 2005;46:E-Abstract 1431.
14. Ozdek S, Deren YT, Gurelik G, Hasanreisoglu B. Posterior subtenon triamcinolone, intravitreal triamcinolone and grid laser photocoagulation for the treatment of macular edema in branch retinal vein occlusion. *Ophthalmic Res* 2008;40(1):26-31.
15. Lin JM, Chiu YT, Hung PT, Tsai YY. Early treatment of severe cystoid macular edema in central retinal vein occlusion with posterior sub-tenon triamcinolone acetonide. *Retina* 2007;27(2):180-9.
16. Saghaei M. Random allocation software for parallel group randomized trials. *BMC Med Res Methodol* 2004;4:26.
17. Nozik RA. Periocular injection of steroids. *Trans Am Acad Ophthalmol Otolaryngol* 1972;76(3):695-705.

18. Colen TP, van Everdingen JA, Lemij HG. Axonal loss in a patient with anterior ischemic optic neuropathy as measured with scanning laser polarimetry. *Am J Ophthalmol* 2000;130(6):847-50.
19. Slater BJ, Mehrabian Z, Guo Y, et al. Rodent anterior ischemic optic neuropathy (rAION) induces regional retinal ganglion cell apoptosis with a unique temporal pattern. *Invest Ophthalmol Vis Sci* 2008;49(8):3671-6.
20. Hayreh SS, Zimmerman MB. Optic disc edema in non-arteritic anterior ischemic optic neuropathy. *Graefes Arch Clin Exp Ophthalmol* 2007;245(8):1107-21.
21. Hedges TR 3rd, Vuong LN, Gonzalez-Garcia AO, et al. Subretinal fluid from anterior ischemic optic neuropathy demonstrated by optical coherence tomography. *Arch Ophthalmol* 2008;126(6):812-5.
22. Optic nerve decompression surgery for nonarteritic anterior ischemic optic neuropathy (NAION) is not effective and may be harmful. The Ischemic Optic Neuropathy Decompression Trial Research Group. *JAMA* 1995;273(8):625-32.
23. Hayreh SS, Zimmerman MB. Nonarteritic anterior ischemic optic neuropathy: natural history of visual outcome. *Ophthalmology* 2008;115(2):298-305.
24. Miller NR, Newman NJ, Biouesse V, Kerrison JB. Walsh and Hoyt's Clinical Neuro-Ophthalmology: The Essentials, 2nd ed. Wolters Kluwer, Lippincott, Williams & Wilkins, 2008;168.
25. Basic and Clinical Science Course. Neuro-Ophthalmology, section 5, American Academy of Ophthalmology, 2009-2010;126-7.

Archive of SID