



SID

Available online at www.sciencedirect.com

ScienceDirect

Journal of Current Ophthalmology 30 (2018) 91–96

<http://www.journals.elsevier.com/journal-of-current-ophthalmology>

Case report

Fungal keratitis caused by rare organisms

Seyed Ali Tabatabaei^a, Mehdi Tabatabaei^a, Mohammad Soleimani^{a,*}, Zahra Fallah Tafti^b^a Eye Research Center, Farabi Eye Hospital, Tehran University of Medical Sciences, Tehran, Iran^b Razi Eye Clinic, Tehran, Iran

Received 26 December 2016; revised 2 August 2017; accepted 4 August 2017

Available online 26 August 2017

Abstract

Purpose: To report two rare cases of filamentous fungal keratitis.

Methods: Two non-consecutive patients presented with suspicious fungal keratitis. After performing the smear and culture, medical therapy was started for them. They underwent slit photography and in vivo confocal microscopy (IVCM) in their follow-up visits.

Results: The patients were 33-year-old and 56-year-old farmer men. They both mentioned a history of ocular trauma by plants. During their follow-up visits, corneal infiltration density and fungal hyphae density decreased in slit-lamp biomicroscopy and IVCM, respectively. The corresponding organisms were *Pseudallescheria boydii* (*P. boydii*) and *Colletotrichum coccodes*.

Conclusions: It is important to be aware of these rare organisms and their antibiotic susceptibility. There was not any specific confocal feature for the presented fungal keratitis that was different from other filamentous fungal hyphae; however, confocal scan is a good choice to follow the response to the treatment.

Copyright © 2018, Iranian Society of Ophthalmology. Production and hosting by Elsevier B.V. This is an open access article under the CC BY-NC-ND license (<http://creativecommons.org/licenses/by-nc-nd/4.0/>).

Keywords: Fungal keratitis; *Pseudallescheria boydii*; *Colletotrichum coccodes*

Introduction

Microbial keratitis is one of the major causes of ocular morbidity and a potentially leading cause of blindness. It is reported that in warm, tropical climates, 30–62% of all microbial keratitis cases are caused by fungi,^{1–3} but they are rare in regions with temperate climates.⁴ Trauma with plants is one of the main predisposing factors in fungal keratitis.^{1–4} Common causes include *Candida* spp., *Fusarium* spp., and *Aspergillus* spp.⁵

The standard diagnostic methods for infectious keratitis, including fungal keratitis, are corneal smear and culture. However, it may take several days to obtain the result of a corneal culture from a patient with suspicious fungal keratitis. On the other hand, the result could be negative in cases with deep infiltrates.⁶ It is obvious that the sooner diagnosis of causative agent, the better the prognosis.

In clinical examination, they are usually determined by gray-white infiltrates and satellite lesions with feathery borders, but it is not a perennial finding.

Considering long time to obtain culture results and variable clinical pictures, it is wise to use other diagnostic methods such as in vivo confocal microscopy (IVCM) with the resolution of 1 μm.^{7,8} This resolution is enough to show fungal hyphae that are larger than a micrometer. IVCM is useful in diagnosis, management, and follow-up of patients with fungal keratitis.⁹

In this report, we report two patients with fungal keratitis caused by rare molds.

Case reports

Case 1

A 33-year-old male farmer was referred to our emergency department with the impression of microbial keratitis. He mentioned a history of ocular trauma with herbal material 5 days earlier.

Conflicts of interest and source of funding: None.

* Corresponding author.

E-mail address: Soleimani_md@yahoo.com (M. Soleimani).

Peer review under responsibility of the Iranian Society of Ophthalmology.

<http://dx.doi.org/10.1016/j.joco.2017.08.004>

2452-2325/ Copyright © 2018, Iranian Society of Ophthalmology. Production and hosting by Elsevier B.V. This is an open access article under the CC BY-NC-ND license (<http://creativecommons.org/licenses/by-nc-nd/4.0/>).

www.SID.ir

On clinical examination, his best corrected visual acuity without any glasses was counting fingers from 50 cm. On slit-lamp biomicroscopy, he had a superficial corneal infiltration with epithelial defect and feathery border. Its diameter was 5 mm, and there was a deeper infiltration with 6.5 mm diameters of infiltration (Fig. 1). Corneal scraping was done with a surgical blade, and mycelium was seen. Samples were taken on sabouraud agar, blood agar, and chocolate agar media and were sent to laboratory for culture and defining the organism.

Based on clinical picture and the result of corneal scraping fortified topical voriconazole, topical levofloxacin and oral itraconazole 100 mg were started hourly, then every 4 hours and every 12 hours for the patient, respectively. Clinical signs and symptoms of the patients improved with medical therapy. Considering clinical improvement, the anti-microbial therapy was tapered down, and non-preserved lubricating agents were added.

20 days after initiating medication, the patient developed a 1.5 mm hypopyon, but the corneal infiltration was reducing. Despite formation of the hypopyon, medical regimen was not change. The patient underwent IVCM (Heidelberg engineering, Heidelberg, Germany) weekly. He had hyper-reflective linear, branching and interlocking structures typical of fungal hyphae in IVCM that reduced in density with therapy

(Fig. 2). When the patient developed hypopyon, the density of hyphae in IVCM was just reducing. Seven days after corneal sampling, the organism was defined by culture, and it was *Pseudallescheria boydii* (*P. boydii*). The topical voriconazole was tapered from hourly in the first week to every six hours in the fifth week, when it was discontinued because of resolving the infiltration and scar formation. Systemic itraconazole was discontinued after two weeks.

Case 2

A 56-year-old male farmer came to our emergency department with chief complaint of ocular pain and burning. He had minimal ocular trauma with rice plant one week earlier. He was not a contact lens user.

His best corrected visual acuity was 20/40 without glasses. On slit-lamp biomicroscopy he had conjunctival injection, and there was an area of corneal infiltration in infranasal quadrant with gritty appearance and feathery border. The diameter of infiltration was 3.5*2 mm (Fig. 3). In corneal scraping samples that were obtained with surgical blade, mycelium was seen. Topical natamycin every 1 hour and topical levofloxacin every 4 hours were started for the patient with the impression of fungal keratitis. Clinical signs and symptoms were improved

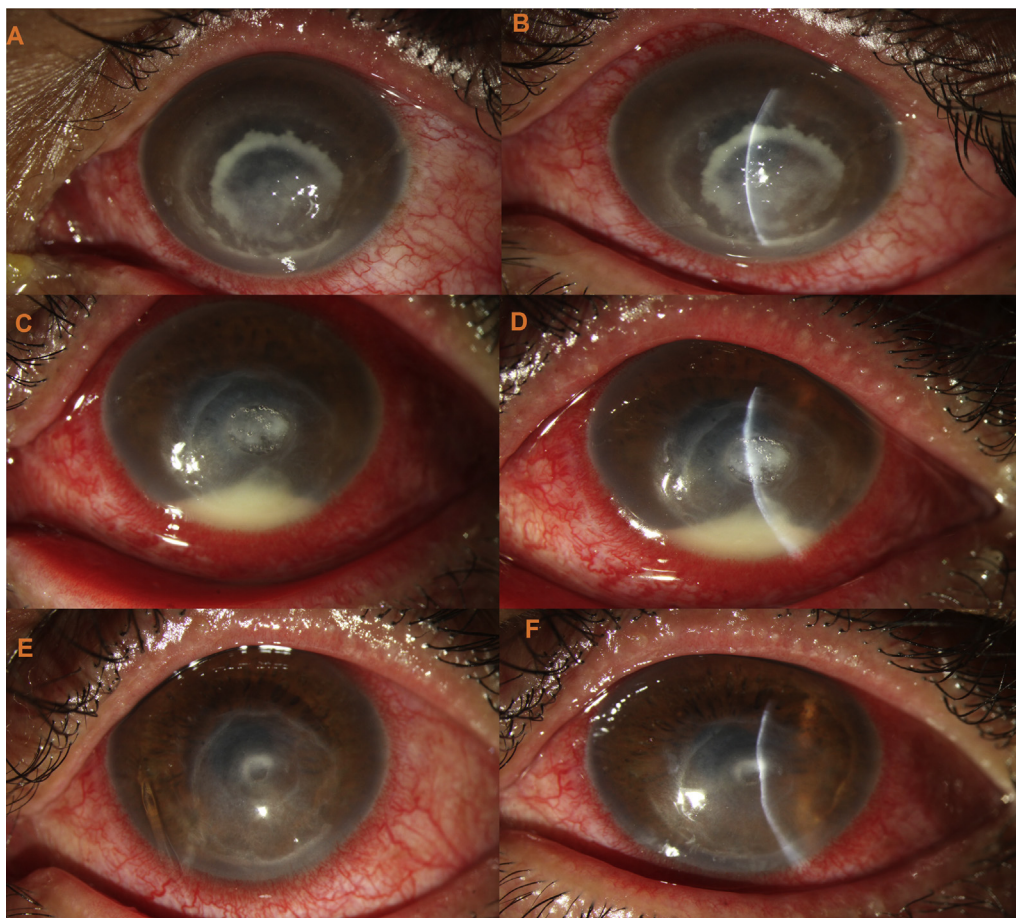


Fig. 1. Clinical picture of the case 1. A, B: clinical picture of the patient at presentation. C, D: the patient developed hypopyon 20 days after initiating medication, but the density of infiltration was reducing. E, F: the infiltration is almost cleared with a central thinning.

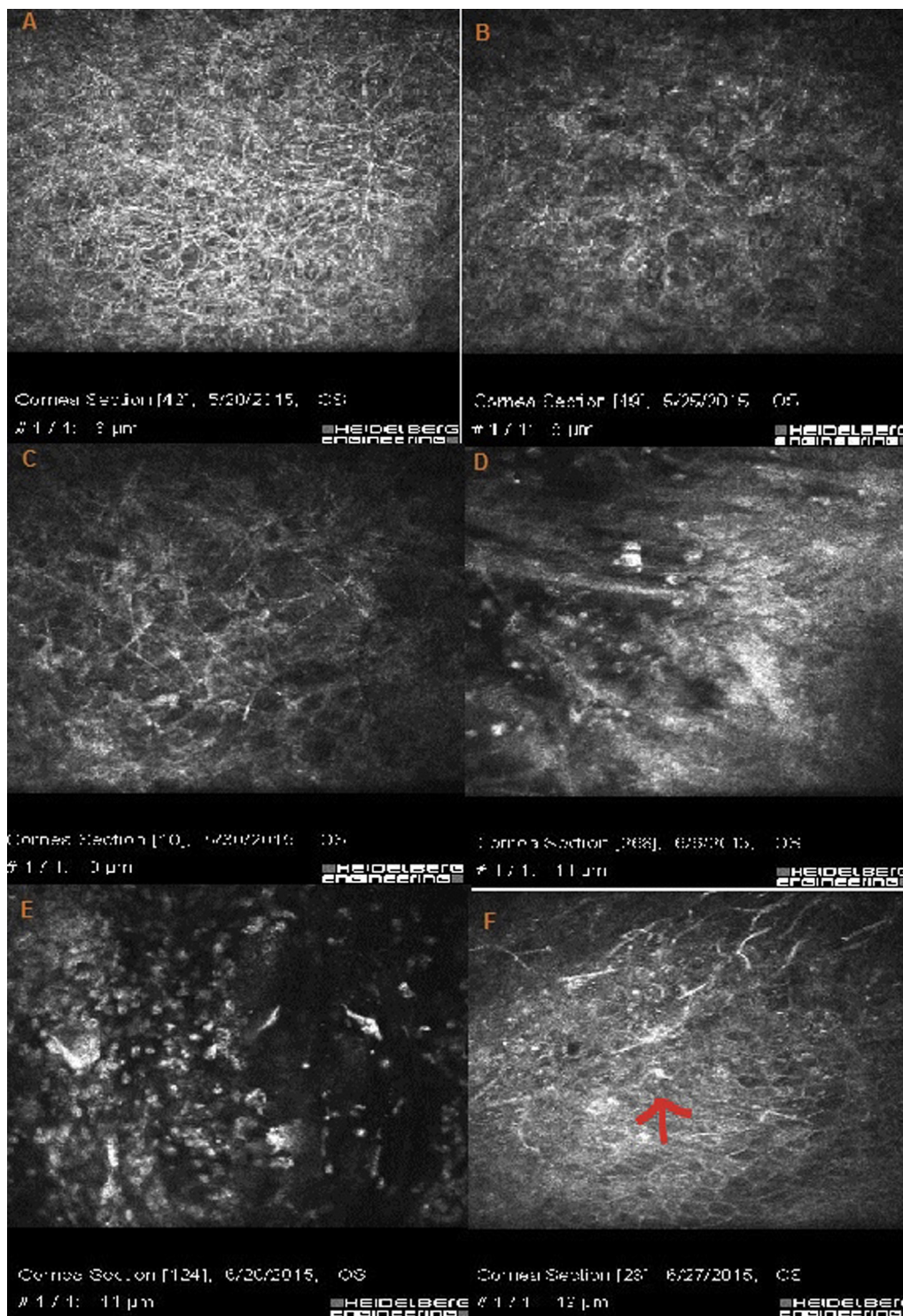


Fig. 2. In vivo confocal microscopy (IVCM) of the patient. A: diffuse, hyper-reflective, branching and interlocking structures typical of fungal hyphae. B, C: The density of hyphae decreased after 5 days. D: The cornea is infiltrated by inflammatory cells. This image is synchronous with development of hypopyon. E, F: presence of inflammatory cells in the cornea (arrow).

after starting medications, and anti-microbial agents were tapered while signs and symptoms were improving. Besides this regimen, lubricating agents were also prescribed. IVCM was done for the patient weekly. Multiple hyper-reflective, branching, and interlocking structures characteristics of fungal hyphae were detected in IVCM (including interlocking

and branching structures with septate appearance) (Fig. 4). These fungal hyphae decreased in density with treatment. Five days after culturing on sabouraud agar, blood agar, and chocolate agar, the organism was detected as *Colletotrichum coccodes*. Topical natamycin was tapered weekly until the sixth week when the patient developed a scar. Systemic anti-

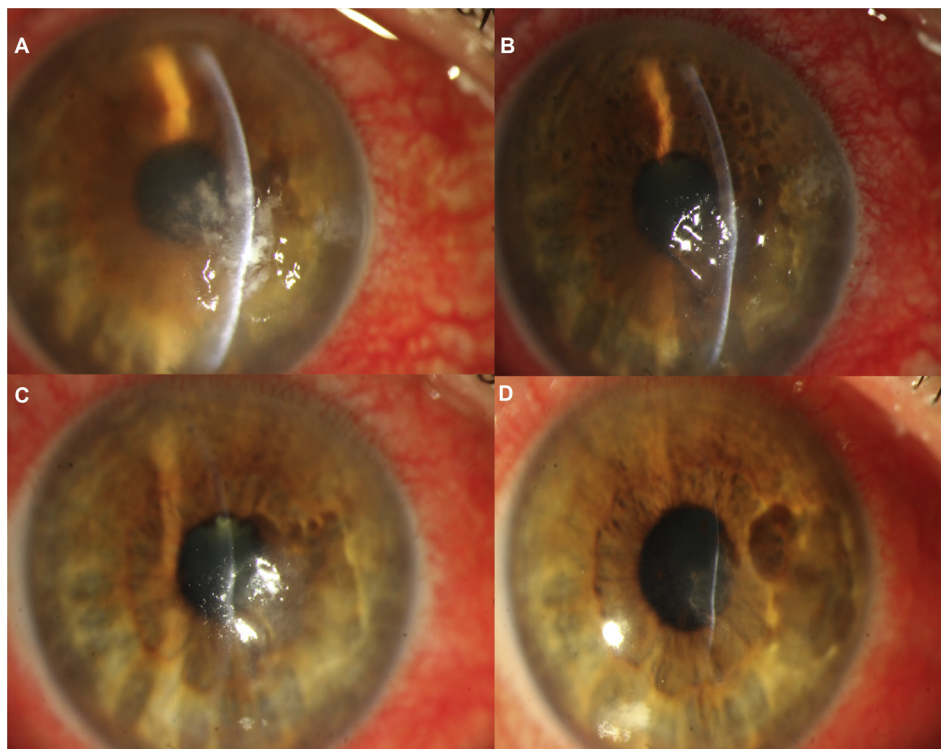


Fig. 3. Clinical picture of the case 2. A: Slit photograph of the patient at presentation. B, C: reduced infiltration after 1 week and 3 weeks, respectively. D: slit photograph 2 months after presentation. Infiltration has turned into scar tissue with central thinning.

fungal was discontinued two weeks after startup of the treatment.

Discussion

P. boydii is a recognized cause of mycetoma, a chronic fungal disease that usually affects the extremities.¹⁰ It is a ubiquitous filamentous fungi found in soil, water, and sewage.^{10,11} First described in 1955, the organism can cause fungal keratitis that is usually unresponsive to medical treatment. Wong et al presented the first case of *P. boydii* keratitis that was successfully treated with topical natamycin. Wu et al reported a rate of enucleation or evisceration about 45% in these patients. They related this failure rate to misrecognition of this pathogen and initial bacterial treatment. There are other reports of successful treatment using topical voriconazole, miconazole, nystatin, and amphotericin B.^{11–20} This organism has septate, thin-walled, branching hyphae and an angioinvasive tendency.¹⁴ There is not any report of confocal scanning of this type of fungal keratitis in the literature. However, its clinical picture is almost the same as other keratitis caused by fungal organisms with white-gray infiltration and feathery border. The diagnosis is made by studying the smear and culture of corneal scraping samples. When the organism is stained with hematoxylin and eosin, it is indistinguishable from *Aspergillus* spp. morphologically.²⁰ *P. boydii* is generally sensitive to azoles, and there are some reports of its resistance to polyenes.²⁰ In cases that suffer from keratitis caused by this

organism, fortified topical voriconazole can be prescribed. We added oral itraconazole as an adjuvant medication.

Colletotrichum spp. are anamorphic stages of fungi of the family Glomerellaceae.^{21–25} *Colletotrichum* spp. exist in hot and moderate climates.^{22–24,26} There are rare reports of keratitis caused by *Colletotrichum* spp.^{27–30} On KOH smear, septate hyaline hyphae can be seen. *Fusarium* spp. and *Colletotrichum* spp. both have curved conidia, so morphological discrimination is difficult. However, the presence of appressoria, non-septate conidia, and (in the later stages) acervuli with setae in *Colletotrichum* help in the discrimination.²³ Povidone iodine is fungicidal to aerial mycelium of *Colletotrichum dematium*, *Colletotrichum gloeosporioides*, and *Colletotrichum acutatum*, and it is fungistatic to *C. coccodes*.³¹ Amphotericin B is the first choice for this organism.³¹ It is also sensitive to clotrimazole and miconazole.³¹ There is a high minimum inhibitory concentration (MIC) by in vitro susceptibility testing for natamycin, but it has good clinical response²⁷ the same as our case.

In conclusion, these cases bold the importance of determining causative organism of fungal keratitis and their antibiotic susceptibility. There was not any specific confocal feature for the presented fungal keratitis that was different from other filamentous fungal hyphae; however, confocal scan is a good choice to follow the response to the treatment, as in the first case. Despite increasing hypopyon, medical treatment was continued because of decreasing hypha density in confocal scanning.

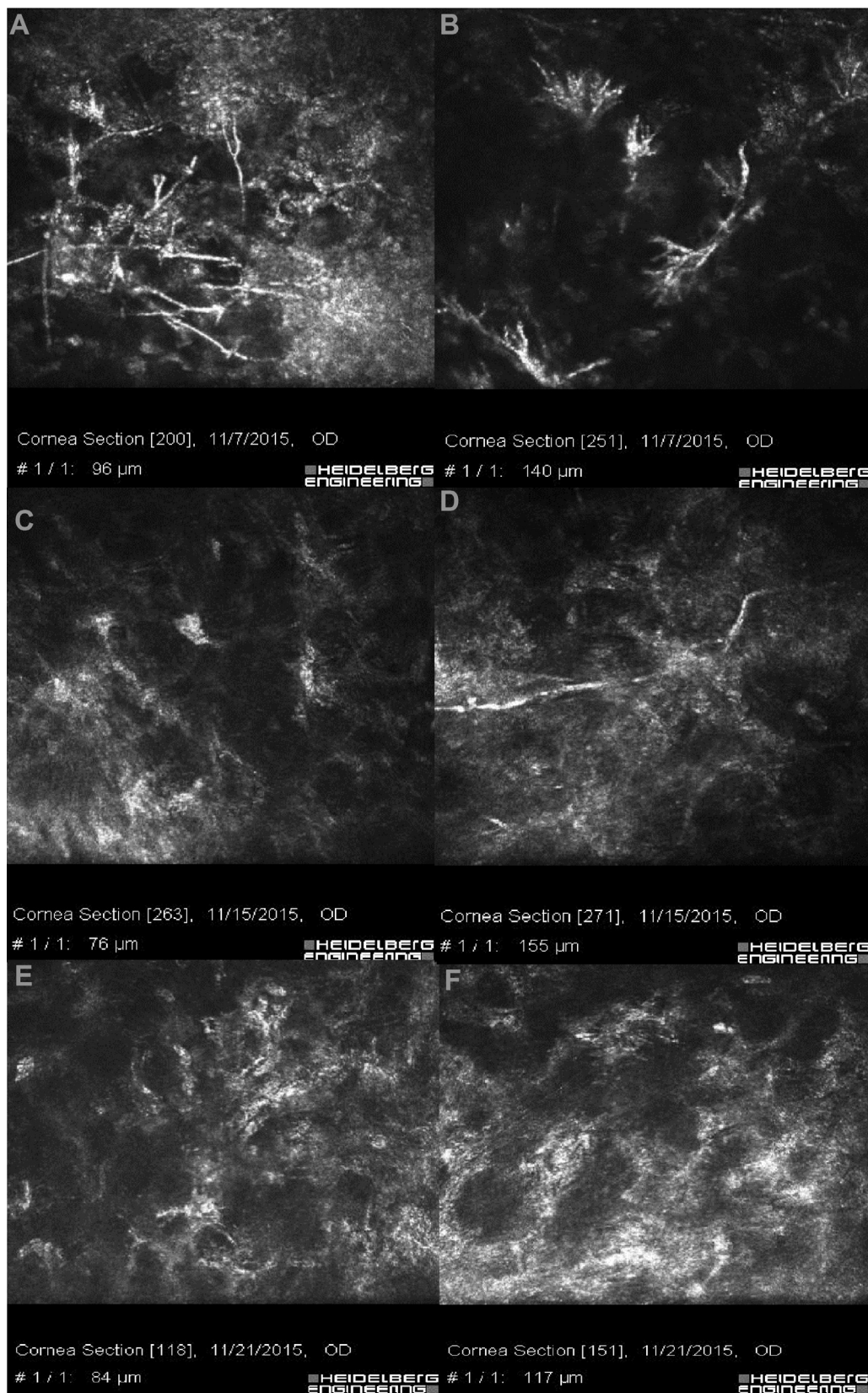


Fig. 4. In vivo confocal microscopy (IVCM) of the patient. A, B: hyper-reflective, branching, and interlocking structures typical of fungal hyphae. C, D: The reduction of fungal hyphae density can be seen in IVCM after 8 days. E, F: The IVCM is free of hyphae 2 weeks after starting the medication.

References

1. Chang HY, Chodosh J. Diagnostic and therapeutic considerations in fungal keratitis. *Int Ophthalmol Clin*. 2011;51(4):33–42.
2. Thomas PA. Fungal infections of the cornea. *Eye (London)*. 2003;17(8):852–862.
3. Srinivasan M. Fungal keratitis. *Curr Opin Ophthalmol*. 2004;15(4):321–327.
4. Nielsen E, Heegaard S, Prause JU, Ivarsen A, Mortensen KL, Hjortdal J. Fungal keratitis – improving diagnostics by confocal microscopy. *Case Rep Ophthalmol*. 2013;4(3):303–310.
5. Cheng SC, Lin YY, Kuo CN, Lai LJ. Cladosporium keratitis – a case report and literature review. *BMC Ophthalmol*. 2015;15:106.
6. Takezawa Y, Shiraishi A, Noda E, et al. Effectiveness of in vivo confocal microscopy in detecting filamentous fungi during clinical course of fungal keratitis. *Cornea*. 2010;29(12):1346–1352.
7. Das S, Samant M, Garg P, Vaddavalli PK, Vemuganti GK. Role of confocal microscopy in deep fungal keratitis. *Cornea*. 2009;28(1):11–13.
8. Kumar RL, Cruzat A, Hamrah P. Current state of in vivo confocal microscopy in management of microbial keratitis. *Semin Ophthalmol*. 2010;25(5-6):166–170.
9. Kaufman SC, Musch DC, Belin MW, et al. Confocal microscopy: a report by the American Academy of Ophthalmology. *Ophthalmology*. 2004;111(2):396–406.
10. Travis LB, Roberts GD, Wilson WR. Clinical significance of *Pseudallescheria boydii*: a review of 10 years' experience. *Myco Clin Proc*. 1985;60(8):531–537.
11. Wong AC, Mak ST, Luk S, Tse RK. Successful treatment of *Pseudallescheria boydii* keratitis with topical natamycin as monotherapy. *J Ocul Pharmacol Ther*. 2010;26(5):519–521.
12. Wu Z, Ying H, Yiu S, Irvine J, Smith R. Fungal keratitis caused by *Scedosporium apiospermum*: report of two cases and review of treatment. *Cornea*. 2002;21(5):519–523.
13. Guber I, Bergin C, Majo F. Repeated intrastromal injections of voriconazole in combination with corneal debridement for recalcitrant fungal keratitis – a case series. *Klin Monbl Augenheilkd*. 2016;233(4):369–372.
14. Bradley JC, Hirsch BA, Kimbrough 3rd RC, McCartney DL. *Pseudallescheria boydii* keratitis. *Scand J Infect Dis*. 2006;38(11-12):1101–1103.
15. Pautler EE, Roberts RW, Beamer PR. Mycotic infection of the eye. Monosporium apiospermum associated with corneal ulcer. *Arch Ophthalmol*. 1955;53(3):385–389.
16. Ozkurt Y, Oral Y, Kulekci Z, Benzonana N, Ustaoglu R, Dogan OK. *Pseudallescheria boydii* keratitis. *J Pediatr Ophthalmol Strabismus*. 2006;43(2):114–115.
17. Mancini N, Ossi CM, Perotti M, et al. Direct sequencing of *Scedosporium apiospermum* DNA in the diagnosis of a case of keratitis. *J Med Microbiol*. 2005;54(Pt 9):897–900.
18. Sridhar MS, Garg P, Bansal AK, Sharma S. Fungal keratitis after laser in situ keratomileusis. *J Cataract Refract Surg*. 2000;26(4):613–615.
19. D'Hondt K, Parys-Van Ginderdeuren R, Foets B. Fungal keratitis caused by *Pseudallescheria boydii* (*Scedosporium apiospermum*). *Bull Soc Belge Ophthalmol*. 2000;277:53–56.
20. Saracli MA, Erdem U, Gonlum A, Yildiran ST. *Scedosporium apiospermum* keratitis treated with itraconazole. *Med Mycol*. 2003;41(2):111–114.
21. Joseph J, Fernandez M, Sharma S. *Colletotrichum dematium* keratitis. *J Postgrad Med*. 2004;50(4):309–310.
22. Mendiratta DK, Thamke D, Shukla AK, Narang P. Keratitis due to *Colletotrichum dematium* – a case report. *Indian J Med Microbiol*. 2005;23(1):56–58.
23. Kirk PM, Cannon PF, Minter DW, Stalpers JA. *Ainsworth and Bisby's Dictionary of the Fungi*. 10th ed. CABI Europe–UK, Wallingford: CAB International; 2008:771.
24. Machowicz-Stefaniak Z. Occurrence and characterization of *Colletotrichum dematium* (Fr.) Grove. *Pol J Microbiol*. 2010;59(3):191–200.
25. Kotwal A, Biswas D, Kakati B, Bahadur H, Gupta N. Non traumatic keratitis due to *Colletotrichum coccodes*: a case report. *J Clin Diagn Res*. 2015;9(2). DD01-2.
26. Shivaprakash MR, Appannanavar SB, Dhaliwal M, et al. *Colletotrichum truncatum*: an unusual pathogen causing mycotic keratitis and endophthalmitis. *J Clin Microbiol*. 2011;49(8):2894–2898.
27. Liesegang TJ, Forster RK. Spectrum of microbial keratitis in South Florida. *Am J Ophthalmol*. 1980;90(1):38–47.
28. Natarajan SV, Rekha NS, Sharda RD, Mahalingam N. *Colletotrichum* keratitis: a rare but definite clinical entity. *J Clin Diagn Res*. 2013;7(7):1430–1433.
29. Machowicz-Matejko E, Zalewska ED. Pharmacological substances in vitro in limiting growth and development of fungi *colletotrichum* genera. *J Ocul Pharma Ther*. 2015;31(5):303–309.
30. De Hoog GS, Guarro J, Gene J, Figueras MJ. *Atlas of Clinical Fungi: Central Bureau Voor Schimmelcultures*. 2nd ed. The Netherlands: Utrecht; 1995.
31. Shukla P, Kumar M, Keshava G. Mycotic keratitis: an overview of diagnosis and therapy. *Mycoses*. 2008;51(3):183–199.