



Brief report

# Intravitreal bevacizumab as rescue therapy following treatment failure with laser photocoagulation in retinopathy of prematurity

Caner Kara <sup>a,\*</sup>, Emre Hekimoğlu <sup>b</sup>, İkbal Seza Petriçli <sup>a</sup>, Handan Akıl <sup>c</sup>

<sup>a</sup> Etlik Zübeyde Hanım Women's Health Education and Research Hospital, Department of Ophthalmology, Ankara, Turkey

<sup>b</sup> Avrupa Eye Hospital, Istanbul, Turkey

<sup>c</sup> Nevşehir State Hospital, Department of Ophthalmology, Nevşehir, Turkey

Received 20 April 2017; revised 30 July 2017; accepted 7 August 2017

Available online 24 August 2017

## Abstract

**Purpose:** To evaluate the efficacy of intravitreal bevacizumab (IVB) in case of treatment failure with laser photocoagulation in retinopathy of prematurity (ROP).

**Methods:** A retrospective review of infants treated with IVB injection due to treatment failure with laser photocoagulation was performed. The anatomical results and complications were evaluated after treatment.

**Results:** 9 eyes of 6 premature infants with a mean gestational age of  $26.8 \pm 3.0$  weeks (range, 23–32 w) and mean birth weight of  $958 \pm 319$  g (range, 600–1400 g) were identified. Six of the eyes had zone 1 disease, and all of these eyes were classified as aggressive posterior ROP (APROP). Three of the eyes had zone 2 disease, and one of these eyes was classified as APROP, and the other two eyes were classified as high-risk pre-threshold disease. All of the eyes showed regression of the disease except one patient, both eyes of whom progressed to stage 4A. None of the patients developed ocular and systemic complications at the end of the six-month follow-up period.

**Conclusion:** IVB could be an option in patients with ROP in whom laser photocoagulation failed.

Copyright © 2018, Iranian Society of Ophthalmology. Production and hosting by Elsevier B.V. This is an open access article under the CC BY-NC-ND license (<http://creativecommons.org/licenses/by-nc-nd/4.0/>).

**Keywords:** Bevacizumab; Retinopathy of prematurity; Photocoagulation; Rescue therapy; Treatment failure

## Introduction

Retinopathy of prematurity (ROP) is a neovascular disorder of the developing retina, which is the main cause of visual impairment and blindness in infants with low birth weight and

preterm gestational age.<sup>1</sup> The development of retinal vessels is disrupted by preterm birth. Fibrovascular proliferation and abnormal vessel formation may cause vitreoretinal traction and retinal detachment which may lead to irreversible blindness.

ROP has recently become a very serious problem in developing countries due to the improvement in the surviving rates of younger preterm infants.<sup>2</sup> As the survival rate of very low birth weight infants in intensive care units rises, the number of infants with ROP has risen.<sup>3</sup>

Laser photocoagulation is the standard of treatment choice in an attempt to slow down or reverse the growth of abnormal blood vessels and scar tissue formation despite problems such as visual field loss and development of myopia.<sup>4,5</sup> Recent research studies have shown that although laser treatment

**Funding:** This research received no specific grant from any funding agency in the public, commercial, or not-for-profit sectors.

**Conflict of interest:** The authors report no conflicts of interest and have no proprietary interest in any of the materials mentioned in this article.

\* Corresponding author. Etlik Zübeyde Hanım Women's Health Education and Research Hospital, Department of Ophthalmology, Yeni Etlik Caddesi, No: 55, 06010, Etlik, Keçiören, Ankara, Turkey.

E-mail address: [canerkara@hotmail.com](mailto:canerkara@hotmail.com) (C. Kara).

Peer review under responsibility of the Iranian Society of Ophthalmology.

produces excellent results, 10% of the patients still may have unfavorable results.<sup>6</sup>

In current practice, there has been an increase in the use of vascular endothelial growth factor inhibitors (anti-VEGF) which appears to cause abnormal vessels to regress thereby preventing bleeding and retinal detachment. Intravitreal bevacizumab (IVB) monotherapy compared with conventional laser therapy showed a significant benefit for zone 1 stage 3 plus ROP.<sup>7</sup> Additionally, many clinicians prefer to use IVB injection in combination to laser photocoagulation or preoperatively to improve surgical outcome.<sup>8,9</sup>

Anti-VEGF treatment may be reserved for premature infants who cannot tolerate the laser procedure because of their other life-threatening conditions, inadequate visualization of the retina preventing appropriate laser treatment, or in extremely premature infants with an aggressive form of ROP [aggressive posterior ROP (APROP)] that has a high risk of retinal detachment.

In this study, we evaluated IVB injection as a treatment option following the failure of laser photocoagulation.

## Methods

A retrospective review of infants treated with IVB injection due to treatment failure of laser photocoagulation between 2011 and 2014 was performed. The study was approved by Ethics Committee of the Institution.

Laser photocoagulation was performed in cases with APROP and high-risk pre-threshold (type 1) disease. Type 1 disease is defined as: zone 1 any stage with plus disease, zone 1 stage 3 without plus disease and zone 2 stage 2 and stage 3 with plus disease according to Early Treatment Retinopathy of Prematurity Study.<sup>10</sup> APROP was defined as increased dilation and tortuosity of the posterior pole vessels in all quadrants with flat neovascularization between vascular and avascular retina in Zone I or posterior Zone II.<sup>11</sup>

Laser photocoagulation was performed under sedoanalgesia with remifentanyl.<sup>12</sup> The laser technique used was indirect transpupillary photocoagulation (OcuLight® SL, Iridex, CA, USA). All patients underwent diode laser photocoagulation of the peripheral avascular retina area with confluent laser pattern. After laser treatment, patients were examined with indirect video ophthalmoscope on the next day and weekly. All the laser procedures were performed by a single experienced physician.

Despite fully laser photocoagulation without skip areas, persistence or progression of plus disease and retinal neovascularization, the persistence of rubeosis iridis or new vessel formation on the iris, and an increase in retinal traction were considered treatment failure. In these cases, IVB injection was taken into consideration, and the parents were informed about the procedure. Informed consent was obtained.

All IVB injections were performed in the NICU. The pupil was dilated with 2.5% phenylephrine and 0.5% tropicamide before intravitreal injection. Following topical anesthesia using 0.5% proparacaine hydrochloride, the children were held by a nurse. The eyelids and eyelashes were cleaned with 10%

povidone-iodine and draped. A lid speculum was placed, and conjunctiva was prepared with 5% povidone-iodine. A total of 0.625 mg (0.025 ml) bevacizumab was injected 1.5 mm posterior to the limbus in the temporal inferior quadrant in an oblique way via a 30G needle. Both eyes were not treated in the same sessions. When necessary, the fellow eyes of the patients were treated on the following day. After intravitreal injection, retinal artery perfusion was checked. Topical netilmicin sulfate was administered six times a day for 1 week postoperatively.

## Results

The study consisted of 9 eyes of 6 premature infants, 5 boys and 1 girl whose main clinical characteristics are detailed in Table 1. Gestational age at birth of the infants ranged from 25 to 29 weeks (mean  $26.3 \pm 2.1$  weeks), and the birth weights varied from 600 g to 1200 g (mean  $908 \pm 253$  g). Laser photocoagulation and IVB were performed at the mean postmenstrual age of  $35.2 \pm 1.4$  weeks (range, 33–37) and  $36.4 \pm 1.8$  weeks (range, 34–38), respectively.

One patient (Patient 3) was followed in our neonatal intensive care unit, and the others were referred from other clinics for laser photocoagulation.

Six of the eyes had zone 1 ROP, and all of these eyes were classified as APROP. Three of the eyes had zone 2 ROP, and one of these eyes with zone 2 posterior was classified as APROP, and the other two eyes were classified as high-risk pre-threshold disease. All of the eyes showed regression of the disease except one patient, both eyes of whom progressed to stage 4A and underwent lens-sparing vitrectomy bilaterally. At the last follow-up performed two years after surgery, the retina was attached in both eyes and the lenses were clear. Mean regression time was 5 days (3–7 days) after treatment, and mean follow-up time was  $22.8 \pm 20.9$  (6–50 months). Images of one of the patients in whom ROP regressed after treatment and the only patient who developed retinal detachment following IVB injection are shown in Figs. 1 and 2.

There were no ocular complications such as cataract, endophthalmitis or ocular inflammation, and any other systemic (cardiovascular, neurological and respiratory) adverse effects were not identified at the end of the six month follow-up period.

## Discussion

In this study, our small case series showed that IVB treatment seems to be effective in case of treatment failure with laser photocoagulation. In our case series, only one patient did not respond to therapy and bilaterally progressed to stage 4A, whereas the other eyes we observed significant improvement.

Currently, standard therapy in the treatment of ROP is to ablate the peripheral avascular area by making laser photocoagulation scars without skip areas.<sup>13</sup> Many studies have found the success rate of laser treatment over 90%.<sup>14,15</sup> However, unfavorable structural results have been reported,

Table 1  
Clinical characteristics of the patients.

Patient	GA (weeks)	BW (g)	Gender	Stage	Zone	Laser	IVB	Indication for IVB	Time to resolution	Anatomical outcome
1	25	720	Male	APROP	1	W: 36 OD: 1810 spots OS: 1700 spots	W: 38 (Bilateral)	Persistence of plus disease	4 days	Regression
2	27	1100	Male	APROP	2-P	W: 34 OD: 1490 spots OS: 1580 spots	W: 36 (OS)	Persistence of plus disease	5 days	Regression
3	26	730	Male	3	2	W: 36 OD: 1085 spots OS: 988 spots	W: 38 (OD)	Persistence of retinal neovascularization and new vessel on the iris	7 days	Regression
4	28	1200	Male	APROP	1	W: 33 OD: 1698 spots OS: 1762 spots	W: 36 (Bilateral)	Progression of plus disease and retinal neovascularization	4 days	Regression
5	29	1100	Male	APROP	1	W: 35 OD: 1935 spots OS: 2047 spots	W: 37 (Bilateral)	Progression of plus disease and new vessel on the iris	–	Progression to stage 4A
6	23	600	Female	3	2	W: 35 OD: 1430 spots OS: 1350 spots	W: 37 (OD)	Persistence of plus disease and new vessel on the iris	3 days	Regression

GA: Gestational age, BW: Birth weight, IVB: Intravitreal bevacizumab, W: Postmenstrual week, APROP: Aggressive posterior retinopathy of prematurity.

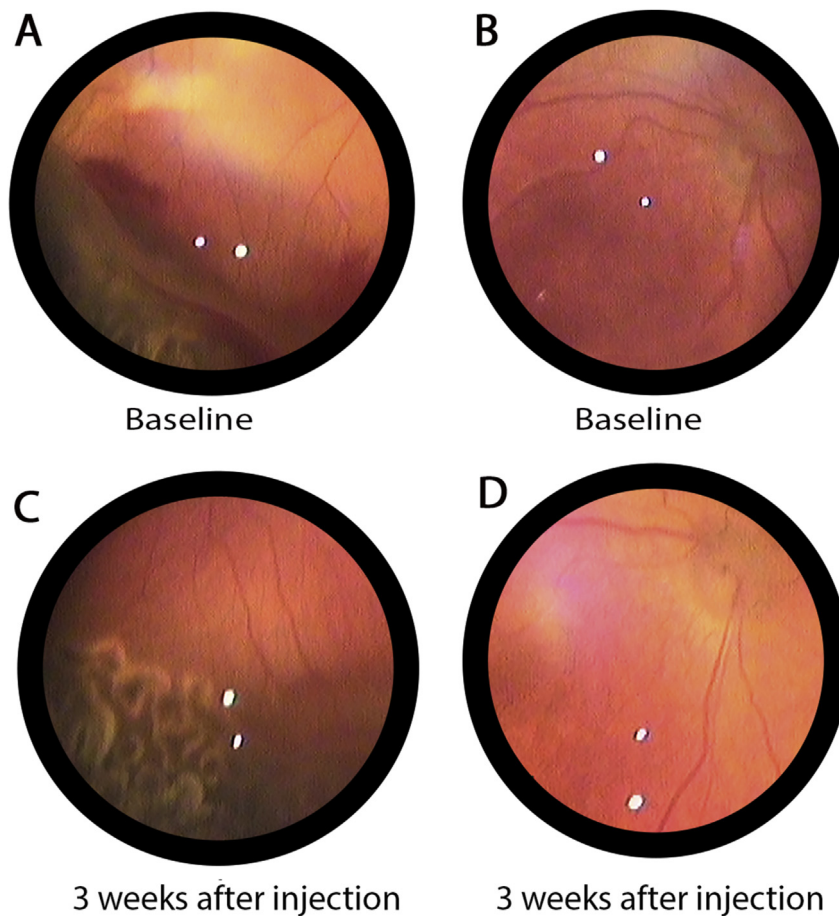


Fig. 1. Fundus images of the right eye of case 3. The patient was treated with laser photocoagulation for zone 2, stage 3 disease at 36 weeks. Due to insufficient regression of retinal neovascularization, intravitreal bevacizumab (IVB) injection was performed at 38 weeks. Baseline fundus images at 38 weeks before IVB were shown on (A) and (B) and regression of the disease 3 weeks later following IVB injection were shown on (C) and (D).

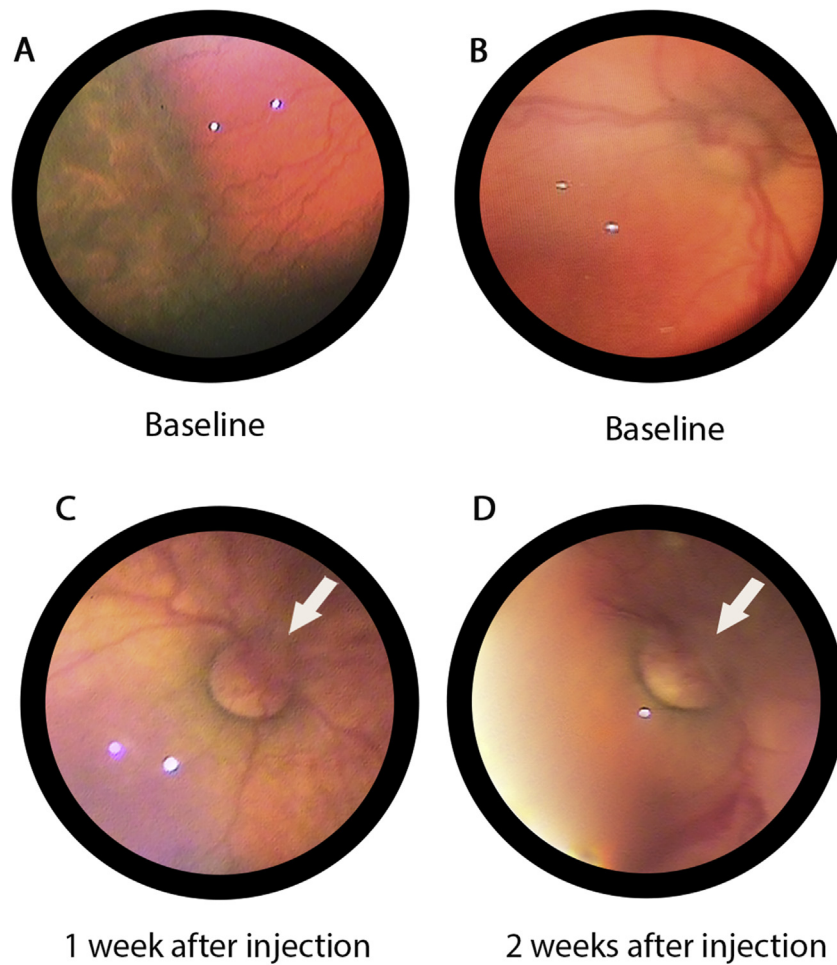


Fig. 2. Fundus images of the right eye of case 5. The patient was treated with laser photocoagulation for aggressive posterior retinopathy of prematurity (APROP) at 35 weeks. Due to persistence of plus disease, intravitreal bevacizumab (IVB) injection was performed at 37 weeks. Baseline fundus photographs at 37 weeks before IVB were shown on (A) and (B). Development of retinal detachment and its progression after IVB injection were shown on (C) and (D). Retinal detachments on nasal side optic disk were shown with white arrows.

and progression of the disease in zone 1 cases is common despite extensive laser treatment.<sup>16–18</sup> Laser photocoagulation causes regression of retinal neovascularization by destructing avascular retina, but it may cause an increase in VEGF levels temporarily after photocoagulation, and this situation may cause a progression in ROP.<sup>19,20</sup> For this reason, regression of neovascularization occurs within 2–3 weeks, and progression of ROP can be seen, especially in posterior pole ROP (zone 1 or posterior zone 2 ROP) despite complete laser treatment.<sup>21</sup>

IVB does not act over a long period. It starts inducing regression of the neovascularization as soon as it blocks all VEGF in the vitreous.<sup>20</sup> For that reason, the anti-VEGF therapy has an additional benefit in over laser therapy. Furthermore, previous studies have evaluated IVB as an adjuvant or as a possible monotherapy for especially posterior ROP disease.<sup>22,23</sup>

The results of the BEAT-ROP study demonstrated that IVB monotherapy, as compared with conventional laser therapy in infants with stage 3 ROP, showed a significant benefit for zone 1 diseases.<sup>7</sup> However, the rate of recurrence in zone 2 posterior disease did not show the difference between laser therapy group and the bevacizumab group. In addition to IVB

monotherapy, several studies using combined IVB injection and laser ablation reported favorable outcomes.<sup>9,22,24</sup>

In our case group, the choice of laser photocoagulation in cases with zone 1 or zone 2 posterior disease may have led to the need of IVB as a rescue therapy (7 eyes with zone 1 and zone 2 posterior vs. 2 eyes with zone 2). In these cases, laser photocoagulation was preferred because bevacizumab was not used in our clinical practice at that time. At present, we prefer IVB monotherapy in these types of cases with additional laser photocoagulation if the disease recurs or peripheral avascular area remains. Additionally, laser photocoagulation may be required for APROP cases as a first treatment if there is a contraindication for the use of IVB such as conjunctivitis or other active external eye infections.

As another point, surgeons should follow the cases for a long period of time after IVB because the recurrence is common, and in these cases, previous laser therapy had the benefit of possible less recurrence. Also, surgeons should follow the cases closely, as the eyes may progress to higher stages despite aggressive laser and IVB and need vitrectomy.

Although IVB may be a good treatment choice for posterior ROP and can be used in different approaches, timing is crucial

for the success. In early usage, it may lead to the delay of normal vascularization in contrast to late usage that may cause tractional retinal detachment due to preformed fibrous vitreoretinal membrane termed as Crunch phenomenon. Similar cases with severe proliferative diabetic retinopathy showed the phenomenon after IVB injection. One of our stage 3 patients might have faced the same problem in our follow-up, but further studies are needed to show which group of ROP patients may develop the phenomenon.

Despite promising results with IVB as monotherapy or combination with laser, systemic effects of IVB injection are uncertain. So it should be noted that infants with ROP are still in the process of organogenesis, and VEGF plays a role in the development of most organs. Furthermore, contrary to monotherapy with IVB, rescue therapy has a higher risk of systemic side effects because previously performed laser treatment may cause the escape of more bevacizumab into the systemic circulation from ablated retina.<sup>23</sup> Although we did not see systemic side effects, further prospective larger scaled studies with longer follow-up periods might be helpful.

Due to a small number of cases, it is difficult to make a generalized statements regarding the use of bevacizumab as a rescue therapy in cases unresponsive to laser photocoagulation in this report. Nonetheless, we observed a significant improvement in the progression of disease except for a patient.

As a result, in case of failure of laser photocoagulation in ROP, IVB can be an option to prevent progression of the disease. However, studies with larger sample sizes need to be performed to clarify this issue.

## References

- Hutcheson KA. Retinopathy of prematurity. *Curr Opin Ophthalmol*. 2003; 14(5):286–290.
- Gilbert C. Retinopathy of prematurity: a global perspective of the epidemics, population of babies at risk and implications for control. *Early Hum Dev*. Feb 2008;84(2):77–82.
- Gibson DL, Sheps SB, Uh SH, Schechter MT, McCormick AQ. Retinopathy of prematurity-induced blindness: birth weight-specific survival and the new epidemic. *Pediatrics*. 1990;86(3):405–412.
- Prepiakova Z, Tomcikova D, Kostolna B, Gerinec A. Confluent diode laser coagulation: the gold standard of therapy for retinopathy of prematurity. *J Pediatr Ophthalmol Strabismus*. 2015;52(1):43–51.
- McLoone E, O'Keefe M, McLoone S, Lanigan B. Effect of diode laser retinal ablative therapy for threshold retinopathy of prematurity on the visual field: results of goldmann perimetry at a mean age of 11 years. *J Pediatr Ophthalmol Strabismus*. 2007;44(3):170–173.
- Repka MX, Tung B, Good WV, Capone A, Shapiro MJ. Outcome of eyes developing retinal detachment during the early treatment for retinopathy of prematurity study. *Arch Ophthalmol*. 2011;129(9):1175–1179.
- Mintz-Hittner HA, Kennedy KA, Chuang AZ. Efficacy of intravitreal bevacizumab for stage 3+ retinopathy of prematurity. *N Engl J Med*. 2011;364(7):603–615.
- Xu Y, Zhang Q, Kang X, et al. Early vitreoretinal surgery on vascularly active stage 4 retinopathy of prematurity through the preoperative intravitreal bevacizumab injection. *Acta Ophthalmol*. 2013;91(4):e304–310.
- Nazari H, Modarres M, Parvaresh MM, Ghasemi Falavarjani K. Intravitreal bevacizumab in combination with laser therapy for the treatment of severe retinopathy of prematurity (ROP) associated with vitreous or retinal hemorrhage. *Graefes Arch Clin Exp Ophthalmol*. 2010;248(12):1713–1718.
- Early Treatment For Retinopathy Of Prematurity Cooperative G. Revised indications for the treatment of retinopathy of prematurity: results of the early treatment for retinopathy of prematurity randomized trial. *Arch Ophthalmol*. 2003;121(12):1684–1694.
- International Committee for the Classification of Retinopathy of P. The international classification of retinopathy of prematurity revisited. *Arch Ophthalmol*. 2005;123(7):991–999.
- Demirel N, Bas AY, Kavurt S, et al. Remifentanyl analgesia during laser treatment for retinopathy of prematurity: a practical approach in neonatal intensive care unit. *Am J Perinatol*. 2014;31(11):983–986.
- Nicoara SD, Cristian C, Irimescu I, Stefanut AC, Zaharie G. Diode laser photocoagulation for retinopathy of prematurity: outcomes after 7 years of treatment. *J Pediatr Ophthalmol Strabismus*. 2014;51(1):39–45.
- Austeng D, Kallen KBM, Ewald UW, Wallin A, Holmstrom GE. Treatment for retinopathy of prematurity in infants born before 27 weeks of gestation in Sweden. *Br J Ophthalmol*. 2010;94(9):1136–1139.
- Gunn DJ, Cartwright DW, Yuen SA, Gole GA. Treatment of retinopathy of prematurity in extremely premature infants over an 18-year period. *Clin Exp Ophthalmol*. 2013;41(2):159–166.
- Sanghi G, Dogra MR, Katoch D, Gupta A. Aggressive posterior retinopathy of prematurity: risk factors for retinal detachment despite confluent laser photocoagulation. *Am J Ophthalmol*. 2013;155(1):159–164 e152.
- Jalali S, Kesarwani S, Hussain A. Outcomes of a protocol-based management for zone 1 retinopathy of prematurity: the Indian Twin Cities ROP Screening Program report number 2. *Am J Ophthalmol*. 2011;151(4):719–724 e712.
- Gunn DJ, Cartwright DW, Gole GA. Prevalence and outcomes of laser treatment of aggressive posterior retinopathy of prematurity. *Clin Exp Ophthalmol*. 2014;42(5):459–465.
- Witmer AN, Vrensen GFJM, Van Noorden CJF, Schlingemann RO. Vascular endothelial growth factors and angiogenesis in eye disease. *Prog Retin Eye Res*. 2003;22(1):1–29.
- Mintz-Hittner HA, Kuffel Jr RR. Intravitreal injection of bevacizumab (avastin) for treatment of stage 3 retinopathy of prematurity in zone I or posterior zone II. *Retina*. 2008;28(6):831–838.
- Naug HL, Browning J, Gole GA, Gobe G. Vitreal macrophages express vascular endothelial growth factor in oxygen-induced retinopathy. *Clin Exp Ophthalmol*. 2000;28(1):48–52.
- Law JC, Recchia FM, Morrison DG, Donahue SP, Estes RL. Intravitreal bevacizumab as adjunctive treatment for retinopathy of prematurity. *J AAPOS – Off Publ Am Assoc Pediatr Ophthalmol Strabismus/Am Assoc Pediatr Ophthalmol Strabismus*. 2010;14(1):6–10.
- Chung EJ, Kim JH, Ahn HS, Koh HJ. Combination of laser photocoagulation and intravitreal bevacizumab (Avastin) for aggressive zone I retinopathy of prematurity. *Graefes Arch Clin Exp Ophthalmol*. 2007; 245(11):1727–1730.
- Yoon JM, Shin DH, Kim SJ, et al. Outcomes after laser versus combined laser and bevacizumab treatment for type 1 retinopathy of prematurity in zone I. *Retina*. 2017;37(1):88–96.