

Original Article

The Anal Position Index: A Simple Method to Define the Normal Position of the Anus in Neonate

H. A. Davari MD*, M. Nazem MD**

ABSTRACT

Background: The purpose of this study was to determine the normal position of anus using anal position index (API) and the modified measurement method and also to emphasize the importance of ectopic anus.

Methods: This cross-sectional study was performed on 400 neonates, equally boys and girls, who were all full term and delivered without any malformations. Anal position index, which is the ratio of anus-fourschette distance in girls and anus-scrotum distance in boys to the distance between coccyx and fourschette/scrotum, was calculated in all cases. To make correct measurements, transparent adhesive tape was used longitudinally on midperineum in a way that it covered the anus. Then fourschette/scrotum, anus center, and the lower margin of coccyx were marked on it. Distances marked on each tape were then measured with the standard ruler.

Results: Mean \pm SD of API in girls was 0.45 ± 0.005 (95%CI: 0.44-0.46) and in boys was 0.54 ± 0.005 (95% CI: 0.53-0.55). Mean \pm 2SD was considered as the normal range for an anus position. Six female and five male neonates who had abnormal APIs were put through more investigations.

Conclusion: Our findings suggest a simple method for determination of normal position of anus in children; especially those who referred for chronic constipation. API can never be considered as the sole indication for the surgical intervention.

Keywords: ectopic anus, anal position, constipation.

One of the most common disorders of anorectal function in infancy and childhood is constipation¹. Although, the most common cause of constipation is functional, congenital anatomic malformations in anorectal area may be responsible in some of these cases¹. Similar to many other abnormalities, congenital anorectal malformations occur in a wide spectrum of severity. Slight anterior displacement of the anus is the least severe form of anorectal malformations (Figure 1.A, B). In the neonates, these abnormalities are easily diagnosed at birth with simple inspection; yet ectopic anterior anus is very difficult to diagnose without using diagnostic measurement tools^{2,3}. Ectopic anterior anus has been always reported as unrecognized cause of constipation during infancy and childhood⁴. Nowadays, despite of controversies, many

researchers believe that anterior anus cause up to one third of childhood chronic constipations and its diagnosis remains uncertain. Leape and Ramenofsky in 1978 stated that the usual anal position is in midway between the vaginal fourchette and coccyx⁵. In 1984, Reisner et al presented a simple method, the anal position index (API), to define the normal position of the anus in neonates⁶. The aim of this study is to present a modified technique to help physicians guess the abnormal position of anus without the need for complicated diagnostic measurement methods.

Materials and Methods

This was a cross sectional study conducted from January 2002 to Jun 2003 on neonates born at Isfahan's university hospitals. A total number of 400

* Associate Professor, Department of Pediatric Surgery, Isfahan University of Medical Sciences, Isfahan, Iran.

** Assistant Professor, Department of Pediatric Surgery, Isfahan University of Medical Sciences, Isfahan, Iran.

Correspondence to: Heidar Ali Davari MD, Department of pediatric surgery, AL-Zahra Hospital, Isfahan Medical University, Isfahan, Iran.

Table1. Comparing demographic data between males and females.

Variable	Sex	Mean± SD	p-value
1 Body mass index	Male	13.3±1.5	0.53
	Female	13.2±0.09	
2 Head circumference (cm)	Male	34.8±1.3	0.01*
	Female	34.5±1.08	
3 Gestational age (w)	Male	38.1±1.32	0.09
	Female	38.4±1.14	
4 Weight(g)	Male	3241±342	0.08
	Female	3184±333	

* = significant

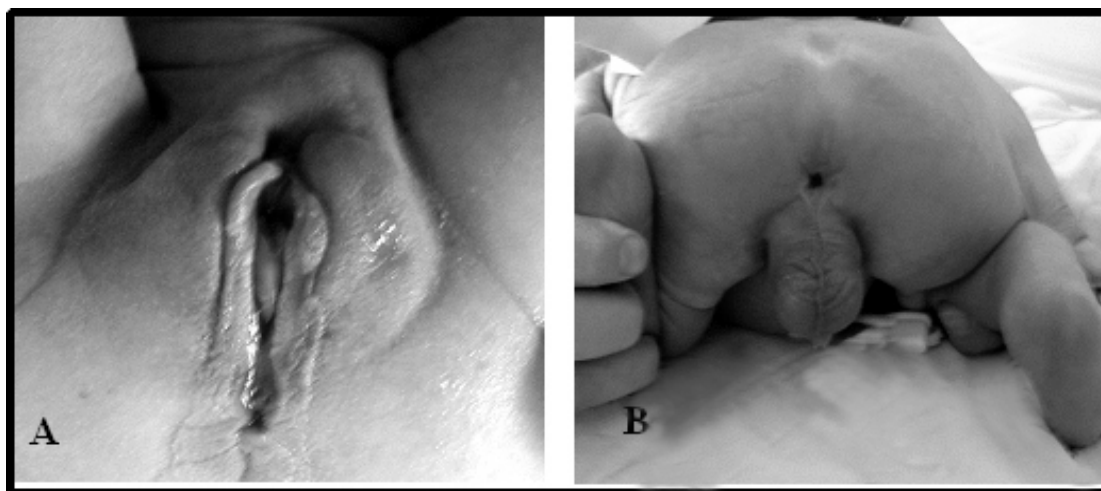


Figure 1. Anterior anus in female (A), and male (B).

cases (200boys, 200girls) were randomly selected. All neonates included were 1-3 days old, without any malformations especially in the perineum. Boys and girls were matched for variables such asz body mass index, head circumference, gestational age, and weight (Table 1). Two persons performed all

measurements and each measurement was double checked every time. To determine the neonates' API, they were held in jenopectoral position and transparent scotch tapes were used on the longitudinal axis of midperineum.

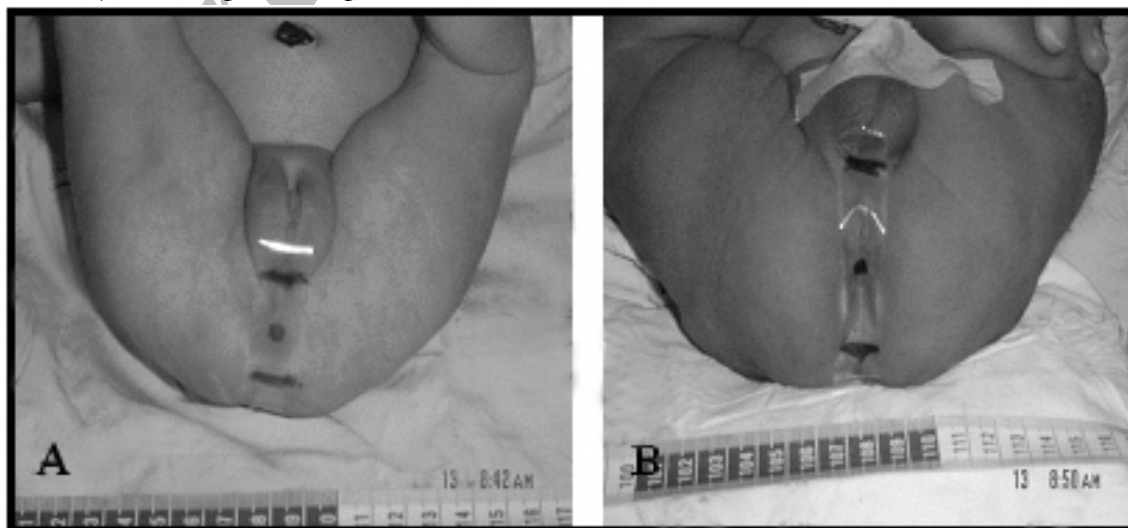


Figure2. Measurement of API in female (A), and male (B).

Results

In Table 1, sampling demographic data is shown. In this study mean \pm SD of API in girls was 0.45 ± 0.005 (95%CI: 0.44-0.46) and in boys was 0.54 ± 0.005 (95%CI: 0.53-0.55) (Table 2) (Figure 3). Mean \pm 2SD was considered as the normal range of anus position in both girls and boys, and API less than 0.44 in girls and 0.53 in boys defined as ectopic anus; Therefore anus was positioned normally in the 97.3% of the neonates. The anus position in 6 girls and 5 boys were below of normal range, which

formed 3% of girls and 2.5% of the boys who required further diagnostic investigations. Based on t-student test, the mean value of API was significantly different in boys and girls in (Boys was more than girls) ($p < 0.001$). A significant correlation was seen between API and weight only in boys ($r = 0.14$), based on stepwise logistic regression methods. Boys weight predicts API with $B = 3.19 \times 10^{-5}$ with $SE = 0.0001$.

Table2. Measurements of anus normal position in male and female neonates.

	Sex group	Mean \pm SD	CI95%	minimum	maximum
Sacroanus	Male	29.4 \pm 6	28.5-30.2	15	42
	Female	18.4 \pm 3.2	17.9-18.8	12	31
	Total	23.9 \pm 7.9	23.1-24.6	12	42
Sacrococy	Male	54.27 \pm 7.6	53.2-55.3	36	74
	Female	40.9 \pm 5.9	40.1-41.8	31	61
	Total	47.6 \pm 9.5	46.6- 48.5	31	74
API	Male	0.54 \pm 0.07	0.53-0.55	0.33	0.87
	Female	0.45 \pm 0.08	0.44-0.46	0.24	0.67
	Total	0.49 \pm 0.09	0.48-0.50	0.24	0.87

Discussion

Anterior anus, anteriorly displaced anus, anterior ectopic anus, anteriorly anus, or short perineal body are synonyms for the same anomaly. However, several investigators claim it to be the major cause of constipation in children and it is reported to be more common in the female^{7,8}. Hedren, Leape, and Ramenofsky reported occurrence of constipation with anterior anus in many patients^{5,9}.

In 1958 Bill et al described anterior anus as a form of imperforated anus. In 1978 two separate reports explained cases of constipation, finally diagnosed as ectopic anus¹⁰. In most studies the diagnosis was relied on inspection only. It mostly described that when anus was obviously placed more anteriorly it must be termed ectopic anterior anus. Sometimes it is difficult, even for experienced pediatrician to diagnose this malformation simply with inspection. According to Reisner et al measurements the mean API was 0.44 and 0.53 in girls and boys respectively (SD=0.05), and in 4-18 months old infants, the mean API was 0.56 (SD= 0.04) in boys, while it was 0.4 (SD=0.06) for girls. No significant differences

were found between the values of neonates and infants⁴. In study by Abdolkabir Genc in 2002, measurement of API was modified to give a more reliable value¹⁰.

According to their measurements, API was 0.46 in girls (SD=0.08), and 0.53 (SD= 0.03) in boys⁶. The results of our study were compatible with the latter study. The differences between the results of our study and Reisner study are possibly due to different measurement techniques. Using transparent scotch tape for measurement, we decreased the possibility of sliding to left or right and increased precision and accuracy of our measurements compared to previous similar studies in which ruler tapes were used instead.

In our study, mean API \pm 2SD was considered as the normal position of anus, thus 97% of female neonates as well as 97.5% of male neonates had a normally positioned anus (didn't have ectopic anus) (Figure 3). Therefore 3% of female neonates and 2.5% of male neonates required further diagnostic investigations. Even in the Abdolkabir's study group

of 60 neonates, three girls (5%) were seen to fall out of the given limits¹⁰.

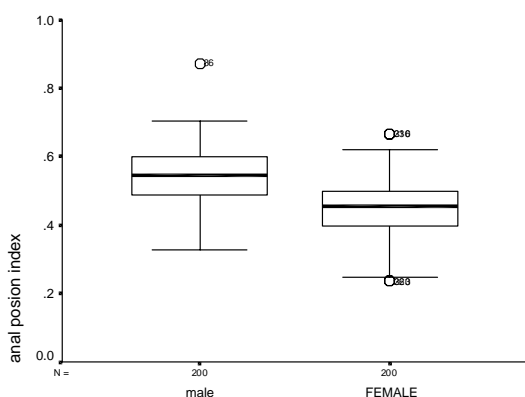


Figure3. Comparing API between females and males.

We think that measuring API in the newborn will help identify the anteriorly located anus both in and girls, which is not easy to detect at the first sight. API is simply a means to suspect ectopic anus and it is never prudent to decide for surgery just for an abnormal API.

Although growth curves and indices are of the most useful tools for children evaluation, but they are developed in developed countries and their efficacy for our society is in doubt. For the first time in Iran, with this study we tried to offer an index (guide) for diagnosing anorectal malformations in the first examination, hence patients who fall out of the

limits could be referred for further examinations such as radiologic studies (computed tomography, magnetic resonance imaging)¹¹, neurological (electromyogram and anorectal manometry)¹², and urologic examinations, before any surgical intervention⁷. In our clinical practice, most of these patients visited firstly by pediatrician and then referred to pediatric surgeon for evaluation. However in anatomic books, normal position of anus is defined as mid point of coccyx to fourschette (in girls) or scrotal crease (in boys) distance, but it is not defined for all the population (children vs. adults, alive vs. cadaver), or in other anatomy reference, the normal position of anus defined as the surface opening of the anal canal situated about 4 cm below or in front of the tip of the coccyx in the cleft between the two buttocks¹³.

Our study present a simple effective method for evaluation of children referred for chronic constipation, and pediatricians can determine normal position of anus by simple tools. Also it is helpful for pediatric surgeons to decide for the most accurate position of anus and to avoid anorectoplasty complications such as fecal incontinence¹⁴ and constipation by improper technique for the placement of anus^{2,10}.

Acknowledgment

Authors would like to thank Dr. L.Aghily and Dr. M.Soltani for their efforts and cooperation.

References

- Weinberg G, Boley SJ. Anorectal continence and management of constipation. In: Ashcraft KW, Holder TM. *Pediatric Surgery*. 3rd ed. Philadelphia: Saunders Company; 2000: p502-510.
- Pena A, Hong AR. Anorectal malformations. In: Mattei P. *Surgical Directives Pediatric surgery*. Philadelphia: Lippincott Williams & Wilkins; 2003: p413-420.
- Edward MK, Pena A. Anorectal malformation. In: O'Neill JA, Rowe MI, Grosfeld JL, Fonkalsrud EW, Corna AG. *Pediatric surgery*. 5th Ed. New York: Mosby Company; 1998: p1425-1488.
- Upadhyaya P. Mid- anal sphincteric malformation, cause of constipation in anterior perineal anus. *J pediatr surg* 1978; 13: 627-630.
- Ramenofsky ML. Anterior ectopic anus: A common cause of constipation in children. *J Pediatr surg* 1978; 13: 627-930.
- Riesner SH, Sivan Y, Nitzan M, Merlob P. Determination of anterior displacement of the anus in newborn infant and children. *Pediatrics* 1984; 73: 216-217.
- Gence A, Taneli C, Tansug N, Kasirga E, Yilmaz D, Kucukoglu T, et al. Evaluation of the location of the Anus by a modified Technique in the neonate *J Pediatr surg* 2002; 37(1): 80-82.

8. Shah AJ, Bhattachrjee N, Patel DN, Ganatra JR. Anal shift: preliminary results. *J Pediatr surg* 2003; 38(2): 196-8.
9. Hendren WH. Constipation caused by anterior location of the anus and its surgical correction. *J pediatr Surg* 1978; 13: 505-511.
10. Rintala R. Constipation is a major functional complication after internal sphincter-saving posterior sagittal anorectoplasty for high and intermediate anorectal malformations. *J Pediatr Surg* 1993; 28:1054.
11. Nievelstein RAJ, Vos A, Valk J. Magnetic Resonance Imaging in children with anorectal malformations: Embryologic implications. *J Pediatr Surg* 2002; 37(8): 1146-50.
12. Schuster T, Joppich I, Schneider K, Jobst G. A computerized vector manometry study of the so-called ectopic anus. *Pediatr Surg int* 2000; 16(1-2): 8-14.
13. Chaurasia BD. *Human Anatomy. regional and applied, volume two, lower limbs and abdomen.* Delhi, India: CBS publishers and distributors; 2000: p335.
14. Ludman L, Sptiz L, Kiely EM. Social and emotional impact of faecal incontinence after surgery for anorectal abnormalities. *Arch Dis Child* 1994; 71:194.

Archive of SID