

Original Article

Evaluation of ECG changes after Radiotherapy of left chest wall by Electron in patients with left breast cancer who receive Anthracycline based chemotherapy following mastectomy

J. Emami MD*, S. Hemati MD*, K. Mohammadian MD**

ABSTRACT

Background: Cardiovascular damage after Radiotherapy of left chest wall for left breast cancer is a potential fear, therefore studying both the possible causes of radiation-induced heart damage and preventive measures are crucial issues in radiation therapy of breast cancer. The present study investigates noninvasively the possible acute and chronic ECG changes and their incidences after Radiotherapy in patients with left sided breast cancer who have received 6-8 courses of Anthracycline based chemotherapy following mastectomy.

Methods: 56 patients with breast cancer (invasive ductal carcinoma) who had been undergone modified radical mastectomy, adjuvant Anthracycline based chemotherapy, and left sided chest wall electron therapy with direct field, have been evaluated. All patients investigated with physical examination and standard 12 leads ECG before, and immediately after completion of radiation therapy, and 6 months afterward.

Results: New electrocardiographic changes after therapy were seen in 3 patients (5.35%) and reduced to 2 cases (3.57%) after 6 months. there was no significant difference in T wave findings before and after radiation therapy ($P=0.521$). Also there wasn't any correlation between stage of cancer and any changes in ECG findings after radiation therapy ($P=0.56$).

Conclusion: There were no clinical cardiac symptoms or signs after Radiotherapy. Most affected leads in ECG were V1-V4 and the main abnormality was Inverted T wave. This findings suggest that the most acute and chronic electrocardiographic effect of irradiation on heart is repolarization abnormality.

This study suggests that there are no significant ECG changes after Radiotherapy of left chest wall by electron beam in patients with left sided breast cancer who has received Anthracycline based chemotherapy following mastectomy. Also Radiotherapy by electron doesn't induce any clinical cardiac symptoms and signs in these patients.

Therefore, we recommend using electron beam for Radiotherapy of patients with left sided breast cancer after radical mastectomy if Anthracycline based chemotherapy, has been administered.

Keywords: Electrocardiogram changes, Radiation therapy, Anthracycline based Chemotherapy.

Post-operative, adjuvant Radiotherapy is increasingly used as an integral part of the primary treatment of breast cancer and now, over than 70% of women with breast cancer have radiotherapy as an integral part of their primary treatment¹. This is owing to the increase in conservative surgery following which Radiotherapy of the remainder of the breast tissue is required². In addition, a higher proportion of patients undergoing mastectomy are receiving radiotherapy as a part of combined modality therapy owing to higher stage

disease. The common rationale for post operative radiotherapy has been to reduce local recurrence³, but recently there have been reports of breast cancer cause-specific survival advantage with Radiotherapy³⁻⁶. However, recent studies of radiation toxicity in the treatment of breast cancer show that the effect of radiation on normal tissue can constitute a significant clinical problem, and increase cardiac mortality which particularly, may offset any potential survival benefit of treatment^{4,7,8}.

The severity of cardiac disease induced by radiation

* Assistant Professor, department of Radiation Oncology, Isfahan university of medical sciences, Isfahan, Iran.

** Resident, department of Radiation Oncology, Isfahan university of medical sciences, Isfahan, Iran.

Correspondence to: Dr. Simin Hemati, Department of Radiation Oncology, sayed-ol-shohada hospital, Isfahan university of medical sciences, Isfahan, Iran.

E-Mail: Hematti @med.mui.ac.ir.

therapy (RT) did not become widely recognized until the 1990s, when, for instance, it became apparent that adverse cardiac effects almost completely outweighed the overall survival benefit achieved with RT in most of the randomized trials in early stage breast cancer⁹.

Radiation to the mediastinum may cause cardiac changes. In autopsies and in clinical studies, fibrosis and thickening of the pericardium has occasionally led to pericardial concrete and tamponade^{9,10,11}, myocardial fibrosis^{10,11,12}, endocardial fibrosis which sometimes causing valve disease^{11,12,13}, and coronary artery disease owing to coronary artery fibrosis or accelerated atherosclerosis, or both^{9,11,12,14}. Also in some studies excess cardiac mortality has been reported in long-term follow up of breast cancer patients treated with some type of radiation therapy^{15, 16}. ECG changes are one of the earliest effects of radiation therapy on heart that can show acute and chronic progression of Radiation-induced heart disease (RIHD)^{11, 13, 14}. It is unknown whether ECG changes are related to only Radiation or not, because some chemotherapy drugs have the ability of sensitizing the heart to RIHD and also can induce many types of ischemic heart disease (IHD) by themselves^{11, 12, 15}.

The present study noninvasively investigates the possible acute and chronic ECG changes and their incidence after radiotherapy following modified radical mastectomy and anthracycline based combination chemotherapy in patients with left sided breast cancer.

Subjects and Methods

The treatment plans of 56 patients who had received Radiotherapy by electron beam for left sided invasive ductal breast carcinoma reviewed. All patients had undergone modified radical mastectomy including axillary dissection and pathological diagnosis of type of breast cancer had been established. Our data collection was performed prospectively and sampling method was simple. Each patient received six or eight courses of standard chemotherapy before Radiotherapy.

Chemotherapy included Doxorubicin, 360-450 mg/m², Cyclophosphamide, 3600-4800 mg/m², and 5FU, 3600-4800 mg/m². The prescribed total dose to the target was 5000 cGy, delivered in 200 cGy per fraction, five fractions per week, by 8 or 10 MeV

Electron beams. Choosing the energy of beam was considered by thickness of chest wall. The target volume included the left chest wall and lymphatic drainage of breast. All patients received this plan for exact five weeks. Before intervention we recorded all demographic characteristics of each patient in data collecting sheets. Evaluations were done before and immediately after completion of radiation therapy, and 6 month afterward. The investigation consisted of history, physical examination, and a standard 12-leads electrocardiogram. Any symptom, sign, or new changes in ECGs were detected (e.g. P wave, T wave, ST segment, or QRS changes). All ECG changes were evaluated and recorded by one observer in data sheets. Statistical comparisons were made using the McNemar test as this makes no assumptions about distribution. Statistical software was SPSS 10.0. We defined that p-value less than 0.05 was significant.

Results

Fifty six patients were studied totally. Mean of age was 47.92 ± 1.61 (mean \pm standard error of mean).

Four patients (7.1%) were in stage I of invasive ductal carcinoma, six patients (10.7%) were in stage IIA, twenty nine patients (51.7%) were in stage IIB, thirteen patients (23.2%) were in stage IIIA, and four patients (7.2%) were in stage IIIB. Thirty nine patients (69.6%) had received six, and 17 patients (30.3%) had received eight courses of chemotherapy before radiation therapy.

Before radiation therapy, only three patients (5.3%) had abnormal ECGs; one had poor progression of R wave, one had ST segment depression in V1-V4, and one had ST segment depression in II, III, avf leads. No patient had any abnormality in P or T wave before irradiation.

New electrocardiographic changes after therapy were seen in 3 patients (5.35%) After about 6 months, 1.78% of ECG changes (T wave changes) resolved and 3.57% remained.

Frequency Distribution of new electrocardiographic changes after radiation therapy have been shown in Figure 1 (N=56).

McNemar test showed that there is no significant difference in T wave findings before and after radiation therapy (P=0.521). We didn't find any other new electrocardiographic changes immediately after irradiation and six months later.

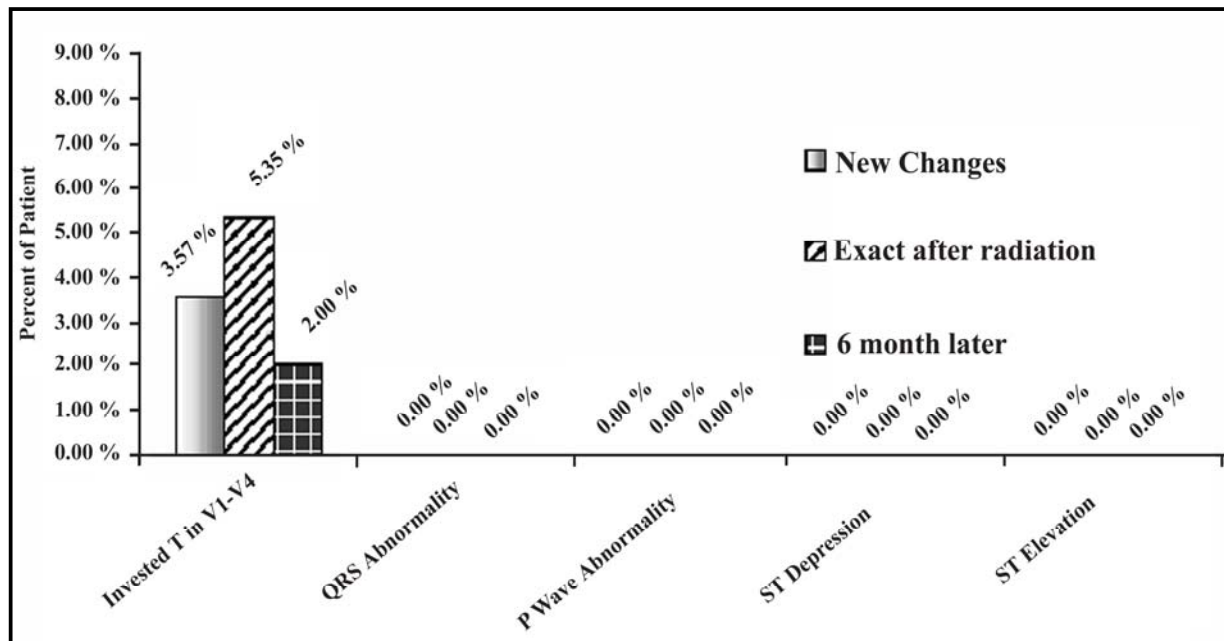


Figure 1. Frequency distribution of electrocardiographic changes after radiotherapy of chest wall by electron beam in patients with left breast cancer who treated with chemotherapy following mastectomy.

Also there wasn't any correlation between stage of cancer and any changes in ECG findings after radiation therapy ($P=0.56$).

Discussion

Radiation may induce both acute and chronic cardiac changes. After accidental fatal radiation, acute changes include myocardial perivascular edema and hemorrhage, leukocytes scattered in the epicardium, and pericardial effusion¹⁶. Some of these changes can in turn change the pattern of ECG. Therefore, sometimes the initial manifestation of various types of RIHDS can be a new ECG change^{11, 14, 16}. Injury to the heart is a possible complication of the radiation therapy. Pericarditis and pericardial effusion have been regarded as the most common side effects of cardiac irradiation²¹. The long term results of the early trials on postoperative Radiotherapy using outmoded techniques show an increase risk of cardiac toxicity²⁰, but modern techniques of irradiation, dose fractionation, and reduction of heart volume irradiated in most malignancies have substantially reduced the frequency of these complications during the last decade²⁴.

A large institutional study on patients with breast cancer treated with modern techniques

(without adjuvant chemotherapy) did not show an increased risk with long follow up²². Also late cardiac mortality has not been seen in institution-based studies using limited cardiac irradiation with CMF chemotherapy²³.

There are some experiences about ECG changes after radiotherapy with or without chemotherapy in patients with breast cancer, but in most of them photon beam with tangential fields have been used^{4, 5, 8, 11}, and there are only few studies about using electron beam by direct field²³.

Incidence of cardiac toxicity and new ECG changes after Radiotherapy differ in various studies^{4, 5, 8, 11}. This is true for Radiotherapy and Chemotherapy, too^{12, 14, 16, 17, 18}. Most previous data show that complications of radiotherapy of chest are more occur when they accompanied with chemotherapy (e.g. anthracycline based)^{12, 14, 16, 17, 18}, but all these experiences have been performed by using photon beams with tangential fields which could encompass a distinct heart volume in irradiated region^{4, 5, 8, 11, 12, 14, 16, 17, 18}. For example, a large study in Milan suggests that cardiac complications including ECG changes increase by using anthracycline based chemotherapy (ST-T change=3.8%) and this cardiac risk increases further in patients receiving Radiation therapy to the left side of the chest (ST-T change =9.7%)¹⁹.

In our study, most patients were in stage IIb. Incidence of new electrocardiographic changes due to radiation after surgery and chemotherapy was about 5.35%, which dropped to 3.57% after 6 months. This incidence is lower than some previous studies and is much lower than some others specially in situation of radiotherapy after combination chemotherapy^{4,5,8,11,12,14,16,17}. The most reasonable explanation for this encouraging result might be the use of electron beam with appropriate energy for treating the left chest wall. As we know, electron beam has a very rapid dose fall off beyond its build up region so that we could expect that a limited dose has delivered to the heart.

The most affected leads in our samples were V1-V4 and the main abnormality was Inverted T wave. This finding suggests that the most acute and chronic electrocardiographic effect of irradiation on heart is repolarization abnormality. There were no clinical cardiac symptoms or signs even in patients with ECG changes. Lindahl et al also showed in their study that a high incidence of T-wave abnormality following left-sided irradiation for breast carcinoma could be exist, but in short term, these ECG changes were functionally insignificant¹⁷.

In summary, cardiac toxicity and mortality represents, needless to say, a fatal complication, therefore methods for an early identification of the high risk patients and choosing the suitable treatment modality according to the patient characteristics is crucial. One of the most considerable subjects in radiotherapy of chest wall is reducing its cardiac toxicity. Although ECG changes are not specific for determination the type of cardiac toxicity and we may need more allocated tools, but it can show many of early cardiac changes. In the other hand, our patients didn't show any clinical symptoms or signs. Based on this experience and comparing these data with other studies we believe that Radiotherapy by electron is a safe modality for treating the left chest wall and specially can be useful in patients who have received chemotherapy (e.g. anthracycline based). It could be expected that by using electron beam with appropriate energy we can offer survival advantages beside local control to our breast cancer patients. Yet, many studies by better procedures such as Echocardiography and radionuclide scan must be done to discover the relation between Radiotherapy by electron and its possible cardiac toxicity.

References

1. Harnett AN, George WD. *Surgical cases-surgery and radiotherapy*. In: *Scottish breast cancer audit 1987 & 1993*. Edinburgh: *Scottish cancer therapy Network/Crown*. 1996: 30-45.
2. Forrest AP, Stewart HJ, Everington D, Prescott RJ. *On behalf of Scottish cancer trials breast group. Randomized controlled trial of conservative therapy for breast cancer: 6-year analysis of the Scottish trial*. *Lancet* 1996; 348:708-13.
3. Pierce LJ, Lichter AS. *Postmastectomy radiotherapy: more than locoregional control?* *J Clin Oncol* 1994; 12: 444-6.
4. Canney PA, Deehan C, Glegg M, Dickson J. *Reducing cardiac dose in post-operative irradiation of breast cancer patients: the relative importance of patient positioning and CT scan planning*. *The Br J Radiol*. 1999; 72:986-993.
5. Overgaard M, Hansen PS, Overgaard J, Rose C. *post-operative radiotherapy in high-risk premenopausal women with breast cancer who received adjuvant chemotherapy*. *N Eng J Med* 1997; 337:1494-55.
6. Rutqvist LE, Johansson H. *Mortality by laterality of primary tumor among 5500 breast cancer patients from Swedish cancer registry*. *Br J Cancer* 1990; 61:866-8.
7. Trott KR. *Cardiovascular system morbidity of radiotherapy*. In: *PN plowman, TJ McElwain, T Meadows, editors. Complications of cancer management*. Oxford: *Butterworth and Heinemann*, 1991: 177-83.
8. Gagliardi G, Lax I, Ottolenghi A, Rutqvist LE. *Long term cardiac mortality after radiotherapy of breast cancer- application of the relative seriality model*. *Br J Radiol* 1996; 69:839-46.
9. Gagliardi G, Lax I, Rutqvist LE. *Partial irradiation of the heart*. *Seminars in radiation oncology*. 2001; 11(3):224-233.
10. Cohn KE, Stewart JR, Fejardo LF, Hancock EW. *Heart disease following radiation*. *Medicine* 1967; 46:281-298.
11. Byhardt R, Brace K, Ruckdeschel J, Chang P, Martin R. *Dose and treatment factors in radiation-related pericardial effusion associated with the mantle technique for hodgkin's disease*. *Cancer* 1975; 35: 795-802
12. Broslus FC, Waller BF, Roberts WC. *Radiation heart disease. Analysis of 16 young necropsy patients who received over 3500 rads to the heart*. *Am J Med* 1981; 70: 519-530.
13. McRaynolds RA, Gold GL, Roberts WC. *Coronary heart disease after mediastinal irradiation for hodgkin's disease*. *Am J Med* 1976; 60:39-45.
14. Dollinger MR, Lavine DM, Foye LV. *Myocardial infarction due to postirritation fibrosis of the coronary arteries*. *JAMA* 1996; 195:316-319.

15. Host H, Brennhovd I, Leob M. Post operative radiotherapy in breast cancer—long-term results from the Oslo study. *Int J Radiat Oncol Biol Phys.* 1986; 12:727-732.
16. Schultz-Hector S. Radiation-induced heart disease: review of experimental data on dose response and pathogenesis. *Int J Radiat Biol.* 1992; 61:149-160.
17. Lindahl J, Strender LE, Larsson LE, Ungaard A. Electocardiographic changes after radiation therapy for carcinoma of the breast. Incidence and functional significance. *Acta Radiol Oncol* 1983; 22(6):433-40.
18. Rayberg M, Nielson D, Skovsgaard T, et al. Epirubicin cardiotoxicity: an analysis of 469 patients with metastatic breast cancer. *J Clin Oncology* 1998; 16:3502-8
19. Charles M. Haskell. *Cancer Treatment*, 2001; W.B. Saunders Company pp 580.
20. DeVita VT, Hellman S, Rosenberg S, et al. *Cancer: principle and practice of oncology*, 2001; Lippincott Williams & Wilkins pp 1677.
21. Stewart JR, Fajardo LF. Radiation induced heart disease: an update. *Prog Cardiovasc Dis* 1984; 27:173
22. Nixon AJ, Manola J, Gelman R, et al. No long term increase in cardiac related mortality after breast conservative surgery and radiation therapy using modern techniques. *J Clin oncol* 1998; 16:1374
23. Gustavsson A, Bendahl P-O, Cwikiel M, et al. No serious late cardiac effect after adjuvant radiotherapy following mastectomy in premenopausal women with early breast cancer. *Radiother oncol* 1999; 43:745
24. Stewart JR. Normal tissue tolerance irradiated of the cardiovascular system. *Front Radiother Oncol.* 1989; 23:302.