

Case report**Cerebral Venous Thrombosis Presented as Subarachnoid Hemorrhage and Treated with Anticoagulants**

M. Zare MD*, P. Mirabdolbaghi MD**

ABSTRACT

A 45-year-old woman was brought into the emergency room of Al-Zahra hospital, Isfahan, after her first generalized tonic-clonic seizure and a history of thunderclap occipital headache ten days before the first seizure. Examination revealed mild confusion and slight left hemiparesis with facial weakness and no meningeal irritation signs. CT scan showed subarachnoid hemorrhage (SAH) and MRI demonstrated left lateral, sigmoid and sagittal sinus thromboses. Angiography was normal. She was treated by anticoagulants in spite of hemorrhagic parenchymal lesion.

Key words: Cerebral venous thrombosis, Subarachnoid hemorrhage, Anticoagulant therapy

JRMS 2005; 10(4): 251-254

Cerebral venous thrombosis is an uncommon cause of cerebral infarction compared to arterial diseases but is an important consideration for its potential morbidity. Venous thrombosis may occur with headache and cranial nerve palsies¹. Headache is the presenting symptom in 70%–100% of cases. Thunderclap headache, typical of subarachnoid haemorrhage is reported in more than 10% of cases². Seizures and hemiparesis, possible manifestations of subarachnoid haemorrhage, occur in about one thirds of cases with CVST³ It is important to establish whether subarachnoid hemorrhage is due to CVST, as this requires a completely different treatment from subarachnoid hemorrhage due to a leaking aneurysm.

Case report

In August 2004, a 45-year-old woman was brought into the emergency room of Al-Zahra hospital, Isfahan, Iran, after her first generalized tonic-clonic seizure. She had a second seizure on just on arrival at the hospital. Ten days

before, She had her first seizure, followed by a thunderclap, occipital headache and vomit. Her past medical history denoted common migraine for some years. She had had four pregnancies, carried to term. She did not smoke but was passive smoker. She had not used contraceptive pills before. There was no family history of migraine, epilepsy, brain hemorrhage, or thrombosis. Examination after her second seizure showed mild confusion and slight left hemiparesis with facial weakness, and no meningeal irritations. She was not feverish and her baseline laboratory tests were normal. A brain CT Scan was done urgently as we suspected a subarachnoid hemorrhage which was, in fact, detected in the right Sylvian fissure and posterior temporal sulci (Figure 1). MRI showed parenchymal damage in the right parieto-occipital region (Figure 2). MRV represented left sigmoid, lateral, straight and superior sagittal sinuses obstruction (Figure 3). MRA was normal. (Figure 4). Angiography with selective catheterisation of the

*Associate Professor, Department of Neurology, Isfahan University of Medical sciences, Isfahan, Iran.

**Resident, Department of Neurology, Isfahan University of Medical sciences, Isfahan, Iran.

Correspondence to: Dr Mohammad Zare, Al-Zahra University Hospital, Isfahan, Iran. E-Mail: zare@med.mui.ac.ir.

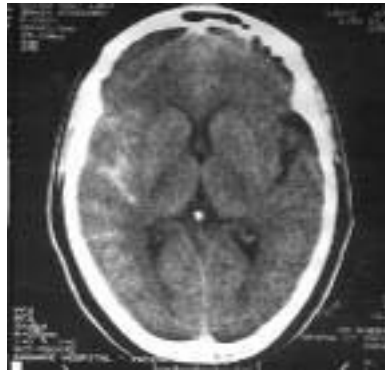

Figure 1. Hemorrhage detected in the right Sylvian fissure and posterior temporal sulci

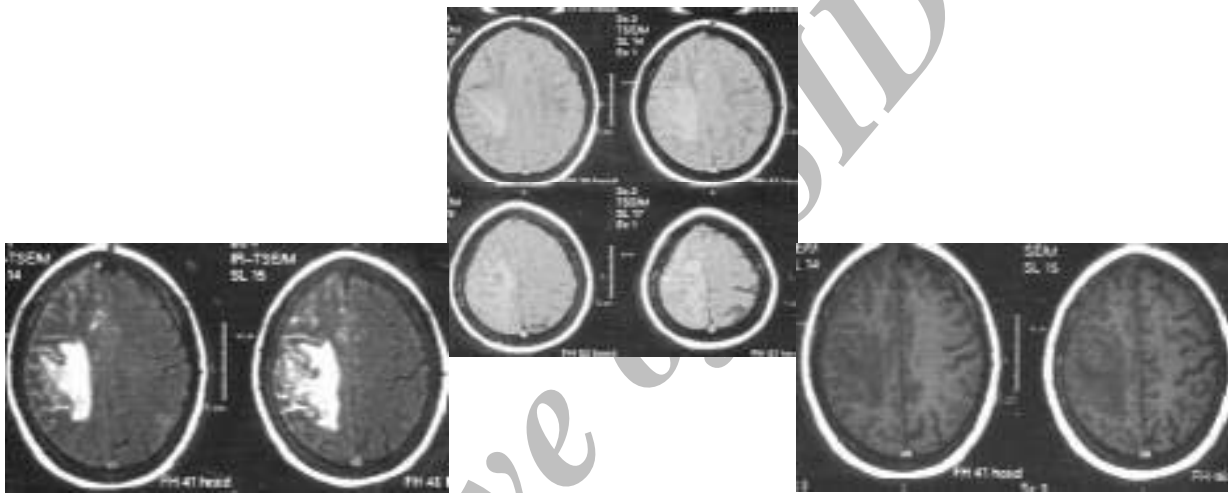


Figure 2. A hemorrhagic infarct in the right parieto-occipital region

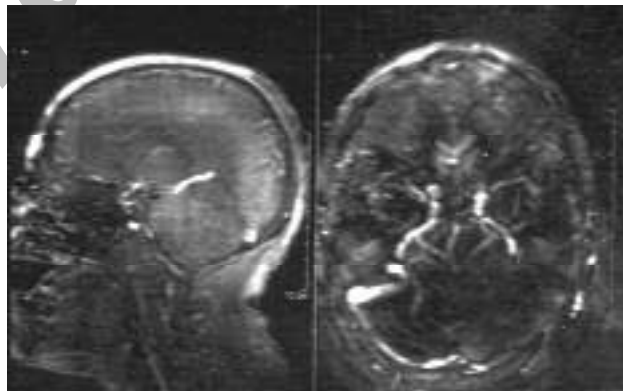


Figure 3. Left sigmoid, lateral, straight and superior sagittal sinuses obstruction

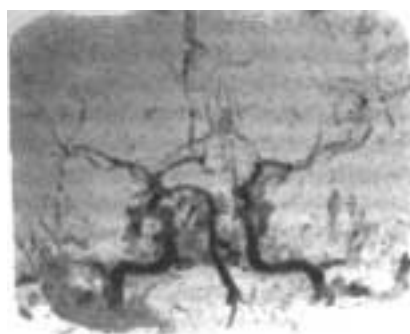


Figure 4. Normal MRA

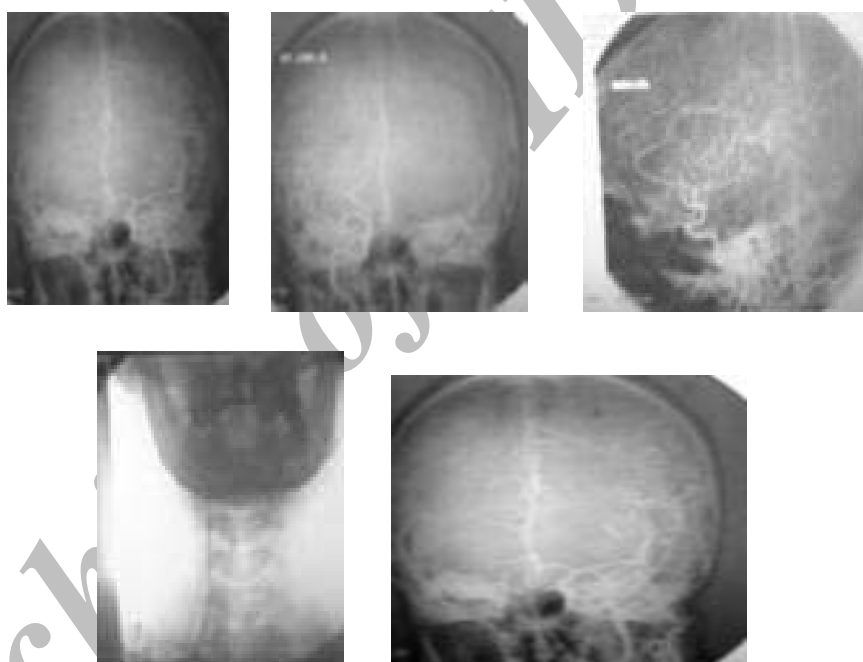


Figure 5. Angiography with selective catheterization of the carotid and vertebral arteries

carotid and vertebral arteries was done to look for an aneurysm. However, no aneurysms were found. Subsequent examination of the angiographic venous phase showed avascularity of the right temporo-occipital regions with no enhancement of the superior sagittal and left lateral sinuses (Figure 5).

with parenchymal damage. Transcranial echodoppler ruled out vasospasm of intracranial arteries. Intravenous heparin and phenytoin was started. Because of phenytoin drug reaction, it was changed to sodium valproate later. She was discharged with slight left

hemiparesia, taking warfarin and sodium valproate 600 mg daily. She was screened for hereditary prothrombotic conditions (Factor V Leiden mutation, deficiency of proteins C and S, antithrombin III and prothrombin gene mutations) but no abnormalities were found except low levels of proteins C and S which would be rechecked after warfarin discontinuation.

Discussion

Intracranial venous sinus thrombosis (CVST) is an infrequent condition with a variety of

causes. Most reported cases have been adult women. CVST presents with a wide spectrum of symptoms and signs. Chief complaints are headache, vomiting, transient visual obstruction, focal or generalized seizures, lethargy and coma ². Headache is the presenting symptom in 70%–100% of cases. Thunderclap headache, typical of subarachnoid hemorrhage is reported in more than 10% of cases ³. Seizures and hemiparesis, possible manifestations of subarachnoid hemorrhage, occur in about one thirds of cases with CVST ⁴. Cerebral edema, venous infarction, and unexplained intracerebral hemorrhage are among the possible consequences of CVST ⁵. Rarely, CTscan may show a subarachnoid hemorrhage ^{4, 6}. Patients with CVST may, as in our case, present with both clinical and radiologic features which mimic an acute subarachnoid hemorrhage from a bleeding aneurysm. Subarachnoid hemorrhage in the course of CVST might arise

from the rupture of a dilated tributary vein of an involved sinus, with the same mechanism as for venous intracerebral hemorrhage ⁶. The subarachnoid hemorrhage of the right Sylvian fissure in our patient may have originated from the rupture of the right Sylvian vein. The best treatment option for CVST seems to be anticoagulants even when a hemorrhage is present ⁷. There was no known risk factor in this patient. There was low levels of C and S proteins but was not reliable because of warfarin administration ⁸. CVST has to be taken into account as a rare, albeit possible, cause of subarachnoid hemorrhage. It is important to establish whether subarachnoid hemorrhage is due to CVST, as this requires a completely different treatment from subarachnoid hemorrhage due to a leaking aneurysm.

References

1. eMedicine - Cerebral Venous Thrombosis: Article by W Alvin McElveen, [<http://emedicine.com/neuro/topic642.htm>, 2004, February 11]
2. Jose Biller and Besty B. Love *Vascular disease of the nervous system in* : Walter G. Bradly , Robert B Daroff , Gerald M. Fenichel , Joseph Jankovice , editors. *Neurology in clinical practice* , volum II 4th ed . Boston. Butterwoth Heinemann . 2004:1244-1245.
3. SF de Bruijn, J Stam and LJ Kappelle, *Thunderclap headache as first symptom of cerebral venous sinus thrombosis. CVSTStudy Group. Lancet* 348 (1996) . 1623–1625.
4. H Allroggen and RJ Abbott, *Cerebral venous sinus thrombosis. Postgrad Med J* 76 (2000), 12–15.
5. Jose Biller and Besty B. Love *Vascular disease of the nervous system in* : Walter G. Bradly , Robert B Daroff , Gerald M. Fenichel , Joseph Jankovice , editors. *Neurology in clinical practice* , volum II 4th ed . Boston . Butterwoth Heinemann . 2004:1243.
6. A Villringer, S Mehraen and KM Einhüpl, *Pathophysiological aspects of cerebral sinus venous thrombosis. J Neuroradiol* 21 (1994), pp. 72–80.
7. SF de Bruijn and J Stam, *Randomized, placebo-controlled trial of anticoagulant treatment with low-molecular-weight heparin for cerebral sinus thrombosis. Stroke* 3 (1999), 484–488.
8. Jose Biller and Besty B. Love *Vascular disease of the nervous system in* : Walter G. Bradly , Robert B Daroff , Gerald M. Fenichel , Joseph Jankovice , editors. *Neurology in clinical practice* , volum II 4th ed . Boston . Butterwoth Heinemann . 2004:1227.