

Case Report:**Septic Thrombophlebitis of the Cephalic Vein Caused by a Peripherally Inserted Venous Catheter**

M. Mirmohammadsadeghi MD, O. Aghadavoudi MD***

ABSTRACT

Septic thrombophlebitis of a vein is a rare but life-threatening complication of an intravascular (IV) catheter placed percutaneously in the veins. Most published clinical experiences with IV catheters, mainly in the outpatient settings, have reported very low rates of catheter-related bloodstream infection compared to rates with central venous catheters placed in a subclavian or internal jugular vein. Most of the complications reported with IV catheters have been non-infectious, particularly sterile phlebitis or thrombosis. We report a case of cephalic vein suppurative thrombophlebitis from an intravascular catheter and offer guidelines for diagnosis and management of this complication.

Key words: Septic thrombophlebitis, Intravascular catheter, Suppurative thrombophlebitis

JRMS 2005; 10(4): 244-247

Intravascular (IV) catheter sepsis is a widely recognized complication of IV therapy or monitoring¹. The most common causative organisms are *Staphylococcus aureus*, gram-negative bacilli and *Candida* species². Most causative organisms arise from the skin; staphylococci are responsible for two-thirds of the infections, with *Staphylococcus aureus* responsible for 5% to 15%³. Significant complications occur in about 25% of cases and include septic shock, suppurative thrombophlebitis, metastatic infection, and endocarditis⁴. In critically ill patients, intravenous lines cause at least 23% of nosocomial bloodstream infection, which has a mortality of 25% and is associated with a longer stay in intensive care unit³. However, few data exist concerning the best strategy for managing septic thrombophlebitis, especially when medical therapy fails².

Although a surgical approach has been emphasized in patients with peripheral vein suppurative thrombophlebitis, anticoagulation therapy may be a useful alternative in the

treatment of patients with central vein infection⁵. Surgical removal of the vein, the treatment usually recommended for peripheral vein suppuration, is technically difficult. Patients with central venous septic thrombophlebitis can be successfully managed with prompt catheter removal, intravenous antibiotics, and anticoagulation, but surgery should be considered when there is a suppurative focus around the vein^{6,7}.

Case History

A 65-year-old man with a past history of 30 pack-year smoking without diabetes was admitted with diagnosis of three coronary vessels disease and a two-week history of unstable angina. An urgent coronary artery bypass grafting (CABG) was done for him with grafting four vessels without any complication intraoperatively. The induction and maintenance of anesthesia were done after taking an intraarterial line through the right radial artery for continuous blood pressure monitoring. After

*Assistant Professor of Cardiovascular Surgery, Department of Surgery, Isfahan University of Medical Sciences, Isfahan, Iran.

**Assistant Professor, Department of Anesthesia, Isfahan University of Medical Sciences, Isfahan, Iran.

Correspondence to: Dr. Mohsen Mirmohammadsadeghi, Chamran Heart Hospital, Isfahan, Iran.

E-mail:mirmohammsadeghi@med.mui.ac.ir

induction of anesthesia and tracheal intubation, a three-lumen central venous catheter was placed through the right subclavian vein. The CABG was done by on-pump route using cardiac arrest with antegrade and retrograde blood cardioplegia. The patient was discharged from the cardiac intensive care unit after 48 hours.

On the 5th postoperative day, he complained of a painful swelling of the lateral side of the left forearm in the domain of the cephalic vein. On examination, he was febrile (38 °C) and there was local erythema and tenderness of the left forearm. Investigations showed a hemoglobin of 7.9 mmol/L (normal values 8.7-10.5), WBC 9.2 10^9 /L (normal values 4.0-10.0), thrombocytes 495 10^9 /L (normal values 140-340) and raised serum C-reactive protein 180 mg/L (normal value <5). Chest X-ray showed normal pattern. The peripheral IV catheter was removed from the vein and considering the diagnosis of superficial thrombophlebitis, conservative managements including local heat, limb elevation and empiric antimicrobial treatment were begun. Intravenous vancomycin was administered as 1 gram every 12 hours. Ceftriaxone was also given as 1 gram three times daily. The microbiologic study reported *Staphylococcus aureus* colonization susceptible to vancomycin. On the 6th postoperative day, the redness and swelling became more significant. The day after, three separate abscesses developed along the cephalic vein pathway (Figure 1) and were drained. Because of continuing the suppurative drainage after the next 24 hours, the diagnosis of suppurative (septic) thrombophlebitis was made and the affected cephalic vein was surgically excised (Figure 2). Specimen of the affected vein was sent for pathology. The wound was left open to let secondary healing. The microbiology study of the specimen revealed *Staphylococcus aureus*. The patient continued receiving intravenous antimicrobial therapy. Both transthoracic and transoesophageal echocardiography were normal. The pathology results also confirmed the diagnosis of septic thrombophlebitis (Figure 3). Blood cultures subsequently

grew *Staphylococcus aureus*. The patient received intravenous vancomycin for 2 weeks and made a full recovery. Blood cultures (three in all, with intervals of 2 days) after 7 days of incubation did not show *Staphylococcus aureus*. Stool and urine cultures were also negative.

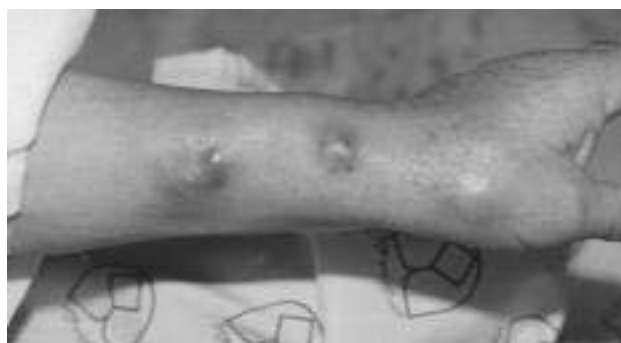

Figure 1. Three separate abscesses along the cephalic vein of the left forearm

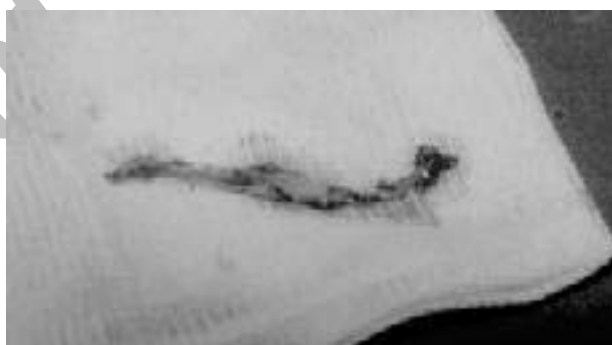

Figure 2. Cephalic vein excised surgically from the left forearm

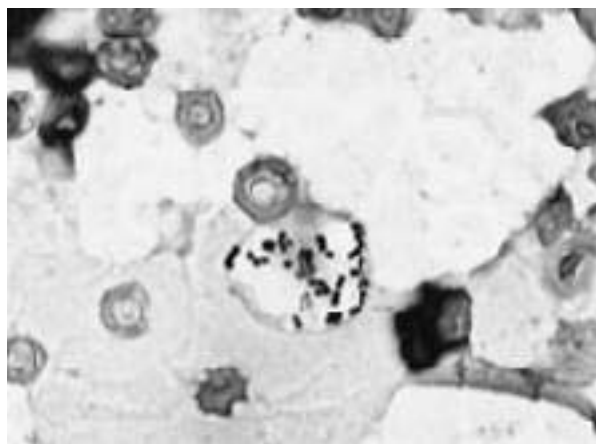


Figure 3. Gram stain of material aspirated from the cephalic vein ($\times 270$).

Discussion

There are two forms of bloodstream infection associated with intravascular devices ⁸:

1) Bacteremia or candidemia, usually related to colonization of the intravascular device but occasionally to contamination of infusate administered through the device; and

2) Infection of thrombus surrounding the catheter, producing septic (suppurative) thrombophlebitis with peripheral venous catheters or septic thrombosis of a great central vein with centrally placed catheters ^{9, 10}. With septic thrombophlebitis, the clinical presentation is that of overwhelming sepsis with high-grade bacteremia or candidemia that characteristically persists after the catheter has been removed.

When first recognized, septic thrombophlebitis of peripheral veins was most frequently encountered in burned patients whose wounds harbored great numbers of microorganisms per gram of tissue ¹¹. It is now an exceedingly rare complication of the small peripheral venous catheters, and is now usually a result of septic thrombus from centrally placed catheters ^{9, 10}. Local inflammation is present less than half the times, as occurred in our patient, and sepsis may not develop until several days after the catheter has been removed.

Expression of pus from the exit site or aspiration of a thrombosed peripheral vein permits immediate confirmation of infection and provides ample grounds to proceed to surgical resection of the involved vein segment. Gram-stain of residual thrombus on the removed central catheter revealing microorganisms also strongly confirms septic thrombosis ¹¹.

Septic thrombophlebitis of peripheral veins is most effectively managed by early resection of the thrombosed vein segment ¹⁰, followed by anti-infective therapy to eradicate peripheral sites of hematogenous seeding, especially with *S. aureus* and *Candida* species. Whereas most infected central venous catheters can be successfully treated by removing the catheter and

a short course of anti-infective therapy, septic thrombosis of the great central veins poses a more difficult problem. If the patient is not critically ill, it can often be managed with intravenous bactericidal antibiotics for 4 to 6 weeks, combined with systemic anticoagulation ¹⁰. Surgical intervention is reserved for refractory sepsis or recurrent septic pulmonary emboli. In our case, resection of the cephalic vein was highly effective. Signs of sepsis resolved almost immediately.

This study indicates that patients who develop catheter-related bacteremia or candidemia must be observed closely, even if there has been a favorable response to initial therapy. Latent foci of deep infection, particularly endocarditis, endophthalmitis, or vertebral osteomyelitis can occur ⁴. Although there is controversy about how long the treatment of nosocomial *S. aureus* bacteremia should continue, 14 days of parenteral antimicrobial therapy has a very high cure rate if the patient responds completely within 3 days ³. With prolonged signs of sepsis, especially with septic thrombosis and high-grade bacteremia, anti-infective therapy should be continued for at least 4 to 6 weeks ³, even if the infected thrombus has been removed.

Standard infection control policies and procedures ⁸, including the use of maximal sterile barriers when IV catheters and peripherally inserted central venous catheters (PICCs) are used should be observed ¹¹. Moreover, regular site care with daily monitoring, should assure low rate of catheter-related bloodstream infection. The morbidity and costs associated with IV catheter sepsis warrant substantial efforts to minimize the incidence of this complication and especially to prevent cases due to *S. aureus* ¹. Septic thrombophlebitis is best prevented by strict asepsis in catheter placement and changing of infusion sites every 48 hours. Total excision of the infected vein remains the treatment of choice.

References

1. Arnow PM, Quimosing EM, Beach M. Consequences of intravascular catheter sepsis. *Clin Infect Dis*. 1993 Jun; 16(6):778-84.
2. Garcia E, Granier I, Geissler A, Boespflug MD, Magnan PE, Durand-Gasselien J. Surgical management of *Candida* suppurative thrombophlebitis of superior vena cava after central venous catheterization. *Intensive Care Med*. 1997 Sep; 23(9):1002-4.
3. Rodriguez-Bano J. Selection of empiric therapy in patients with catheter-related infections. *Clin Microbiol Infect*. 2002 May;8(5):275-81.
4. Tagalakis V, Kahn SR, Libman M, Blostein M. The epidemiology of peripheral vein infusion thrombophlebitis: a critical review. *Am J Med*. 2002 Aug 1;113(2):146-51.
5. Tagalakis V, Kahn SR, Libman M, Blostein M. The epidemiology of peripheral vein infusion thrombophlebitis: a critical review. *Am J Med*. 2002 Aug 1; 113(2):146-51.
6. Mimosz O, Rayeh F, Debaene B. Catheter-related infection in intensive care. *Physiopathology, diagnosis, treatment and prevention*. *Ann Fr Anesth Reanim*. 2001 Jun; 20(6):520-36.
7. Wang FD, Cheng YY, Kung SP, Tsai YM, Liu CY. Risk factors of catheter-related infections in total parenteral nutrition catheterization. *Zhonghua Yi Xue Za Zhi (Taipei)*. 2001 Apr; 64(4):223-30.
8. Maki DG. Infections caused by intravascular devices used for infusion therapy: pathogenesis, prevention, and management. In: Bisno AL, Waldvogel FA, eds. *Infections Associated with Indwelling Medical Devices*. 2nd ed. Washington, DC: American Society for Microbiology; 1994:155-211.
9. Benoit D, Decruyenaere J, Vandewoude K, Roosens C, Hoste E, Poelaert J, Vermassen F, Colardyn F. Management of candidal thrombophlebitis of the central veins: case report and review. *Clin Infect Dis*. 1998 Feb;26(2):393-7.
10. Gillespie P, Siddiqui H, Clarke J. Cannula related suppurative thrombophlebitis in the burned patient. *Burns*. 2000 Mar; 26(2):200-4.
11. Ng PK, Ault MJ, Ellrodt AG, Maldonado L. Peripherally inserted central catheters in general medicine. *Mayo Clin Proc*. 1997; 72:225- 233.

Archive of SID