

Case Report**Vascularized pedicle graft of ipsilateral fibula for recurrent congenital pseudoarthrosis of the tibia***Seyed Esmail Hassanpour\*, Mehdi Rasti\****Abstract**

We have performed the ipsilateral vascularized fibular transfer for the treatment of congenital pseudoarthrosis of the tibia (CPT). In the case under study, the conventional treatment by intramedullary rod and autogenous iliac bone grafting had failed. The follow up took place during the next 4 years and the patient can now walk without assistance. Combining a pedicle ipsilateral fibular transfer with an internal fixation and iliac bone graft may be a good option for the treatment of congenital pseudoarthrosis of tibia.

**KEY WORDS:** Congenital pseudoarthrosis, tibia, vascularized fibular graft, bone graft.

**JRMS 2007; 12(3): 153-158**

Congenital pseudoarthrosis of the tibia (CPT) is an uncommon entity which union is not always easy to achieve<sup>1</sup>. Achieving union of the tibia and fibula in the patients with CPT is still a major challenge. Even if union is achieved, the residual deformities that include nonunion of the fibula, limb length discrepancy, valgus deformity of tibia or ankle, calcaneus deformity, ankle joint arthritis and refracture, are likely to compromise optimal function of the extremity<sup>2</sup>. Although recent advances in surgical techniques have shown much more encouraging results, we still have a long way to reach an ideal treatment<sup>3</sup>. Several treatment options have recommended electrical stimulation at the site of the disease with or without the autogenous iliac bone graft. There are also other treatment options like intramedullary rod placement with autogenous bone graft, Ilizarov bone transposition, pedicle fibula graft and vascularized bone graft<sup>4</sup>. However, each of these

methods has well recognized complications and disadvantages. The operation should include excising all the fibrous tissues at the pseudoarthrosis site, to achieve anatomic alignment of the bone in the sagittal and coronal plane, and the bone grafting of the pseudoarthrosis site with an autogenous iliac crest bone. The reabsorbing of the bone graft and the bone loss in the site of the disease is the most disadvantaged treatment. This method of treatment, leads to a recurrent fracture at the site of the pseudoarthrosis. Minimizing the possibility of refractures and achieving an anatomic alignment of the tibia and the fibula should be the goal of the operative treatment regardless of the treatment modality employed<sup>5</sup>. If we use the vascularized bone, we may decrease the chance of refracture. Two main methods are present for the transfer of vascularized bone to the site of the disease. The methods are the free flap and the vascularized pedicle bone graft. Free flap has many disadvantages

\* Plastic & Reconstructive Surgery Department, Shahid Beheshti Medical University, Tehran, Iran.  
Corresponding Author: Dr Seyed Esmail Hassanpour, e-mail: esmail\_hassanpour@yahoo.com

such as donor site morbidity, a difficult and long operation time and the chance of flap failure<sup>3</sup>. We present a case with a recurrent CPT and refracture which was treated by vascularized bone graft of ipsilateral fibula, for vascularized bone transferring. The purpose of this article is to present a new method for the treatment of CPT which potentially decreases the chance of refracture by transferring vascularized bone to the site of the disease.

### Case presentation

The patient was a 7 year old girl with congenital pseudoarthrosis of the tibia caused by neurofibromatosis. The patient had two operations before being referred to our hospital. The first operation was done at the age of 7 months. In that operation, only the bone graft was used for achieving union. Due to the nonunion, she had another operation 5 months later and the insertion of intramedullary rod and bone grafting were done. However, after few months, pain appeared at the site of the disease. Nonunion was documented in the radiological study. Due to the unfavorable results, her parents didn't agree to other treatment modalities. When the patient reached the age of 7, she was referred to our hospital with 40 degrees of valgus deformity of ankle and 30 degrees of anterior bowing of distal part of tibia which were persisted six years after her last operation. The patient had 6 cm limb length discrepancy (LLD) between the two legs. Due to failure in the previous operation, we decided to transfer the vascularized bone graft (figures 1 and 2).

### Surgical technique

The patient was put in the supine position with a pneumatic tourniquet which was applied proximally on the lower extremity. The knee was flexed 135 degrees, the hip was flexed 60 degrees, and the leg was internally rotated. A line was drawn from the fibular head to the lateral malleolus. The desired length of fibula was marked (10 cm) in the middle third of the fibula (figure 3). A curvilinear incision was then marked along the lateral border of the peroneal muscles. The skin

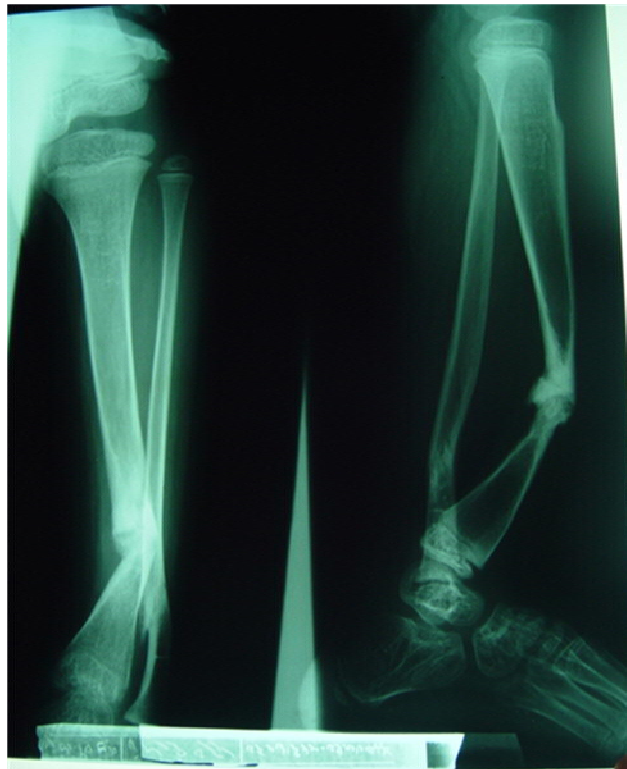incision was made extending through the crural fascia to the peroneal muscles. Then posterior intramuscular septum was separated from its attachment to the fibula along its posterior border. Through an extraperiosteal dissection, the peroneal muscles were separated from the fibula anterolaterally, beginning in proximal location and proceeding distally, leaving a 2 mm muscular cuff. The soleus muscle was separated proximally from the fibula posterolaterally and the lateral surface of the fibula was exposed. Then, dissection of the fibula continued anteriorly and posteriorly using an extraperiosteal dissection (1 cm cuff of flexor hallucis muscle with associated peroneal vessels was left attached to the fibula). At the proximal and distal limits of osteotomies, a malleable retractor was placed immediately adjacent to the fibula on the medial surface (periosteum cut 2 cm beyond the osteotomy sites). The peroneal vessels were identified at the distal osteotomy site and were ligated. The distal end of the fibula was then distracted laterally and posteriorly. The peroneal vessels were next traced to their origin from the posterior tibial vessels. The osseous segment which was only attached by its vascular pedicle was observed for the balanced perfusion after deflating the tourniquet. The antegrade flow pedicle of vascularized fibula graft was transferred in onlay fashion. Screws were used for the fixation of the grafted fibula. We also utilized osteosynthesis plate in the opposite side of the graft, and the defect of tibia was filled by iliac crest cancellous bone graft. Casts were used for 6 weeks as a postoperative immobilization. The progressive hypertrophy of the graft without resorption was demonstrated and the child was able to walk without an orthosis within 6 months.

### Results

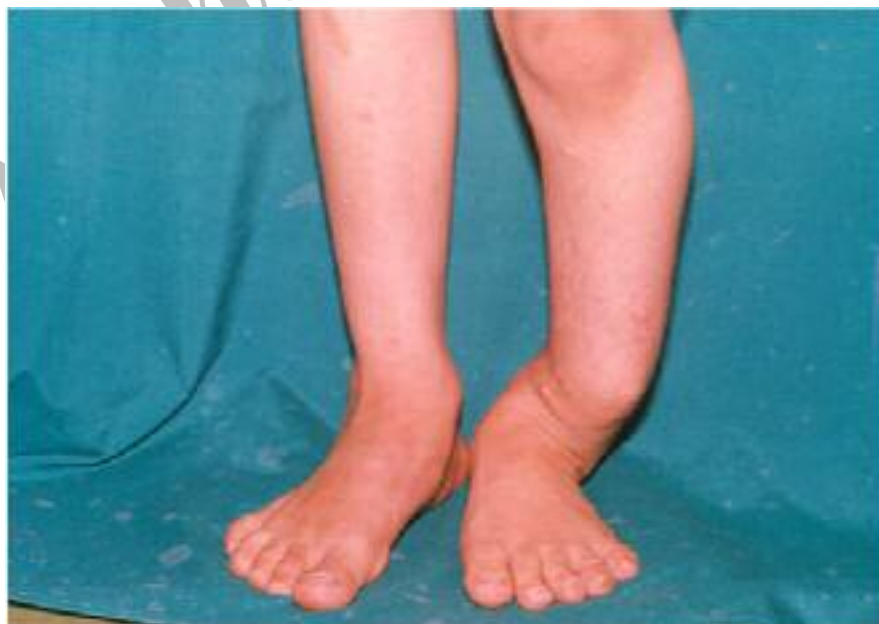Six months after the operation, the child was able to walk without orthosis. Radiological studies demonstrated the progressive hypertrophy of the graft without resorption. After 3 years, the patient was able to walk perfectly and there was no sign of recurrence at the site

of the primary disease. The patient had no pain at the CPT site. Therefore, an excellent clinical result was achieved. It means the patient can perform unrestricted activities and play sports.

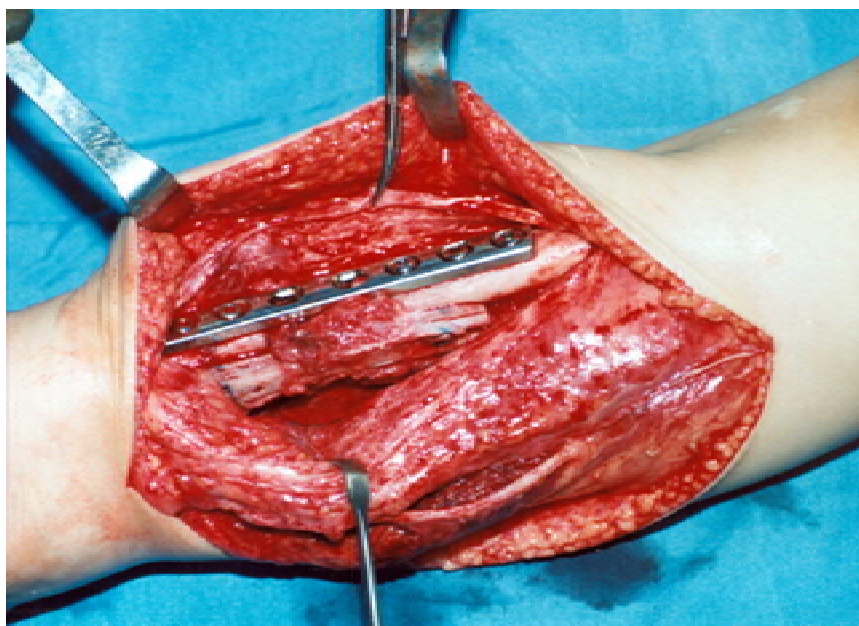
She also has no significant limb length discrepancy. The amount of valgus is less than 20 degrees. After 4 years of follow up, no sign of recurrence is evident (figures 4 and 5).



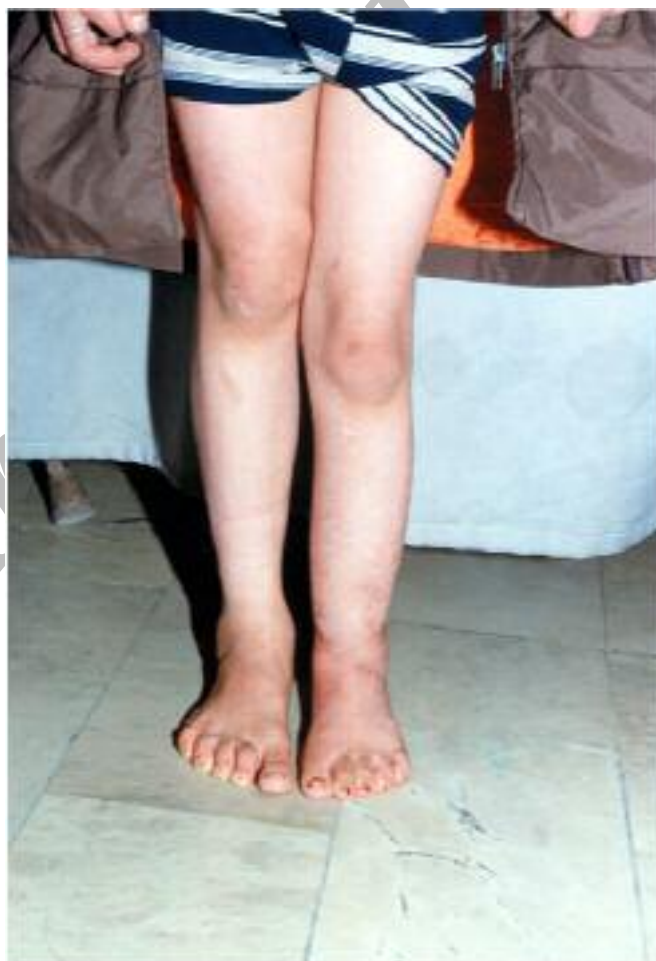**Figure 1.** Radiological study of congenital pseudoarthrosis of tibia in 7 years old girl.



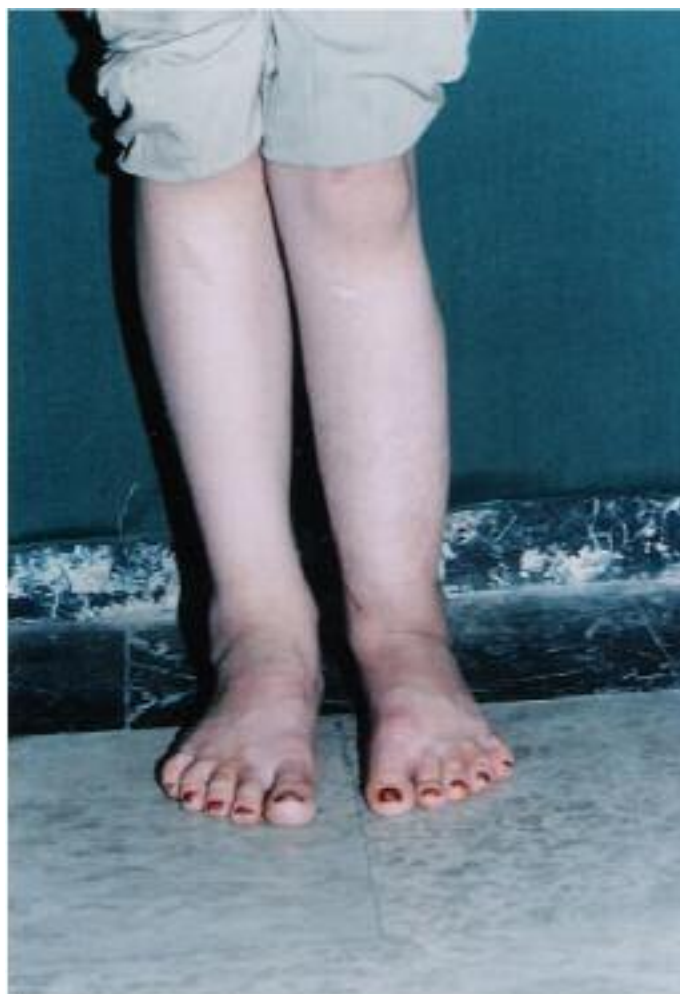**Figure 2.** Congenital pseudoarthrosis of tibia in 7 years old girl.



**Figure 3.** Insertion of vascularized graft of fibula.



**Figure 4.** No LLD is present after four years follow up.



**Figure 5.** No LLD is present after four years follow up.

## Discussion

The pathology of congenital pseudoarthrosis of the tibia is an enigma and its treatment is challenging. Even after achieving the union of the pseudoarthrosis, the patients may have a compromised function secondary to residual deformities<sup>2</sup>. Resection and reconstruction using a vascularized fibular graft is a viable alternative treatment for this disease. Although distal junctional nonunion and residual deformities are known complications that are difficult to cure<sup>6</sup>, our case achieved union of tibia completely. It is important to know that primary surgical treatment should be delayed till age 4-5 when the bone is wider and longer<sup>2</sup>. Residual LLD following a successful union is a ma-

jor problem in these cases. In our case, minimal LLD was remained. Many authors have noted that an unhealed fibular pseudoarthrosis can cause ankle valgus deformity. In this case ankle valgus was 20 degrees approximately. It must be remembered that an early attempt should be made to achieve the union of the tibia and fibula. The mentioned result may be reached by the vascularized fibular graft<sup>7</sup>. This method can be done by harvesting fibula from contra or ipsilateral part and its overall success rate is greater than other techniques. This method can be used regardless of the patient's age (it may also be applied for young children). By achieving union, this method allows early weight bearing.

## References

1. Andersen KS. **Congenital pseudarthrosis of the tibia and neurofibromatosis.** *Acta Orthop Scand* 1976; 47(1):108-111.
2. Inan M, El Rassi G, Riddle EC, Kumar SJ. **Residual deformities following successful initial bone union in congenital pseudoarthrosis of the tibia.** *J Pediatr Orthop* 2006; 26(3):393-399.
3. Coleman SS, Coleman DA. **Congenital pseudarthrosis of the tibia: treatment by transfer of the ipsilateral fibula with vascular pedicle.** *J Pediatr Orthop* 1994; 14(2):156-160.
4. Boero S, Catagni M, Donzelli O, Facchini R, Frediani PV. **Congenital pseudarthrosis of the tibia associated with neurofibromatosis-1: treatment with Ilizarov's device.** *J Pediatr Orthop* 1997; 17(5):675-684.
5. Heikkinen ES, Poyhonen MH, Kinnunen PK, Seppanen UI. **Congenital pseudarthrosis of the tibia. Treatment and outcome at skeletal maturity in 10 children.** *Acta Orthop Scand* 1999; 70(3):275-282.
6. Sulaiman AR, Nordin S, Faisham WI, Zulmi W, Halim AS. **Residual nonunion following vascularised fibular graft treatment for congenital pseudarthrosis of the tibia: a report of two cases.** *J Orthop Surg (Hong Kong)* 2006; 14(1):64-66.
7. Johnston CE. **Congenital pseudarthrosis of the tibia: results of technical variations in the charnley-williams procedure.** *J Bone Joint Surg Am* 2002; 84-A(10):1799-1810.

Archive of SID