

Case Report**Aggressive angiomyxoma of the vulva: dramatic response to gonadotropin-releasing hormone agonist therapy***Azar Danesh*, Mohammad Hossein Sanei*****Abstract**

Aggressive angiomyxoma is a rare soft tissue neoplasm that usually arises within the perineum. It often occurs as a vulvar mass and clinically simulates a Bartholin's gland cyst. Most patients are in the second or third decade of life, but some cases have also been reported in children. This is the report of a 21 year old woman with $4.5 \times 3 \times 1.5$ cm mass in right labia major. The patient underwent wide local excision surgical treatment. Histological examination showed high vascular myxoid tumor containing spindle cells. Immunohistochemical study of cells showed positive reaction to estrogen and progesterone and negative reaction to S100, SMA and desmin. Treatment with a gonadotropin-releasing hormone agonist was administered to deal with residual tumor and prevent local recurrence for 6 months.

KEY WORDS: Aggressive angiomyxoma, vulva, pregnancy, Gonadotropin releasing hormone agonist.

JRMS 2007; 12(4): 217-221

In 1983 Steeper and Rosai described aggressive angiomyxoma, a rare soft tissue tumor which tends to occur primarily on genital, perineal and pelvic organs in women of child-bearing age¹. However, it can occur in perimenopausal women, men and children. Instances have also been seen in the retroperitoneum, and scrotum². Aggressive angiomyxoma grows slowly but is locally invasive and relapses have been seen in 30-40% of cases³. To the best of our knowledge, four cases in pregnant women have been reported in literature and this is the fifth known case to occur during pregnancy^{2,4-6}.

Case report

The patient was a 21-year-old woman, gravida 1 para 1, who sought treatment at the Alzahra Hospital, Isfahan University of Medical Sciences. She had developed a vulvar mass after

her recent delivery. She had never been visited by a physician. She complained of asymmetric labia major which had started after menarche, also complained of dyspareunia after marriage and reported that it have been growing gradually especially during her pregnancy. In gynecologic examination labia major was asymmetric. Right side was enlarged and bulged in the inferior part with no color skin change. There was a firm non-circumscribed mass on manual examination. We considered a diagnosis of Bartholin's mass before operation. Under general anesthesia the patient underwent wide local excision of the right vulva. Complete resection of the tumor wasn't possible because it might have unwanted cosmetic and sexual side effect. Therefore, we prescribed adjuvant gonadotropin releasing hormone (GnRH) agonist (leuprolide acetate, 3.75 mg/monthly for six month) in this case. The tumor has not

*Associate Professor, Department of Obstetrics and Gynecology, Alzahra Hospital, Isfahan University of Medical Sciences, Isfahan, Iran. e-mail: mam_fd@yahoo.com (Corresponding Author)

**Assistance Professor, Department of Pathology, Alzahra Hospital, Isfahan University of Medical Sciences, Isfahan, Iran.

progressed after one year of follow up (figure 1). The resected tumor measured $4.5 \times 3 \times 1.5$ cm. The cut surface was soft, gray-pink in color and had a diffuse gelatinous appearance. Pathological evaluation (figure 2) revealed a background of loose collagenous myxoid in derma. There were small tumor cells that were either stellate or spindle shaped in the background of high vascular myxoid stroma. The nuclei were round-to-oval with bland chromatin. Mitotic activity was not observed in any of

the tumors. Small delicate wavy bands of collagen were identified throughout the tumorous background in the majority of the lesions. The immunohistochemical findings showed the tumor cells were negative for desmin, S100, SMA and focally positive for estrogen (figure 3) and progesterone (figure 4). Therefore, myxoid liposarcoma, sarcoma, botryoides, myxoid variant of malignant fibrous histiocytoma, nerve sheath myxoma were ruled out and aggressive angiomyxoma was reported.

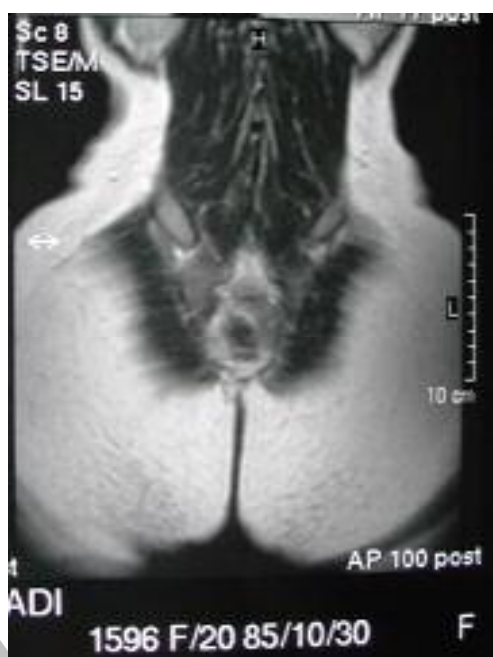


Figure 1. MRI revealed no progression.

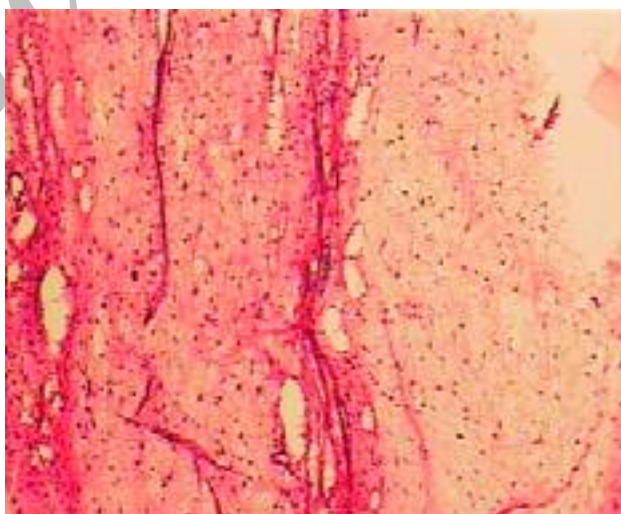


Figure 2. High vascular myxoid stroma contains spindle cells.

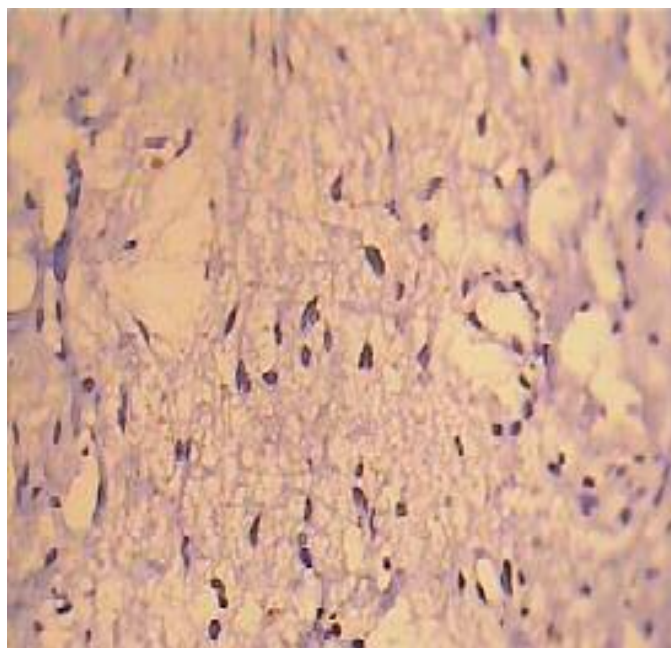


Figure 3. Some cells were positive for estrogen.

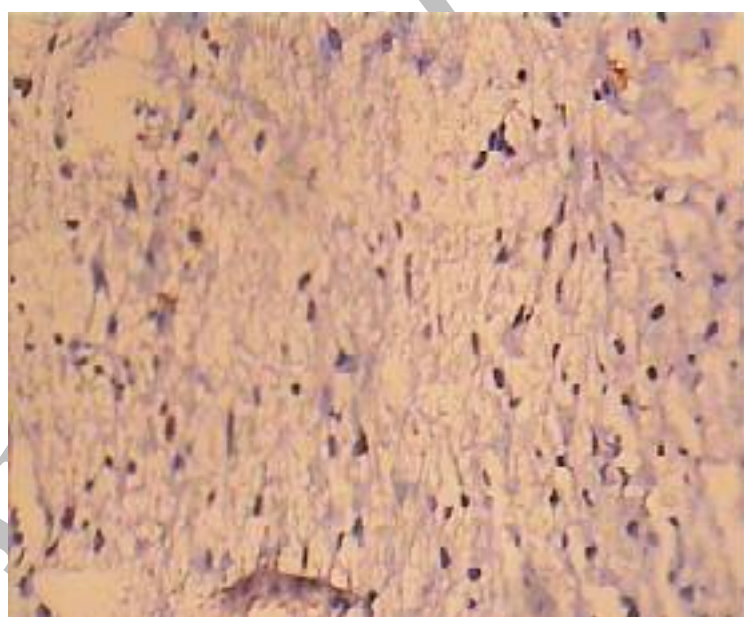


Figure 4. Some cells were positive for progesterone.

Color versions of figures are available for download at the journal homepage

Discussion

We report a rare case of aggressive angiomyxoma which demonstrated growth during recent pregnancy. More than 150 cases of aggressive angiomyxoma have been reported in literature but only four cases occurred during

pregnancy^{2,4-6}. The increased growth or recurrence during pregnancy suggests a relationship between this tumor with some hormones. Immunohistochemical study showed a positive reaction of some cells to estrogen and progesterone receptors. However, one of these cases

was both estrogen and progesterone positive and another case was just strongly progesterone positive but, in our case, both receptors were focally positive. Aggressive angiomyxoma is a rare soft tissue neoplasm which dominantly involves female genital tract³. Although tumor cells show myofibroblastic phenotype, the histogenesis of tumor is poorly known⁷. This tumor generally occurs as a large, slow growing, bulky mass, soft, partly circumscribed, polypoid mass or cyst-like lesion or ill defined swelling in the pelvic region with infiltrating margins^{8,9}. Angiomyxoma can mimic clinically Bartholin's cyst, labial cyst, polyp, Gartner's duct cyst, pedunculated soft tissue tumors or perineal herniation⁶. The size of the neoplasms varies from 5 to 23 cm¹⁰. The most important histological differential diagnosis are myxoma, myxoid liposarcoma, sarcoma, botryoides, myxoid variant of malignant fibrous histiocytoma, nerve sheath myxoma and other soft tissue tumors with secondary myxoid changes¹. Aggressive angiomyxoma grows slowly but is locally invasive and relapses have been seen in 30-40% of cases. Aggressive angiomyxoma can invade bladder, gastrointestinal tract, bones and even pulmonary metastasis has been reported. Therefore, preoperative evaluations including computer tomography (CT) scan, ultrasound, intravenous pyelogram (IVP), bone scan, barium enema, pelvic angiography should be considered to study the extent of the tumor¹⁰. Resection of the tumor with wide tumor-free margin is the

current choice treatment. However, it does not totally prevent a recurrence¹¹. Tumor has low mitotic activity, therefore it is unlikely that radiation therapy or chemotherapy will be useful as an adjunct to primary surgical treatment¹². Fishman et al described a case of a 37-year-old woman with a diagnosis of aggressive angiomyxoma who was weakly estrogen-positive and progesterone-negative, and relapsed during pregnancy¹³. Some authors suggested that complete resection in comparison with incomplete resection plus radiotherapy or arterial embolization doesn't cause any significant decrease of tumor recurrence¹⁴. GnRH analogs have been used in treatment of recurrent aggressive angiomyxoma to avoid further destructive surgery¹⁵. Thus, there may be a role for hormone antagonist, such as tamoxifen, raloxifene, and GnRH analogs¹⁶. In our experience GnRH agonist therapy can prevent tumor recurrence or progression after one year follow up.

Conclusions

Increased growth of the tumor during pregnancy suggests a relationship of this tumor and some hormones because immunohistochemical study showed a positive reaction of some cells for estrogen and progesterone receptor. Therefore, one should consider GnRH agonist in treatment of aggressive angiomyxoma not only in recurrence also in incomplete resection cases.

References

1. Steeper TA, Rosai J. **Aggressive angiomyxoma of the female pelvis and perineum. Report of nine cases of a distinctive type of gynecologic soft-tissue neoplasm.** *Am J Surg Pathol* 1983; 7(5):463-475.
2. Ribaldone R, Piantanida P, Surico D, Boldorini R, Colombo N, Surico N. **Aggressive angiomyxoma of the vulva.** *Gynecol Oncol* 2004; 95(3):724-728.
3. Nucci MR, Fletcher CD. **Vulvovaginal soft tissue tumours: update and review.** *Histopathology* 2000; 36(2):97-108.
4. Bagga R, Keepanasseril A, Suri V, Nijhawan R. **Aggressive angiomyxoma of the vulva in pregnancy: a case report and review of management options.** *MedGenMed* 2007; 9(1):16.
5. Smirniotis V, Kondi-Pafiti A, Theodoraki K, Kostopanagiotou G, Liapis A, Kourias E. **Aggressive angiomyxoma of the pelvis: a clinicopathologic study of a case.** *Clin Exp Obstet Gynecol* 1997; 24(4):209-211.

6. Wolf CA, Kurzeja R, Fietze E, Buscher U. **Aggressive angiomyxoma of the female perineum in pregnancy.** *Acta Obstet Gynecol Scand* 2003; 82(5):484-485.
7. Rabban JT, Dal CP, Oliva E. **HMG A2 rearrangement in a case of vulvar aggressive angiomyxoma.** *Int J Gynecol Pathol* 2006; 25(4):403-407.
8. Begin LR, Clement PB, Kirk ME, Jothy S, McCaughey WT, Ferenczy A. **Aggressive angiomyxoma of pelvic soft parts: a clinicopathologic study of nine cases.** *Hum Pathol* 1985; 16(6):621-628.
9. White J, Chan YF. **Aggressive angiomyxoma of the vulva in an 11-year-old girl.** *Pediatr Pathol* 1994; 14(1):27-37.
10. Cinel L, Taner D, Nabaei SM, Dogan M. **Aggressive angiomyxoma of the vagina. Report of a distinctive type gynecologic soft tissue neoplasm.** *Acta Obstet Gynecol Scand* 2000; 79(3):232-233.
11. Fetsch JF, Laskin WB, Lefkowitz M, Kindblom LG, Meis-Kindblom JM. **Aggressive angiomyxoma: a clinicopathologic study of 29 female patients.** *Cancer* 1996; 78(1):79-90.
12. Rotmensch EJ, Kasznica J, Hamid MA. **Immunohistochemical analysis of hormone receptors and proliferating cell nuclear antigen in aggressive angiomyxoma of the vulva.** *Int J Gynaecol Obstet* 1993; 41(2):171-179.
13. Fishman A, Otey LP, Poindexter AN, III, Shannon RL, Girtanner RE, Kaplan AL. **Aggressive angiomyxoma of the pelvis and perineum. A case report.** *J Reprod Med* 1995; 40(9):665-669.
14. Han-Geurts IJ, van Geel AN, van DL, Bakker Md, Eggermont AM, Verhoef C. **Aggressive angiomyxoma: multimodality treatments can avoid mutilating surgery.** *Eur J Surg Oncol* 2006; 32(10):1217-1221.
15. Fine BA, Munoz AK, Litz CE, Gershenson DM. **Primary medical management of recurrent aggressive angiomyxoma of the vulva with a gonadotropin-releasing hormone agonist.** *Gynecol Oncol* 2001; 81(1):120-122.
16. Abu JI, Bamford WM, Malin G, Brown L, Davies Q, Ireland D. **Aggressive angiomyxoma of the perineum.** *Int J Gynecol Cancer* 2005; 15(6):1097-1100.