

Case Report**A 40 years old woman with monolobar Caroli's syndrome treated
by left hepatic lobectomy**

*Hamid Tavakkoli**, *Abbas Tabatabaei***, *Amir Hosein Davarpanah Jazi****,
*Mahshid Haghighi*****, *Diana Taheri******, *Mahbobeh Tavakkoli******

Abstract

Caroli's disease (CD) is a rare congenital abnormality characterized by dilatation of intra hepatic bile ducts, which causes stone formation, recurrent cholangitis and higher risk for biliary malignancy. Association of this anomaly with congenital hepatic fibrosis is named Caroli's syndrome (CS). The monolobar involvement of CS is a very rare condition, curable by partial hepatectomy. We report a 40-year-old woman with recurrent epigastric pain without icterus with normal AST, ALT and alkaline phosphates for 5 years due to left lobe Caroli syndrome which was diagnosed by CT scan and MRCP. Then, the patient underwent successful operation (left hepatic resection). After 8 months follow up, she was symptom free. Because the presentation of unilobar CS may be as late as middle age, this congenital anomaly should be considered in differential diagnosis of patients with recurrent epigastric pain without icterus in this age group and MRCP is a useful diagnostic tool.

KEY WORDS: Caroli's disease, Caroli's syndrome, congenital hepatic fibrosis, magnetic resonance cholangiopancreatography.

JRMS 2007; 12(6): 320-325

Caroli's disease is characterized by multiple segmental cystic dilatations of the intrahepatic bile ducts and is associated with recurrent cholangitis and a relatively high rate of complicating intrahepatic malignant tumors¹. Caroli's disease is the less common form and is characterized by bile duct ectasia without other apparent hepatic abnormalities. The more common variant is Caroli's syndrome (CS), in which bile duct dilatation is associated with congenital hepatic fibrosis². Caroli's disease or syndrome is divided into two types, diffused and localized. The question of which type of Caroli's disease is more

frequently seen is controversial. The localized form which at most involves the entire left lobe of the liver is the most frequent form according to Lipsett et al³. There are about 150 published cases with Caroli's disease⁴ which less than 30 of them have had pure left lobe involvement⁵. The localized form is usually treated by partial hepatectomy if anatomically feasible. Clinical management of the diffuse form is very difficult because of frequent infectious complications of intrahepatic stones. Medical management includes the use of antibiotics for the treatment of abscesses, whereas surgical treatment usually consists of permanent

*Assistant Professor of Gastroenterology, Department of Gastroenterology, Alzahra Hospital, Isfahan University of Medical Sciences (IUMS), Isfahan, Iran. e-mail: h_tavakoli@med.mui.ac.ir (Corresponding Author)

**Associate Professor of Surgery, Department of Surgery, Alzahra Hospital, IUMS, Isfahan, Iran.

***Medical Student, Alzahra Hospital, IUMS, Isfahan, Iran.

****Associate Professor of Radiology, Department of Radiology, Alzahra Hospital, IUMS, Isfahan, Iran.

*****Assistant Professor of Pathology, Department of Pathology, Alzahra Hospital, IUMS, Isfahan, Iran.

*****Research Assistant, Poursina Hakim Research Institute, Isfahan, Iran.

external drainage of the biliary system. In extreme cases, hepatic transplantation may be considered ⁶⁻⁸. We report a middle age female with monolobar Caroli syndrome involving the left lobe of liver treated by left hepatectomy.

Case Report

A 40-year-old patient presented with recurrent epigastric pain with fever but without icterus, and pruritis. Severe abdominal pain with radiation to left upper quadrant almost always has forced her to be hospitalized and treated by hydration, antibiotics and analgesics. She mentioned such recurrent epigastric pains without jaundice since 5 years ago. At the beginning, attacks have been occurred every 4-5 months but progressively the intervals have shortened to 2 weeks in the last 3 months. She mentioned weight loss (2-3 kg), nausea, vomiting and constipation. Past medical history included anemia, joint pain and septic abortion. Physical examination revealed tenderness and mass in epigastria but, no lymphadenopathy or organomegaly. Because of recurrent epigastric pain, physical findings and anemia we decided to perform esophagogastroduodenoscopy (EGD) and abdominal sonography. Endoscopic evaluation showed antral gastropathy. Pathological study of D2 biopsy demonstrated intraepithelial lymphocytosis consistent with MARSH I classification. Abdominal ultrasound showed cystic dilatation of intrahepatic biliary ducts of left liver lobe with stone formation. Two weeks later, spiral computed tomography of abdomen revealed multiple dilations of biliary ducts of left lobe of liver, normal right lobe and common bile duct (figure 1). Lab findings included WBC: 4930, Hb: 11.2 g/dl, MCV: 74, MCH: 21.6, platelet: 255,000, PTT: 35 seconds, PT: 13 seconds, INR: 1.2, ALT: 17 U/l, AST: 22 U/l, alkaline phosphatase: 147 U/l (normal for females: up to 306), BUN: 13 mg/dl, Cr: 0.9 mg/dl, bilirubin total: 0.5 mg/dl, bilirubin direct: 0.2 mg/dl, gamma glutamyl transferase: 113 IU/l (normal up to 50), negative anti-gliadin antibodies (IgG & IgA) as well as anti-endomysial antibodies. In Decem-

ber 2006 MRCP revealed Caroli's disease with pure left lobe involvement (figure 2). Because of unilobar presentation of this disease we referred her for surgical treatment. Left hepatic lobectomy and cholecystectomy successfully were done (figure 3) and patient was discharged from hospital with mild epigastric and RUQ pain after 9 days. Pathologic examination of liver showed increased fibrous connective tissue in the periportal area and irregular proliferation of biliary ductules compatible with Caroli disease with congenital hepatic fibrosis (figure 4). Four weeks after surgery, T-tube cholangiography was done and T-tube was withdrawn. One day later, she was admitted again in hospital because of abdominal pain, fever and elevated transaminases (less than 2 times) as well as alkaline phosphatase (less than 3 times) with normal bilirubin and serum amylase. Initial therapy included hydration, NPO and antibiotics. These treatments led to dramatic remission of pain as well as fever. Finally, after one week she became symptom free and was discharged with oral antibiotics. During a follow-up period of 8 months, there was no recurrence or any complication.

Discussion

Diagnosis of Caroli disease is based on clinical features and imaging studies. The normal course in Caroli's disease consists of suppurative cholangitis, septicemia with gram-negative organisms and intrahepatic abscesses. The disease must be recognized before these serious complications arise. The hepatobiliary imaging procedures should now allow an early diagnosis and therefore, a better therapeutic approach ^{9,10}. Diagnosis of this syndrome because of its rarity is often delayed. Gillet et al in 1999 reported that the mean interval between the first symptoms and diagnosis is approximately 12.5 years ¹¹ (compared with 5 years in present report).

Fibropolycystic liver disease encompasses a spectrum of related lesions of the liver and biliary tract that are caused by abnormal embryologic development of the ductal plates. These lesions include congenital hepatic fibrosis,

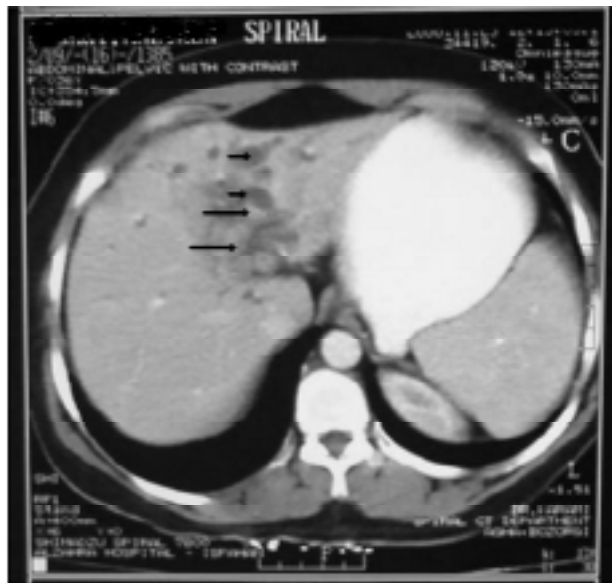

Figure 1: Spiral CT scan of liver with oral and injected contrast. Bile duct ectasia in left liver lobe (short black arrows) and stones in ducts (long thin black arrows).

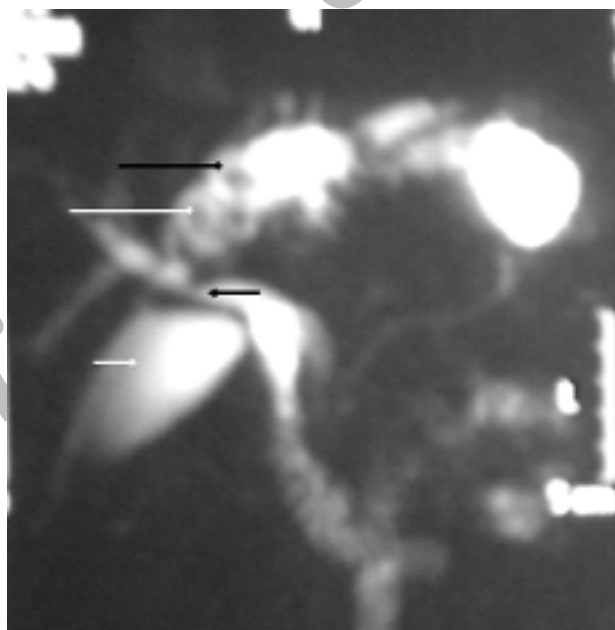


Figure 2: MRCP-multiple stones (long white arrow) in left liver lobe dilated bile duct (long black arrow), gall bladder (short white arrow), and common duct (short black arrow).

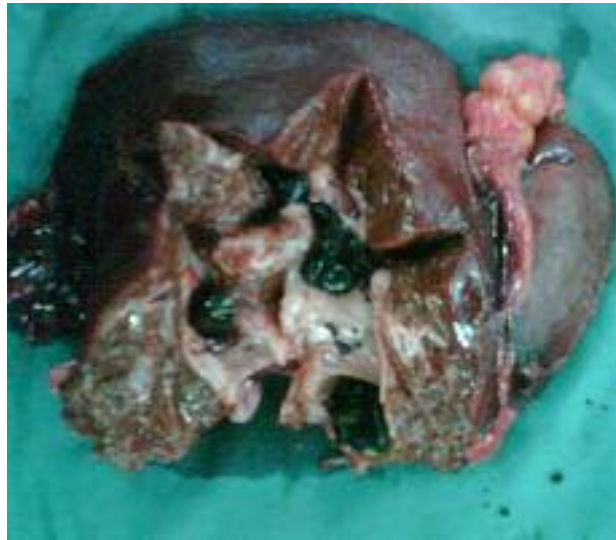

Figure 3: Resected left liver lobe. Intrahepatic bile duct cysts with stone formation are visible.

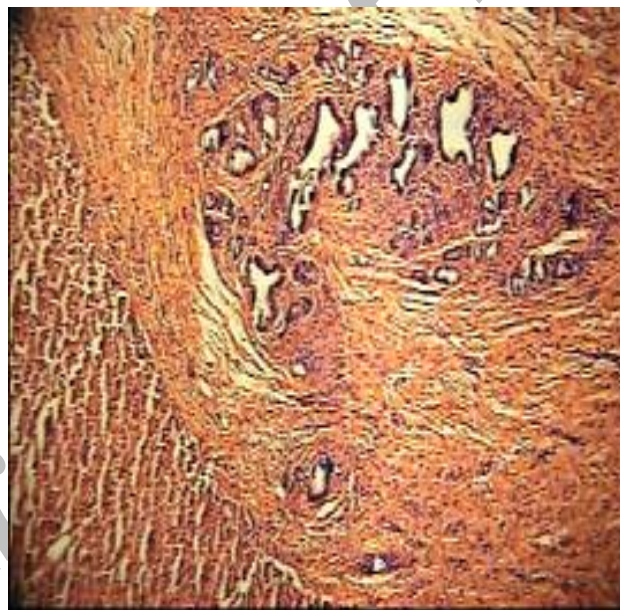


Figure 4: Increased amount of fibrous connective tissue in the periportal area with irregular proliferation of biliary ductules (H & E stain, 100x, Caroli's syndrome / congenital hepatic fibrosis)

biliary hamartomas, autosomal dominant polycystic disease, choledochal cysts and Caroli syndrome. CT and MR imaging features are essential in detecting and differentiating between various fibropolycystic liver diseases¹². Peribiliary cysts, otherwise known as cystic

dilatation of the peribiliary glands, should be considered in differential diagnosis¹³. It has been shown that magnetic resonance cholangiopancreatography (MRCP) is an appropriate diagnostic tool and equivalent to endoscopic retrograde cholangiopancreatography

(ERCP) in detecting and defining the morphologic characteristics of congenital cystic lesions of the bile duct¹⁴ and in detecting an anomalous pancreaticobiliary junction (APBJ). The sensitivity and specificity of MRCP are 82% and 100%, respectively¹⁵. MRCP has advantageous role in early detection of CS. MRCP has the capability to evaluate the entire biliary tree. MR imaging findings were sufficient to confirm the diagnosis and direct cholangiography should be reserved for confirming doubtful cases. Moreover, MR imaging provided information about the severity, location and extent of liver involvement. In addition, it is noninvasive and has a low complication rate and high spatial resolution^{14,16-18}. It is very important to demonstrate that CD or CS is localized or diffuse because the treatments of these conditions are obviously different. Localized forms, which at the most, involve the left lobe of the liver, or the right lobe of the liver, are curable by surgery. They should be treated by left or right hepatic lobectomy with associated treatment of any problem affecting the common duct. Removal of calculi and sphincterotomy when calculi have migrated into the extrahepatic bile ducts and treatment of ectasia of the hepatic common bile ducts when this is associated with the congenital malformations of the intrahepatic bile ducts are indicated. The best treatment of those with diffused type is liver transplantation¹⁹. Although gradual regression of the cysts was reported in asymptomatic infant with localized CD, this disease in older children and adults often is associated with recurrent cholangitis and cirrhosis²⁰. Early

treatment protects the patient from complications, which include calculus formation, cholangitis, abscess and cholangiocarcinoma⁸. Except recurrent bacterial cholangitis, CS causes another life threatening complication. Cholangiocarcinoma is the commonest malignancy in patient with CD. According to reports of other studies, the incidence of cholangiocarcinoma among patients with CD could be as high as 37.5% (6%-10% in the majority of the reports)^{19,21-23}. Cholangiocarcinoma has also been reported in a patient with monolobar Caroli's disease²⁴. Liver resection eliminates the potential for cholangiocarcinoma^{25,26}. In summery, the localized type of Caroli's syndrome is not frequent⁵. Review of previous published cases revealed that CS often causes diffused biliary dilatation and fibrosis. In the present report, a rare clinical case of unilobar CS confined to the left lobe of liver was described which had not shown elevated transaminases as well as icterus. The only abnormal liver test in our patient was elevated gamma glutamyl transferase.

Conclusions

Although Caroli's disease is a congenital abnormality but its presentation may occur as late as adulthood or middle age. Therefore, Caroli disease should be considered in differential diagnosis of patients with recurrent epigastric and/or right upper quadrant pain without jaundice in this age group. MRCP is a useful tool for its diagnosis.

References

1. Takatsuki M, Uemoto S, Inomata Y, Egawa H, Kiuchi T, Hayashi M et al. **Living-donor liver transplantation for Caroli's disease with intrahepatic adenocarcinoma.** *J Hepatobiliary Pancreat Surg* 2001; 8(3):284-286.
2. Harjai MM, Bal RK. **Caroli syndrome.** *Pediatr Surg Int* 2000; 16(5-6):431-432.
3. Lipsett PA, Pitt HA. **Surgical treatment of choledochal cysts.** *J Hepatobiliary Pancreat Surg* 2003; 10(5):352-359.
4. Madjov R, Chervenkov P, Madjova V, Balev B. **Caroli's disease. Report of 5 cases and review of literature.** *Hepatogastroenterology* 2005; 52(62):606-609.
5. Yilmaz S, Kirimlioglu H, Kirimlioglu V, Isik B, Coban S, Yildirim B et al. **Partial hepatectomy is curative for the localized type of Caroli's disease: a case report and review of the literature.** *Surgeon* 2006; 4(2):101-105.
6. Weyant MJ, Maluccio MA, Bertagnolli MM, Daly JM. **Choledochal cysts in adults: a report of two cases and review of the literature.** *Am J Gastroenterol* 1998; 93(12):2580-2583.

7. Dagli U, Atalay F, Sasmaz N, Bostanoglu S, Temucin G, Sahin B. **Caroli's disease: 1977-1995 experiences.** *Eur J Gastroenterol Hepatol* 1998; 10(2):109-112.
8. Merono-Cabajosa EA, Celdran-Uriarte A, Moreno-Caparros A, Solera-Arroyo JC, Marijuan-Martin JL. **Caroli's disease: study of six cases, including one with epithelial dysplasia.** *Int Surg* 1993; 78(1):46-49.
9. Keramidas DC, Kapouleas GP, Sakellaris G. **Isolated Caroli's disease presenting as an exophytic mass in the liver.** *Pediatr Surg Int* 1998; 13(2-3):177-179.
10. Sans M, Rimola A, Navasa M, Grande L, Garcia-Valdecasas JC, Andreu H et al. **Liver transplantation in patients with Caroli's disease and recurrent cholangitis.** *Transpl Int* 1997; 10(3):241-244.
11. Gillet M, Favre S, Fontolliet C, Halkic N, Mantion G, Heyd B. **[Monolobar Caroli's disease. Apropos of 12 cases].** *Chirurgie* 1999; 124(1):13-18.
12. Brancatelli G, Federle MP, Vilgrain V, Vullierme MP, Marin D, Lagalla R. **Fibropolycystic liver disease: CT and MR imaging findings.** *Radiographics* 2005; 25(3):659-670.
13. Fusai G, Tucker O, Nik Sulaiman NM, Karani J, Rela M, Portmann B. **Peribiliary cysts can mimic Caroli's disease: a case report.** *Int J Surg Pathol* 2005; 13(4):379-382.
14. Park DH, Kim MH, Lee SK, Lee SS, Choi JS, Lee YS et al. **Can MRCP replace the diagnostic role of ERCP for patients with choledochal cysts?** *Gastrointest Endosc* 2005; 62(3):360-366.
15. Zhong L, Xiao SD, Stoker J, Nj TG. **Magnetic resonance cholangiopancreatography.** *Chin J Dig Dis* 2004; 5(4):139-148.
16. Govil S, Justus A, Korah I, Perakath A, Zachariah N, Sen S. **Choledochal cysts: evaluation with MR cholangiography.** *Abdom Imaging* 1998; 23(6):616-619.
17. Guy F, Cognet F, Dransart M, Cercueil JP, Conciatori L, Krause D. **Caroli's disease: magnetic resonance imaging features.** *Eur Radiol* 2002; 12(11):2730-2736.
18. Hussain SZ, Bloom DA, Tolia V. **Caroli's disease diagnosed in a child by MRCP.** *Clin Imaging* 2000; 24(5):289-291.
19. Ammori BJ, Jenkins BL, Lim PC, Prasad KR, Pollard SG, Lodge JP. **Surgical strategy for cystic diseases of the liver in a western hepatobiliary center.** *World J Surg* 2002; 26(4):462-469.
20. Bratu I, Laberge JM, Khalife S, Sinsky A. **Regression of antenatally diagnosed localized Caroli's disease.** *J Pediatr Surg* 2000; 35(9):1390-1393.
21. Balsells J, Margarit C, Murio E, Lazaro JL, Charco R, Vidal MT et al. **Adenocarcinoma in Caroli's disease treated by liver transplantation.** *HPB Surg* 1993; 7(1):81-86.
22. Kassahun WT, Kahn T, Wittekind C, Mossner J, Caca K, Hauss J et al. **Caroli's disease: liver resection and liver transplantation. Experience in 33 patients.** *Surgery* 2005; 138(5):888-898.
23. Levy AD, Rohrmann CA, Jr., Murakata LA, Loneragan GJ. **Caroli's disease: radiologic spectrum with pathologic correlation.** *AJR Am J Roentgenol* 2002; 179(4):1053-1057.
24. Abdalla EK, Forsmark CE, Lauwers GY, Vauthey JN. **Monolobar Caroli's Disease and cholangiocarcinoma.** *HPB Surg* 1999; 11(4):271-276.
25. Giovanardi RO. **Monolobar Caroli's disease in an adult. Case report.** *Hepatogastroenterology* 2003; 50(54):2185-2187.
26. Knoop M, Keck H, Langrehr JM, Peter FJ, Ferslev B, Neuhaus P. **[Therapy of unilobar Caroli syndrome by liver resection].** *Chirurg* 1994; 65(10):861-866.