

Case Report**Idiopathic thrombocytopenic purpura in women with breast cancer**

*Mozhgan Alam Samimi<sup>a</sup>, Nooshin Mirkheshti<sup>\*,b</sup>,  
Mitra Heidarpour<sup>c</sup>, Mozhgan Abdollahi<sup>d</sup>*

**Abstract**

The association of solid tumors with idiopathic thrombocytopenic purpura (ITP) is rare. However, there have been some case reports indicating an association between breast cancer and ITP. In this article four patients with breast cancer and ITP are mentioned. The diagnosis of breast cancer was based on the results of biopsy or surgical sample. The ITP diagnosis criteria were 1) exclusion of drug induced thrombocytopenia, 2) platelet count less than  $140 \times 10^9 /l$  with normal or increased number of megakaryocytes on bone marrow samples, and 3) absence of splenomegaly. In this case report an association of breast cancer and ITP is shown.

**KEYWORDS:** Purpura, Thrombocytopenic, Idiopathic, Breast Neoplasms.

IRMS 2010; 15(6): 359-363

**T**hrombocytopenia is one of the disorders that has been observed in different cancers and some mechanisms has been supposed as a reason of this disorder including tumor bone marrow infiltration, chemotherapy/radiotherapy induced hypoplasia, disseminated intravascular coagulation<sup>1</sup> or thrombotic thrombocytopenic purpura (TTP).<sup>2</sup>

TTP<sup>3</sup> and ITP<sup>4,5</sup> have been described in patients with malignant diseases. For example, the association between ITP and lymphoid neoplasms, has been observed in some studies.<sup>6,7</sup> However, regardless lymphoid neoplasms, concomitant solid tumors and ITP have been reported in a limited number of studies. Most of these observations are relevant in breast cancer. Searching to find a relationship between ITP and breast cancer has been raised in recent years,<sup>8</sup> because such relationship can be considered as a predictive or prognostic value in breast cancer.

In this article, 4 cases of patients with breast cancer and ITP treated in the Department of

Medical Oncology of the Sayyed Al-Shohada hospital are reported. Clinical and laboratory characteristics of the two diseases have been reported in this article.

**Case Report**

All patients registered to treat for breast cancer at the Sayyed Al-Shohada hospital between 2005 and 2007. The diagnosis of breast cancer was confirmed by biopsy or surgical sample. Tumor size, axillary lymph node involvement, histologic type and hormonal receptor status were determined for all patients. Clinical examination, blood count, liver function tests, chest radiograph, mammogram, liver ultrasound or computed tomography studies, and bone marrow biopsy were conducted for each patient. According to the study done by Pefault et al,<sup>8</sup> the ITP diagnosis criteria were: 1) exclusion of drug induced thrombocytopenia, 2) platelet count less than  $140 \times 10^9 /l$  with normal or increased number of megakaryocytes on bone marrow samples, and 3) absence

<sup>a</sup> Assistant Professor of Hematology, Sayyed Al-Shohada Hospital, Isfahan University of Medical Sciences, Isfahan, Iran.

<sup>b</sup> Research Assistant, East Sage Investigative Corporation, Isfahan Science and Technology Town, Isfahan, Iran.

<sup>c</sup> Assistant Professor of Pathology, Pathology Department, Al-Zahra Hospital, Isfahan University of Medical Sciences, Isfahan, Iran.

<sup>d</sup> General Practitioner, Sayyed Al-Shohada Hospital, Isfahan University of Medical Sciences, Isfahan, Iran.

\* Corresponding Author

E-mail: nooshinmirkheshti@gmail.com

of splenomegaly. The antiplatelet antibody was not considered to be an absolute diagnostic criterion.<sup>8,9</sup>

In all patients, there was no history of prior blood transfusions, recent medications, or human immunodeficiency virus risk factors. Pertinent negative findings on physical examination included no evidence of lymphadenopathy, splenomegaly, ecchymoses, or petechiae.

### Case 1

A 73 year-old woman presented with a lump in her left breast underneath the nipple. An excisional biopsy revealed invasive ductal carcinoma grade III (Figure 1). Estrogen and progesterone receptors were positive.

At presentation complete blood count showed a marked thrombocytopenia without any evidence of a leukoerythroblastic reaction; the white blood cell (WBC) count and hemoglobin level were normal (hemoglobin: 13 g/dl, WBC:  $5 \times 10^9$  /l, platelet count:  $70 \times 10^9$  /l). A prior complete blood count showed a hemoglobin level of 14 g/dl, WBC  $55 \times 10^9$  /l, and platelet count of  $200 \times 10^9$  /l.

Laboratory workup included a negative anti-nuclear antibody, and no evidence of disseminated intravascular coagulopathy. Bone marrow biopsy was normal, with a normal number of megakaryocytes; no dysplastic changes were noted.

Adjuvant chemotherapy of this patient

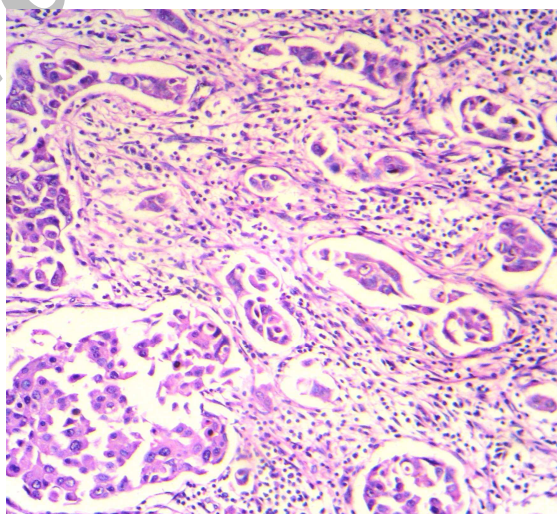
included: 4 courses of cyclophosphamide and adriamycin and 4 courses of taxol. A clinical diagnosis of idiopathic thrombocytopenic purpura (ITP) was made after six months of last chemotherapy administration. No therapy began regarding the platelet count greater than  $50 \times 10^9$  /l. In 3-year follow up, the platelet count remained at the same level. There was no evidence of recurrence of cancer.

### Case 2

A 54 year-old woman presented with a lump in her right breast underneath the nipple. An excisional biopsy revealed inflammatory lobular carcinoma. Estrogen receptors were negative and progesterone receptors were positive.

Twelve months after the chemotherapy for relapse, complete blood count showed a mild to moderate thrombocytopenia without any evidence of a leukoerythroblastic reaction; the white blood cell (WBC) count and hemoglobin level were normal and platelet count was  $90 \times 10^9$  /l. A prior complete blood count showed a platelet count of  $170 \times 10^9$  /l.

The adjuvant chemotherapy used in this patient included: 4 courses of cyclophosphamide and adriamycin and 4 courses of taxol. It must be mentioned that there was no history of leukoerythroblastic reaction by previous chemotherapy. The chemotherapy regimen was the same in both times (the primary tumor and in its relapse).



**Figure 1.** Histological findings of the surgical specimen of the left breast tumor show invasive ductal carcinoma (hematoxylin-eosin stain, 100 x)

Laboratory workup included a negative anti-nuclear antibody, and no evidence of disseminated intravascular coagulopathy. The patient had a positive serum platelet antibody reacting against glycoprotein IIb/IIIa. Bone marrow biopsy was normal, with a normal number of megakaryocytes; no dysplastic changes were noted.

A clinical diagnosis of idiopathic thrombocytopenic purpura (ITP) was made. No therapy began regarding the platelet count greater than  $50 \times 10^9 /l$ . In 3-year follow up, the platelet count remained at the same level.

### Case 3

A 41 year-old woman presented with a lump in the lateral upper quadrant of her left breast. An excisional biopsy revealed in situ papillary carcinoma. Estrogen receptor was negative and progesterone receptor were positive.

A complete blood count while she was on tamoxifen for three years showed thrombocytopenia without any evidence of a leukoerythroblastic reaction; the white blood cell (WBC) count and hemoglobin level were normal (hemoglobin of 12.5 g/dl, WBC  $6 \times 10^9 /l$ , and platelet count of  $54 \times 10^9 /l$ ). A prior complete blood count showed a hemoglobin level of 13 g/dl, WBC  $5 \times 10^9 /l$ , and platelet count of  $300 \times 10^9 /l$ . There was no history of prior blood transfusions, and recent medications other than tamoxifen.

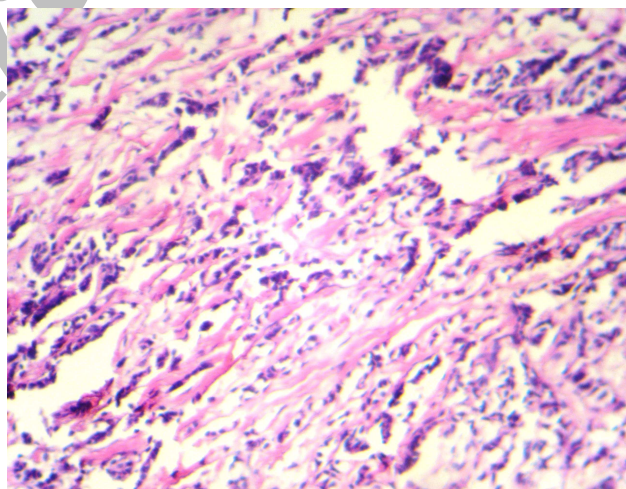
Laboratory workup included a negative anti-nuclear antibody, and no evidence of disseminated intravascular coagulopathy. The patient had a positive serum platelet antibody reacting against glycoprotein IIb/IIIa. Bone marrow biopsy was normal, with a normal number of megakaryocytes; no dysplastic changes were noted.

A clinical diagnosis of idiopathic thrombocytopenic purpura (ITP) was made. No therapy began regarding the platelet count greater than  $50 \times 10^9 /l$ . In 3-year follow up, the platelet count remained at the same level.

### Case 4

A 40 year-old woman presented with a lump in her left breast underneath the nipple. An excisional biopsy revealed invasive lobular carcinoma (Figure 2). Estrogen and progesterone receptors were positive.

Three months after the end of TAC (taxotere and adriamycine and cyclophosphamide) regimen chemotherapy complete blood count showed a marked thrombocytopenia without any evidence of a leukoerythroblastic reaction; the white blood cell (WBC) count and hemoglobin level were normal (hemoglobin of 13 g/dl, WBC of  $5 \times 10^9 /l$ , and platelet count of  $25 \times 10^9 /l$ ). A prior complete blood count showed a hemoglobin level of 13.5 g/dl, WBC  $7 \times 10^9 /l$ , and platelet count of  $150 \times 10^9 /l$ .



**Figure 2.** Histological findings of the surgical specimen of the left breast tumor show invasive lobular carcinoma (hematoxylin-eosin stain, 100 x)

Laboratory workup included a negative anti-nuclear antibody, and no evidence of disseminated intravascular coagulopathy. The patient had a positive serum platelet antibody reacting against glycoprotein IIb/IIIa. Bone marrow biopsy was normal, with a normal number of megakaryocytes; no dysplastic changes were noted.

A clinical diagnosis of idiopathic thrombocytopenic purpura (ITP) was made. A regimen of 60 mg of prednisone daily was begun. Follow-up complete blood counts 2 weeks later showed platelet count of  $160 \times 10^9 /l$ . Prednisolone continued and tapered after about 3 months. Platelet count became normal after using prednisolone.

### Discussion

In this article, 4 cases with ITP and breast cancer that were diagnosed and treated at the Sayyed Al-Shohada hospital were described. While ITP is still one of the most common autoimmune disorders, its relationship with solid tumors has not certainly been confirmed by conducted researches. Similarly, ITP has been reported in a small number of patients with breast cancers<sup>4,10-14</sup> and the study done by Peffault de Latour et al in 2004 is the largest series reported in the literature, that includes 10 patients with ITP and breast cancer.<sup>8</sup>

In the current study 4 patients with 4 different types of breast cancer and positive hormonal receptor status were presented. Considering this and all previous publications, positive hormonal receptor status (estrogen and/or progesterone receptors), especially progester-

one receptors, appeared to be more frequently associated with ITP. Despite some other publications, the current patients did not present a long time interval between the two diseases.<sup>8</sup> Few reports have suggested that thrombocytopenia occurs in the case of breast cancer progression and particularly bone metastases<sup>10,12</sup>; but in the present study, no poor outcome was observed when breast cancer is associated with ITP. So, more aggressive therapeutic strategy for these patients that is suggested in some articles does not seem necessary.

The relationship between ITP and breast cancer raises the question concerning the mechanisms involved in this association. In solid tumors, thrombocytopenia is known to be caused by bone marrow hypoplasia secondary to chemotherapy, bone marrow replacement by tumor, or platelet destruction caused by tumor-intrinsic factors activating the coagulation cascade.<sup>12</sup> Horváth et al reported the presence of circulating immune complex in 62% patients with breast cancer.<sup>15</sup> In addition, it is mentioned in some studies, all cases with ITP and breast cancer had stage IV breast cancer and this might suggest that a high tumor burden is required to produce an immune response resulting in platelet destruction. But regarding the lower stages of breast cancer that is reported in some other studies, like the present one, this mechanism can't be certainly involved.

The underlying mechanism for the development of ITP in breast cancer is unclear and further studies are needed to understand this exceptional but relevant association.

### Conflict of Interests

Authors have no conflict of interests.

### Authors' Contributions

MAS, MA and NM gathered patients' information and followed up them. MH was responsible for pathologic assessments of the samples. All authors have contributed in writing of the article. All authors have read and approved the content of the manuscript.

## References

1. Slichter SJ, Harker LA. Hemostasis in malignancy. *Ann N Y Acad Sci* 1974;230:252-61.
2. Antman KH, Skarin AT, Mayer RJ, Hargreaves HK, Canellos GP. Microangiopathic hemolytic anemia and cancer: a review. *Medicine (Baltimore)* 1979;58(5):377-84.
3. Tsai HM, Lian EC. Antibodies to von Willebrand factor-cleaving protease in acute thrombotic thrombocytopenic purpura. *N Engl J Med* 1998;339(22):1585-94.
4. Schwartz KA, Slichter SJ, Harker LA. Immune-mediated platelet destruction and thrombocytopenia in patients with solid tumors. *Br J Haematol* 1982;51(1):17-24.
5. Kim HD, Boggs DR. A syndrome resembling idiopathic thrombocytopenia purpura in 10 patients with diverse forms of cancer. *Am J Med* 1979;67(3):371-7.
6. Kaden BR, Rosse WF, Hauch TW. Immune thrombocytopenia in lymphoproliferative diseases. *Blood* 1979;53(4):545-51.
7. Fink K, Al-Mondhiry H. Idiopathic thrombocytopenic purpura in lymphoma. *Cancer* 1976;37(4):1999-2004.
8. Peffault de Latour R, Des Guetz G, Laurence V, Palangié T, Pierga JY, Diéras V, et al. Breast cancer associated with idiopathic thrombocytopenic purpura: a single center series of 10 cases. *Am J Clin Oncol* 2004;27(4):333-6.
9. Nonami Y, Yamashiro T, Yamamoto A, Kume M, Hisa N, Yoshida S, et al. Double lung cancer combined with idiopathic thrombocytopenic purpura. A case report. *J Cardiovasc Surg (Torino)* 1999;40(6):889-092.
10. Zucker MB, Ley AB, Borrelli J, Mayer K, Firmat J. Thrombocytopenia with a circulating platelet agglutinin, platelet lysis and clot retraction inhibitor. *Blood* 1959;14(2):148-61.
11. Wahid FS, Fun LC, Keng CS, Ismail F. Breast carcinoma presenting as immune thrombocytopenic purpura. *Int J Hematol* 2001;73(3):399-400.
12. Porrata LF, Alberts S, Hook C, Hanson CA. Idiopathic thrombocytopenic purpura associated with breast cancer: a case report and review of the current literature. *Am J Clin Oncol* 1999;22(4):411-3.
13. Igarashi T, Itoh K, Fujii H, Ohtsu T, Minami H, Sasaki Y, et al. Successful treatment by radiation and hormone therapy of isolated local recurrence of breast cancer 24 years after mastectomy accompanied by immune thrombocytopenia: a case report. *Jpn J Clin Oncol* 1998;28(4):270-5.
14. Cummings OW, Mazur MT. Breast carcinoma diffusely metastatic to the spleen. A report of two cases presenting as idiopathic thrombocytopenic purpura. *Am J Clin Pathol* 1992;97(4):484-9.
15. Horváth M, Fekete B, Rahóty P. Investigation of circulating immune complexes in patients with breast cancer. *Oncology* 1982;39(1):20-2.