

Case Report**Intracranial foreign body granuloma simulating brain tumor: a case report***Hamid Reza Saeidiborojeni^a, Taravat Fakheri^{*b}, Babak Iizadi^c***Abstract**

Intracranial foreign body granulomas are rarely reported. Clinical symptoms caused by foreign body granulomas can be noticed from months to many years after surgical procedure. The most common reported etiology is suture material. A 45-year-old woman was presented with grand mal epilepsy. She was operated for brain tumor 19 years ago. In CT scan, a round radio-dense mass resembling a tumor at anterior fossa was seen. She underwent craniotomy and resected a granuloma with cotton fibers surrounded by yellow capsule without residual or recurrent tumor. Granuloma can mimic intracranial meningioma and special attention should be paid not to leave cotton pledgets during operations.

KEYWORDS: Brain Tumor, Granuloma, Foreign-Body, Meningioma, Craniotomy.

JRMS 2011; 16(3): 358-360

Granulomatous reaction, a specific type of chronic inflammation, is characterized by aggregation of modified macrophages and stimulated by a variety of infectious and non infectious agents. Tuberculosis, sarcoidosis, and reaction to foreign body materials are the most common etiologies reported. Inflammatory pseudo tumor is a kind of foreign body reaction due to nonabsorbable cotton matrix (i.e. retained surgical sponge) left behind unintentionally during abdominal or pelvic operations. These cases have medico legal consequences. However, granulomatous foreign body reactions are rarely encountered in neurosurgical operations; and they are commonly due to haemostatic agents deliberately used during craniotomies.¹

The cotton sheet is well documented as a cause of granuloma in the literature.² Also, chemical haemostatic materials such as cotton pads are routinely used in neurosurgical operations to aid intraoperative hemeostasis. However, it can cause a foreign body reaction,³ which may produce clinical symptoms and

radiologic apparent mass lesion.⁴

Case Report

A 49-year-old woman was admitted with sign of acute onset tonic clonic grand mal epilepsy and seizure. She had a throbbing frontal headache resistant to analgesics and intractable vomiting and blurred vision since three months ago. Also, she had a positive medical history of craniotomy for removing brain tumor when she was 30 years old.

The complaint of the patient 19 years ago was also epilepsy, which was relieved by operation and anticonvulsant therapy (carbamazepin, 200 mg, TDS) for 11 years. Only the report of first CT scan was accessible, which said: "A right frontal neopalastic tumofaction with severe peri lesion edema."

Pathologic Report: Meningioma (Meningotheliosis Type) Non contrast-Enhanced CT

A 5×6 cm round radio dense mass lesion in anterior interhemispheric arising from the falx was seen. Mild mass effect without surround-

^a Assistant Professor of Neurosurgery, School of Medicine and Maternity Research Center, Kermanshah University of Medical Sciences, Kermanshah, Iran.

^b Assistant Professor of Gynecology, School of Medicine and Maternity Research Center, Kermanshah University of Medical Sciences, Kermanshah, Iran.

^c Assistant Professor of Pathology, Kermanshah University of Medical Sciences, Kermanshah, Iran.

* Corresponding Author

E-mail: fakheritaravats@yahoo.com

ing edema was present. Punctuate hyper dense area due to calcium deposition was also noted. At the site of previous craniotomy a surgical defect in the right temporal bone and adjacent right frontal lobe encephalomalacia was seen (Figure 1).

After a bicoronal incision at the previous site, a craniotomy was done by removing the right frontal bone. After opening the Dura mater, sub frontal and interhemispheric dissection anteriorly revealed the mass originating from falx cerebri which extended laterally in to the right frontal lobe and was tough, fibrous and beige in color. The capsule of the mass was opened and yellowish cotton wool and creamy soft tissue was removed without complication. After operation anti convulsant therapy continued and the patient was discharged with good condition and without any symptoms. Her headache and seizure were resolved.

Pathologic Report

Gross examination of the received specimen showed fragments of gray-white firm tissue measuring 2×1×3 cm, totally (Figure 2).

Microscopic examination of the several H&E stained slides showed hyalinized tissue containing several foreign body granulomas (Figure 3).

Polarizing microscope revealed refractile material gauze fibers (Figure 4).

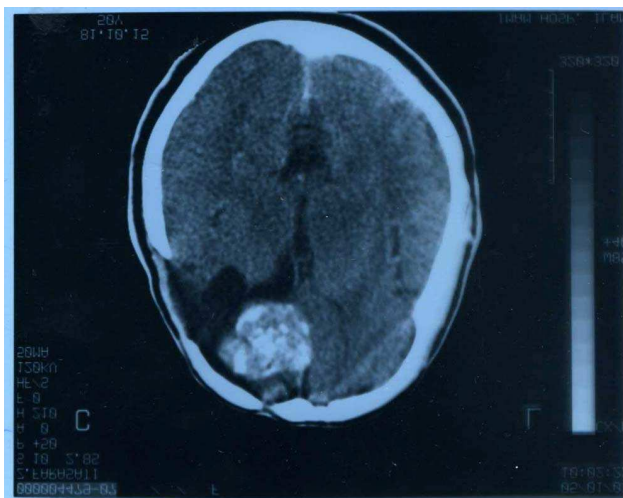

Figure 1. A 5×6 cm round radio dense mass lesion in anterior interhemispher

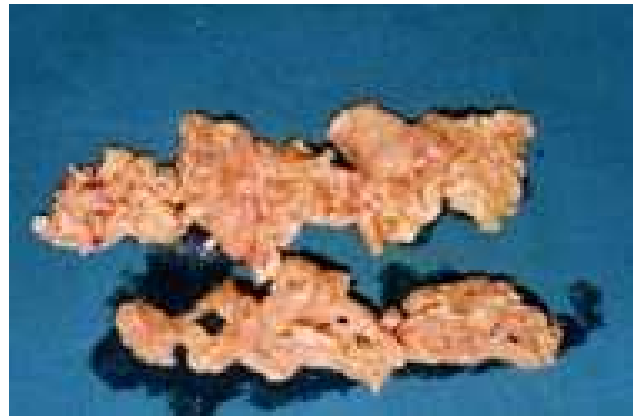

Figure 2. The gross view of Intracranial foreign body

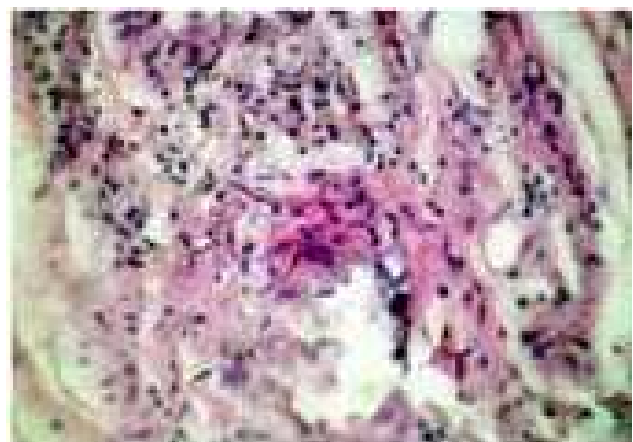

Figure 3. Microscopic view of the Intracranial foreign body

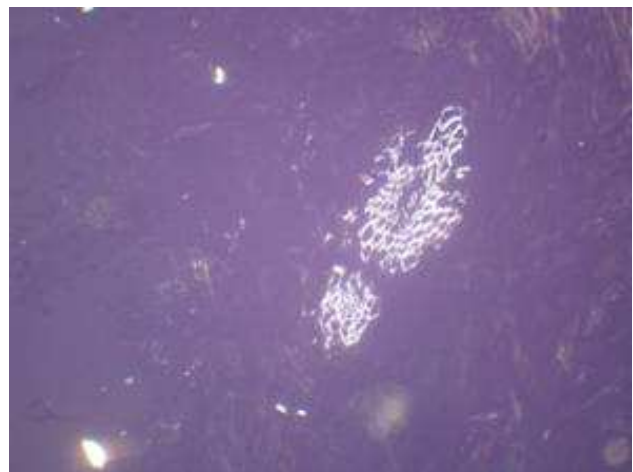


Figure 4. The polarizing microscopic view of Intracranial foreign body

Discussion

Clinical symptoms caused by foreign body granulomas can be noticed from months to many years after surgical procedure. Suture

material is the most common etiology of granulomas in noncentral nervous system surgery; and various symptoms depending on deposited location can be seen. They can simulate neoplasm clinically, radiologically, and even grossly.^{5,6}

Two cases reported by Leong et al, illustrate the difficulty of detecting an unsuspected foreign body in MRI. When the signal characteristics and morphology may appear conflicting or uncertain on MRI, consideration can be given to the use of CT, which is more sensitive to the presence of hemorrhage, gas, calcium or man-made material. While a foreign body may be overlooked or difficult to demonstrate on MRI, addition of CT, ultrasound or plain X-ray may provide a useful adjunct to diagnosis.⁷

Searching published papers from 1965 to 2001 with keywords "foreign body granuloma" and "brain," 20 such reports were found. Cotton materials used commonly for hemostasis

during various operations may cause a foreign body granulomatous reaction that may resemble recurrent or progressive neoplasm or abscess. They can have the same appearance on postoperative imaging studies.⁸

Conclusions

When suspecting a central nervous system mass lesion as primary or recurrent, a second look laparotomy should be planned to determine the true nature. The final treatment decisions depend on the nature of the mass lesion. In case of tumor recurrence, surgical resection and additional oncologic consultation should be recommended; if the resection yields a foreign body reaction, potentially harmful therapy can be withheld or postponed.⁹

Although rare, differential diagnosis of foreign body granuloma is stressed to pay attention not to leave cotton pledgets during operations.¹⁰

Conflict of Interests

Authors have no conflict of interests.

Authors' Contributions

HS carried out the experiment, analyses, interpretation, and presentation and wrote the paper. TF planned the project and assisted in analyses, interpretation, and presentation and edited the manuscript. BI was in charge of pathologic report and co-designed experiments. All the authors have read and approved the content of the manuscript.

References

1. Dinesh SK, Lee SY, Thomas J. A case of mistaken identity: intracranial foreign body reaction after AVM embolisation mimicking a glioma. *J Clin Neurosci* 2008; 15(4): 463-5.
2. Nakayama T, Shimazaki K, Ono J, Ohsato K, Yamaura A. Intra cranial foreign body granuloma caused by fine cotton fibers: a case report. *No Shinkei Geka* 1994; 22(11): 1081-4. (Japanese).
3. Chambi I, Tasker RR, Gentili F, Loughheed WM, Smyth HS, Marshall J, et al. Gauze-induced granuloma ("gauzoma"): an uncommon complication of gauze reinforcement of berry aneurysms. *J Neurosurg* 1990; 72(2): 163-70.
4. Ribalta T, McCutcheon IE, Neto AG, Gupta D, Kumar AJ, Biddle DA, et al. Textiloma (gossypiboma) mimicking recurrent intracranial tumor. *Arch Pathol Lab Med* 2004; 128(7): 749-58.
5. Crundwell N, O'Donnell P, Saifuddin A. Non-neoplastic conditions presenting as soft-tissue tumors. *Clin Radiol* 2007; 62(1): 18-27.
6. Feldman RP, Marcovici A, Suarez M, Goodrich JT. Foreign body granuloma mimicking intracranial meningioma: case report and review of the literature. *Neurosurg* 1999; 44(4): 855-8.
7. Leong SK, Laing B, Saines N. Magnetic resonance imaging (MRI) and computed tomography (CT) findings in intrathecal catheter granuloma: report of two cases. *Eur J Radiol Extra* 2010; 74(2): e17-21.
8. Menkü A, Akdemir H, Tucer B, Konaş O, Durak AC. Foreign body granuloma mimicking recurrent of convexity meningioma. *Turk Neurosurg* 2003; 13(1-2): 53-6.
9. Kothbauer KF, Jallo GI, Siffert J, Jimenez E, Allen JC, Epstein FJ. Foreign body reaction to hemostatic materials mimicking recurrent brain tumor. Report of three cases. *J Neurosurg* 2001; 95(3): 503-6.
10. Suga T, Ohara H. A case of foreign body granuloma caused by cotton pledgets that remained during intracranial operation. *No Shinkei Geka* 1987; 15(3): 289-92. (Japanese).