

Case Report**Rosai-Dorfman Disease with nodal and extranodal involvements: A case report**

Mehri Najafi-Sani¹, Hossein Saneian², Fatemeh Mahjoub³

Abstract

Rosai-Dorfman disease (RDD) is a rare lymphoproliferative disorder with nodal and extranodal involvements. Here we report a case of RDD in a 15-year-old female who presented with epigastric pain, fatigue, Raynaud phenomenon in fingers, submandibular lymphadenopathy, proptosis, hepatosplenomegaly, and round shape painless patches on the extensor surfaces. Histological examination of the submandibular lymph nodes and skin biopsy demonstrated evidences of RDD. Patient was treated with prednisone and thereafter, with azathioprine. After one year, prednisone was discontinued and all of the symptoms and signs, except proptosis, were resolved. This report highlights the extranodal manifestations of RDD. The presentation, differential diagnosis, and treatment are discussed.

KEYWORDS: Rosai-Dorfman Disease, Sinus Histiocytosis, Lymphadenopathy.

J Res Med Sci 2011; 16(9): 1251-1256

Sinus histiocytosis with massive lymphadenopathy (SHML), also known as Rosai-Dorfman disease (RDD), was first described by Rosai and Dorfman in 1969.¹ It is a rare idiopathic proliferative disorder that is commonly characterized by painless, massive cervical lymphadenopathy. RDD frequently affects the cervical lymph nodes and accompanies by fever, leukocytosis, high erythrocyte sedimentation rate and polyclonal hypergammaglobulinemia. The involved lymph nodes show a remarkable proliferation of sinus histiocytes. The hallmark of the SHML is distinctive histiocyte/phagocytic cells within lymph node sinuses and lymphatics in extranodal sites. The cytoplasm of many of the histiocytes contains well preserved lymphocytes, a phenomenon referred to as lymphocytophagocytosis or emperipolesis.² Plasma cells, neutrophils, and red blood cells may also occupy this unique intracytoplasmic niche.^{2,3} The histiocytes of SHML are markedly immunoreactive to the S-100 protein, but the underlying patho-

physiology is remained obscure.⁴ Concurrent extranodal disease, presenting in about half of the cases, may be widespread, but most prevalently involves the skin⁵, upper respiratory tract⁶, skeletal system⁷, followed by the central nervous system⁸, oral cavity⁹, and soft tissue.¹⁰

The outcome is usually good, and the disease is often self-limited.¹¹ Only in a minority of the patients, where massive nodal or extranodal enlargement interferes with organ function or threatens life, treatment is warranted to halt the natural progression of RDD.^{12,13} The most common treatments for RDD include corticosteroid therapy, surgery, radiation therapy, chemotherapy, and newer agents such as interferons.¹¹ The reported mortality rate is about 7%; many patients who have a fatal outcome, suffer from concomitant immune dysfunction.¹¹

In our report, we described a RDD case with concurrent nodal and exclusive extranodal involvements, highlighting the diversity of the clinical presentation of this disease.

1- Associate Professor of Pediatric Gastroenterology, Department of Pediatrics, Tehran University of Medical Sciences, Tehran, Iran.

2- Assistant Professor. of Pediatric Gastroenterology, Department of Pediatrics, Isfahan University of Medical Sciences, Isfahan, Iran.

3- Associate Professor of Pathology, Department of Pathology, Tehran University of Medical Sciences, Tehran, Iran.

Corresponding Author: Hossein Saneian

E-mail: saneian@med.mui.ac.ir

Case Report

A 15-year-old Iranian girl was admitted to Tehran Pediatrics Medical Center, Tehran (IRAN) in June 2006. On admission, she complained of epigastric pain, fatigue, and Raynaud phenomenon in fingers. Also, she had submandibular soft-tissue asymmetry, night sweats, and proptosis (Figure 1) and round shape painless patches on the arm and leg extensor surfaces (Figure 2).

She had previous medical history of frequent pharyngitis, hearing loss since age 3, a left-sided orbital dermoid cyst at age 4, and herpes-zoster infection at age 11. Physical examination revealed two large bilateral submandibular lymph nodes with diameters of 3×2 cm and 1×1.5 cm that were persistent despite antibiotic therapy. She had also undergone splenomegaly and hepatomegaly. Laboratory examination revealed mild leukopenia [3,700/cu mm³ (normal range = 5000-10000/cu mm³)], iron deficiency anemia [Hb = 10 g/dl (normal, 12-14 g/dl)], red blood cell = 3,800/cu mm³ (normal, 3.9-6.1/cu mm³)], platelet count of 421,000/mm³ (normal, 150,000-400,000/mm³), erythrocyte sedimentation rate

of 98 mm/1st hour (normal, <20 mm/1st hour), and a 4.3 g/dl gamma globulin rate (normal, 0.7-1.2 g/dl). Liver function test was normal. Tuberculin test and serological tests for viral infections including Hbs Ag, Hbs Ab, HBc Ab, HCV Ab, HAV Ab (IgM), HEV Ab (IgM), and VCA (IgM), and also the test for toxoplasmosis were all negative. Bone marrow aspiration showed proportionally erythroid hyperplasia. Liver biopsy showed mild infiltration in portal area and dilatation of central sinusoids. Echocardiography was normal.

We performed biopsy of the neck lymph nodes for the second time as the result of the first one performed two years before admission has been reported as reactive adenitis. Histological examination demonstrated numerous histiocytes invading the lymph sinuses. On immunohistochemical examination, these were positive for S-100 protein and negative for CD1a, a marker of Langerhans histiocytosis (Figure 3). Her skin biopsy showed a dense inflammatory infiltrate into dermis, mainly histiocytes, containing vesicular nuclei, lymphocytes, neutrophils, and plasma cells; i.e., panniculitis.

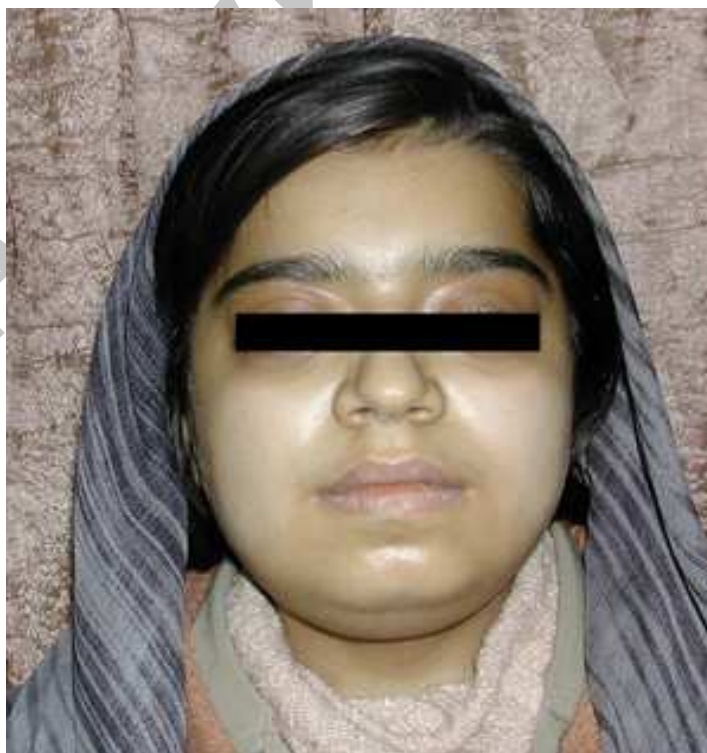

Figure 1. A 15-year-old woman with proptosis

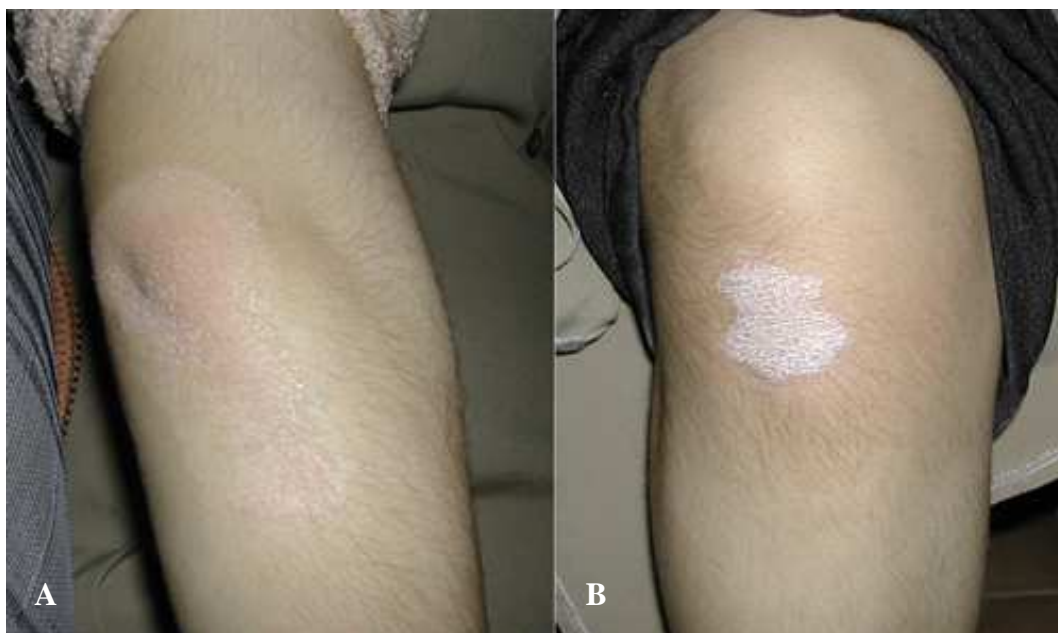

Figure 2. A) Painless patches on extensor surface of the arm.
B) Painless patches on extensor surface of the leg

With the classical features of massive lymphadenopathy and evidence of sinus histiocytosis and the histopathological features of lymph node, diagnosis of RDD was approved. The patient was treated with Prednisone (40 mg/d) for a period of one month, and thereafter the dose decreased and Azathioprine 1 mg/kg was added. After one year, prednisone discontinued and all of the symptoms and

signs progressively resolved, although no change occurred in her proptosis.

Discussion

RDD predominantly affects children and young adults with relatively male sex predominance.² Although some other reports are available from Iran including RDD cases with intracranial^{14,15} and kidney involvement¹⁶, the

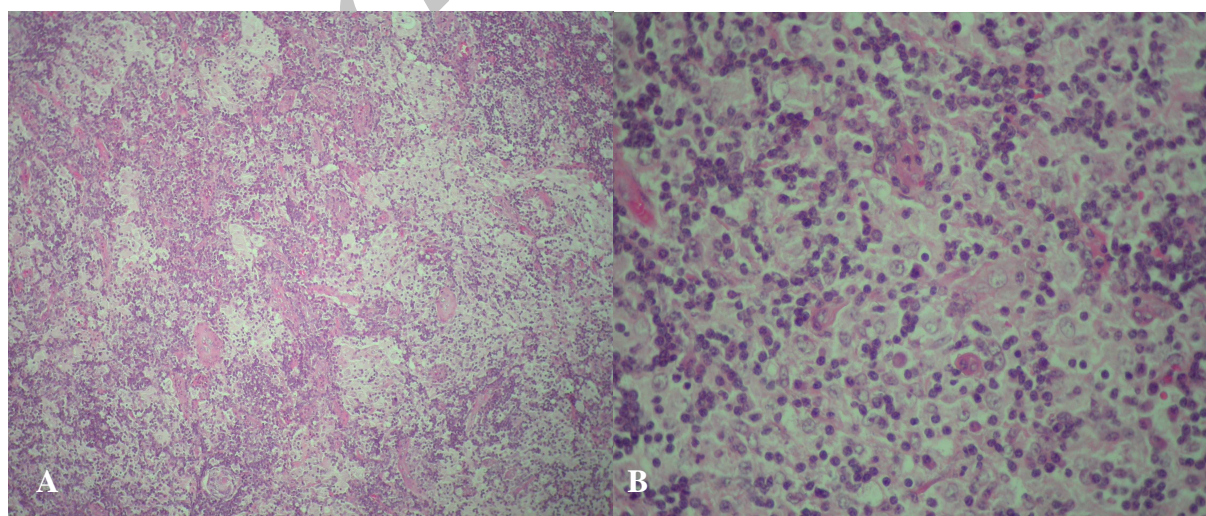


Figure 3. A) Lymph node architecture is rather preserved but sheets of large histiocytes with pale cytoplasm fill the sinusoids. B) Closer view: Large histiocytes with abundant pale cytoplasm are seen, some ingesting blood elements (emperipolesis).

disease is less common in Asian populations.² Its etiology still remains obscure, but two hypotheses have been proposed: a disturbance in inguinal, and mediastinal lymph nodes are also commonly affected. Antecedent non-specific fevers and pharyngitis may herald the onset of RDD, occasionally accompanied by pain, tenderness, malaise, night sweats, or weight loss. Extranodal disease is documented in 43% of cell mediated immunity¹⁷, and a focus of infection due to viruses such as human herpes viruses (HHV-6 and HHV-8).¹⁸ Painless lymphadenopathy is the most frequent presenting symptom and involves the cervical region in up to 90% of the cases. Axillary, para-aortic, the cases, in some of them, without associated lymphadenopathy which may or may not develop later in the disease course.² Hepatosplenomegaly which was present in our case is relatively an uncommon finding in RDD as very few cases with splenomegaly and or hepatomegaly have been reported.^{19,20}

Widespread concurrent nodal and extranodal involvements have also been reported by other authors. Konca et al. reported a case of RDD presented with inguinal lymphadenopathy in which lung, renal and bone were also extensively involved.²¹ In such patients, numerous extranodal involvements pose a diagnostic challenge, as was the problem in our case. Involvement of the neck area, skin, soft tissue, liver, spleen, orbit, and bone elicited a wide differential diagnosis. RDD in lymph nodes may clinically mimic Hodgkin and non-Hodgkin lymphoma, infectious processes, granulomatous lymphadenitis, reactive lymphadenopathy or other histiocytoses including Langerhans cell histiocytosis (LCH) and metastatic carcinoma. Histiocytic disorders, particularly Langerhans cell histiocytosis must be distinguished from RDD affecting skin, soft tissue, and bone. Another external manifestation is orbital soft-tissue mass with proptosis, which can present without any sign suggestive of lymphadenopathy.²² Skin lesions of RDD may be solitary or multiple, macular or papulonodular, xanthomatous or erythematous,

dermal or subcutaneous, and found in virtually any location including the face, ears, trunk, extremities, or genitalia.⁵ Histological findings of skin lesion biopsy specimens are similar to those found in lymph nodes. However, the lesions of RDD can be localized in the soft tissue mimicking a subcutaneous mass or panniculitis cutaneous. Also, it has been clinically mistaken for other dermatologic disorders including vasculitis, acne vulgaris, lupus vulgaris, sarcoidosis, hidradenitis suppurativa, granuloma annulare, malignant breast neoplasm, and other histiocytosis.²³

The histological differential diagnosis includes LCH, storage disorders such as Gaucher disease, classical Hodgkin lymphoma, metastatic melanoma and carcinoma, histiocytic sarcoma, and infections caused by *Histoplasma* and mycobacterial organisms involving the lymph node. In the nasal cavity, rhinoscleroma may morphologically resemble RDD but is distinguished by the identification of *Klebsiella rhinoscleroma*. Perhaps the most frequently faced histological challenge is that of distinguishing SHML from reactive sinus histiocytic proliferations which occur as nonspecific responses to a variety of instigating agents. Emperipolesis is rare or absent in reactive histiocytic proliferations. Although erythrophagocytosis is seen in reactive and neoplastic histiocytic proliferations including LCH, emperipolesis in a setting outside of SHML is extremely rare. The appearance of lymph node sinuses expanded by a histiocytic proliferation is a feature common to LCH and SHML², but in our case LCH was unlikely because Langerhans histiocytes with their familiar folded nuclei and eosinophil infiltrates were absent, as was immunoreactivity for CD1a, a reliable marker of LCH.^{2,3}

Conclusion

Since RDD recognition, the constellation of clinical findings has formed an ever-expanding almanac as more and more cases of RDD are diagnosed so it should be included in the differential diagnoses for patients, whoever admitted to our medical center with any of the men-

tioned extranodal involvements. Given the wide range of clinical presentations and the broad pathologic differential diagnosis, the clinical hallmark of massive lymphadenopathy is often crucial for diagnosis of RDD, however, several pitfalls may complicate pathologic diagnosis.

Acknowledgement

We would like to thank the patient who provided a written consent for publication of her medical history within this case report. Also, we are thankful to Dr. Ali Gholamrezaei from Poursina Hakim Research Institute for helping with preparation of this report.

Conflict of Interests

Authors have no conflict of interests.

Authors' Contributions

MNS and Hossein Saneian participated in diagnosis and treatment of the patient and FM participated in pathological study of the patient. All authors participated in writing the draft and editing the final version of the report.

References

1. Rosai J, Dorfman RF. Sinus histiocytosis with massive lymphadenopathy. A newly recognized benign clinicopathological entity. *Arch Pathol* 1969; 87(1): 63-70.
2. Foucar E, Rosai J, Dorfman R. Sinus histiocytosis with massive lymphadenopathy (Rosai-Dorfman disease): review of the entity. *Semin Diagn Pathol* 1990; 7(1): 19-73.
3. Lussier C, Klijanienko J, Brisse H, Quintana E, Vielh P, Brousse N. Cytology of Rosai-Dorfman disease. *Diagn Cytopathol* 2001; 24(4): 298-300.
4. Mannan AA, Karak AK. Sinus histiocytosis with massive lymphadenopathy (Rosai Dorfman disease): evidence for a dendritic cell derivation? *Indian J Pathol Microbiol* 2005; 48(3): 300-4.
5. Frater JL, Maddox JS, Obadiah JM, Hurley MY. Cutaneous Rosai-Dorfman disease: comprehensive review of cases reported in the medical literature since 1990 and presentation of an illustrative case. *J Cutan Med Surg* 2006; 10(6): 281-90.
6. Ali A, Mackay D. Rosai-Dorfman disease of the lung. *Thorax* 2009; 64(10): 908-9.
7. Demicco EG, Rosenberg AE, Bjornsson J, Rybak LD, Unni KK, Nielsen GP. Primary Rosai-Dorfman disease of bone: a clinicopathologic study of 15 cases. *Am J Surg Pathol* 2010; 34(9): 1324-33.
8. Adeleye AO, Amir G, Fraifeld S, Shoshan Y, Umansky F, Spektor S. Diagnosis and management of Rosai-Dorfman disease involving the central nervous system. *Neurol Res* 2010; 32(6): 572-8.
9. Sridhara SK, Shah RK. Rosai-Dorfman in the submandibular salivary glands of a pediatric patient. *Laryngoscope* 2010; 120(Suppl 4): S228.
10. Al-Daraji W, Anandan A, Klassen-Fischer M, Auerbach A, Marwaha JS, Fanburg-Smith JC. Soft tissue Rosai-Dorfman disease: 29 new lesions in 18 patients, with detection of polyomavirus antigen in 3 abdominal cases. *Ann Diagn Pathol* 2010; 14(5): 309-16.
11. Pulsoni A, Anghel G, Falcucci P, Matera R, Pescarmona E, Ribersani M, et al. Treatment of sinus histiocytosis with massive lymphadenopathy (Rosai-Dorfman disease): report of a case and literature review. *Am J Hematol* 2002; 69(1): 67-71.
12. Abou-Zeid AH, Herwadkar A, du PD, Gnanalingham KK. Isolated extradural Rosai-Dorfman disease of the thoracic spine: a rare cause of spinal cord compression: case report. *Neurosurgery* 2010; 67(2): E514-E515.
13. Zhou LF, Chen L, Zhu Q, Wang C, Xu H, Cui XF, et al. Unusual life-threatening Rosai-Dorfman disease of the trachea: role of NF-kappaB. *Thorax* 2010; 65(10): 927-9.
14. Zahiri A, Rahmat H, Shojaiee A. A Rare Presentation of Rosai-Dorfman Syndrome: First Reported Case in Iran. *Iranian Journal of Radiology* 2005; 3(1): 23-8.
15. Seyednejad F, Tubbs RS, Shoja MM, Daghighi MH, Oakes WJ. Presumed recurrence of intracranial Rosai-Dorfman disease as a cervical spine tumor. *Acta Neurochir (Wien)* 2007; 149(4): 425-7.
16. Abdollahi A, Ardalan FA, Ayati M. Extranodal Rosai-Dorfman disease of the kidney. *Ann Saudi Med* 2009; 29(1): 55-7.

17. Hsiao CH, Tsai TF, Yang TH, Liu CM. Clinicopathologic characteristics of Rosai-Dorfman disease in a medical center in northern taiwan. *J Formos Med Assoc* 2006; 105(9): 701-7.
18. Ortonne N, Fillet AM, Kosuge H, Bagot M, Frances C, Wechsler J. Cutaneous Destombes-Rosai-Dorfman disease: absence of detection of HHV-6 and HHV-8 in skin. *J Cutan Pathol* 2002; 29(2): 113-8.
19. Chow CP, Ho HK, Chan GC, Cheung AN, Ha SY. Congenital Rosai-Dorfman disease presenting with anemia, thrombocytopenia, and hepatomegaly. *Pediatr Blood Cancer* 2009; 52(3): 415-7.
20. Riyaz N, Khader A, Sarita S. Rosai-Dorfman syndrome. *Indian J Dermatol Venereol Leprol* 2005; 71(5): 342-4.
21. Konca C, Ozkurt ZN, Deger M, Aki Z, Yagci M. Extranodal multifocal Rosai-Dorfman disease: response to 2-chlorodeoxyadenosine treatment. *Int J Hematol* 2009; 89(1): 58-62.
22. Prabhakaran VC, Bhatnagar A, Sandilla J, Olver J, Leibovitch I, Ghabrial R, et al. Orbital and adnexal Rosai-Dorfman disease. *Orbit* 2008; 27(5): 356-62.
23. Landim FM, Rios HO, Costa CO, Feitosa RG, Rocha Filho FD, Costa AA. Cutaneous Rosai-Dorfman disease. *An Bras Dermatol* 2009; 84(3): 275-8.

Archive of SID