

Case Report**Endoscopic resection of large colonic lipomas assisted by a prototype single-use endoloop device**

Ahmad Khosravi Khorashad¹, Seyyed Musaalreza Hossein²,
Kamran Gaffarzadegan³, Mohammad Reza Farzanehfar⁴, Hamid reza Zivarifar⁴

Abstract

Colonic lipomas are benign adipose tumors that do not usually cause symptoms. Giant colonic lipoma (GCL) is an uncommon finding at endoscopy which may lead to iron deficiency anemia (IDA) with or without macroscopic ulceration. The choice of therapeutic procedure to treat symptomatic GCLs has been controversial. A case of GCL presented with occult bleeding and IDA is reported in this article. IDA resolved following the successful removal of the GCL by a combination of endoloop ligation and snare cautery technique.

KEYWORDS: Endoscopic Therapy, Giant Submucosal Lipoma, Iron Deficiency Anemia.

J Res Med Sci 2011; 16(11): 1511-1515

A 45-year-old male was seen in consultation for iron deficiency anemia (IDA) and occasional fresh rectal bleeding. He had no significant prior medical history and his physical examination did not reveal any other remarkable issue.

Laboratory data showed a hemoglobin of 9.9 g/dl (range: 14-18 g/dl), hematocrit of 30.4% (range: 42-52%), red blood cell distribution width of 9.5% (range: 4.5- 11.5%), and a mean corpuscular volume of 74 fl (range: 82-98 fl). Iron studies showed an iron saturation of 18% (range: 20-50%), total iron binding capacity of 483 µg/dl (280-400 µg/dl), and a serum ferritin of 9 ng/ml (range: 12-300 ng/ml). The values were consistent with IDA. Routine chemistries, white blood count, platelets, comprehensive metabolic panel, and coagulation studies were all normal.

The patient underwent an esophagogastroduodenoscopy (EGD) and a colonoscopy to investigate his anemia. EGD was unremarkable up to the second part of the duodenum. However, the colonoscopic examination revealed a large, broad-based polypoid lesion in the region of the sigmoid colon (Figure 1). The mass was soft, approximately 8 centimeters in diameter, and yellowish in color. It also exhibited a "pillow sign" on probing with a biopsy forceps. Biopsies showed benign inflammation without any adenomatous changes. Therefore, it was decided to endoscopically remove the lesion.

After obtaining a written informed consent, the lipoma was removed. In order to reduce the risk of subsequent bleeding, we elected to perform endoloop ligation prior to snare cautery resection. An endoloop was

1- Associate Professor, Department of Gastroenterology and Hepatology, School of Medicine, Mashhad University of Medical Sciences, Mashhad, Iran.

2- Assistant Professor, Department of Gastroenterology and Hepatology, School of Medicine, Mashhad University of Medical Sciences, Mashhad, Iran.

3- Clinical Pathologist, Department of Gastroenterology and Hepatology Mashhad University of Medical Sciences, Razavi Hospital, Mashhad, Iran

4- Gastrointestinal Fellowship, Department of Gastroenterology and Hepatology, School of Medicine, Mashhad University of Medical Sciences, Mashhad, Iran.

Corresponding Author: Mohammad Reza Farzanehfar
E-mail: r_farzaneh_m@yahoo.com

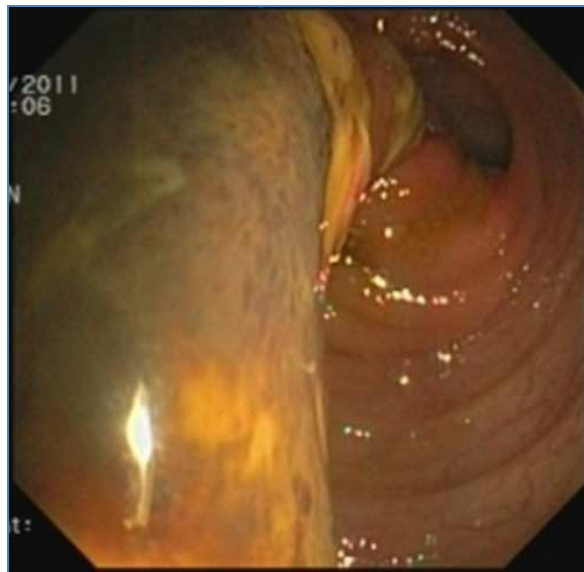


Figure 1. Colonoscopic view of the 8cm sigmoid mass

placed around the base of the polyp and was slowly tightened to include the surrounding mucosa with the stalk. Then, the giant lipoma was resected using a blended current with a rotatable snare above the endoloop (Figures 2 and 3). There was no bleeding from the polypectomy site and the patient tolerated the procedure without any complications. He was discharged 48 hours after the procedure. Being asymptomatic, he was prescribed with a short course of oral antibiotics (metronidazole

500 mg a day for 5 days) to prevent postpolypectomy syndrome.

On microscopic examination, the tumor had uniform parenchyma in bright yellow color resulting in lobulated appearance of the lipoma in the absence of fat necrosis, granulation or ulceration which confirmed the diagnosis of colonic lipoma (Figure 4).

Repeated hemoglobin, hematocrit, and iron studies showed normal values after six weeks of follow-up.

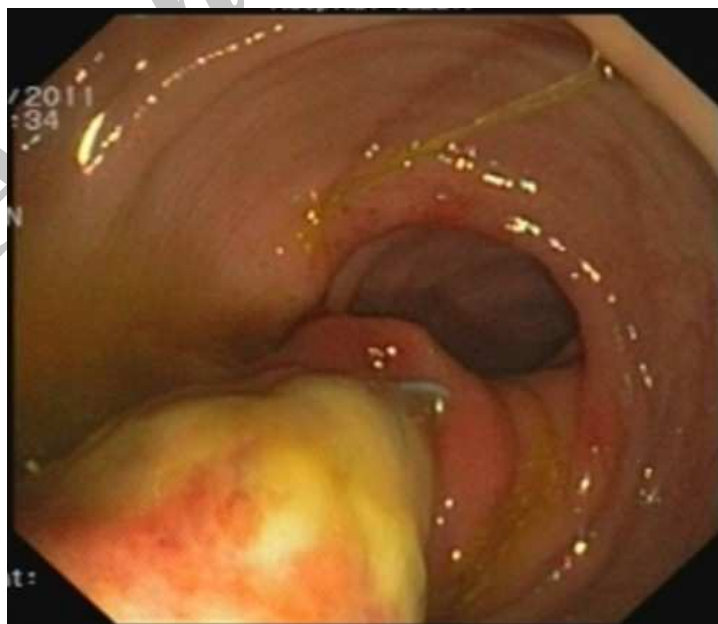


Figure 2. Endoloop placement around the base of the polyp

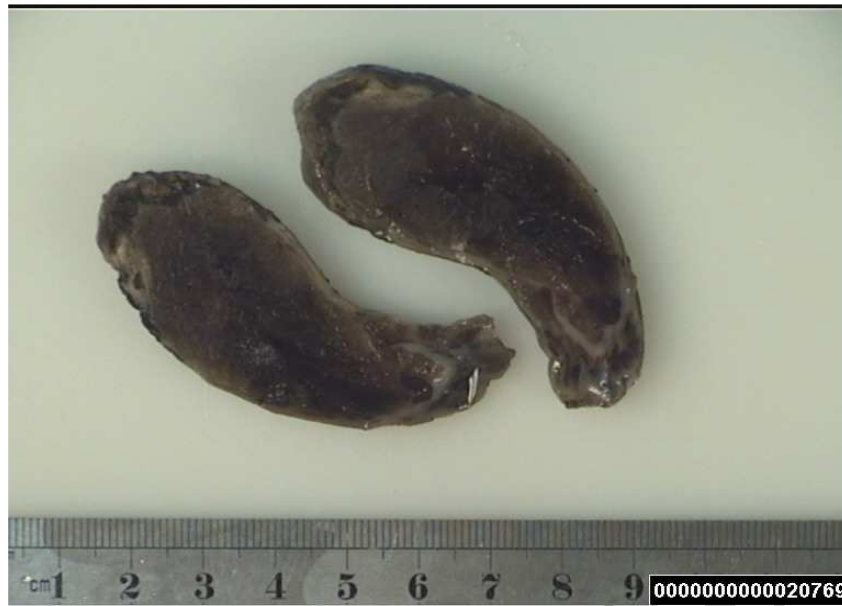

Figure 3. Macroscopic examination of the polyp after polypectomy

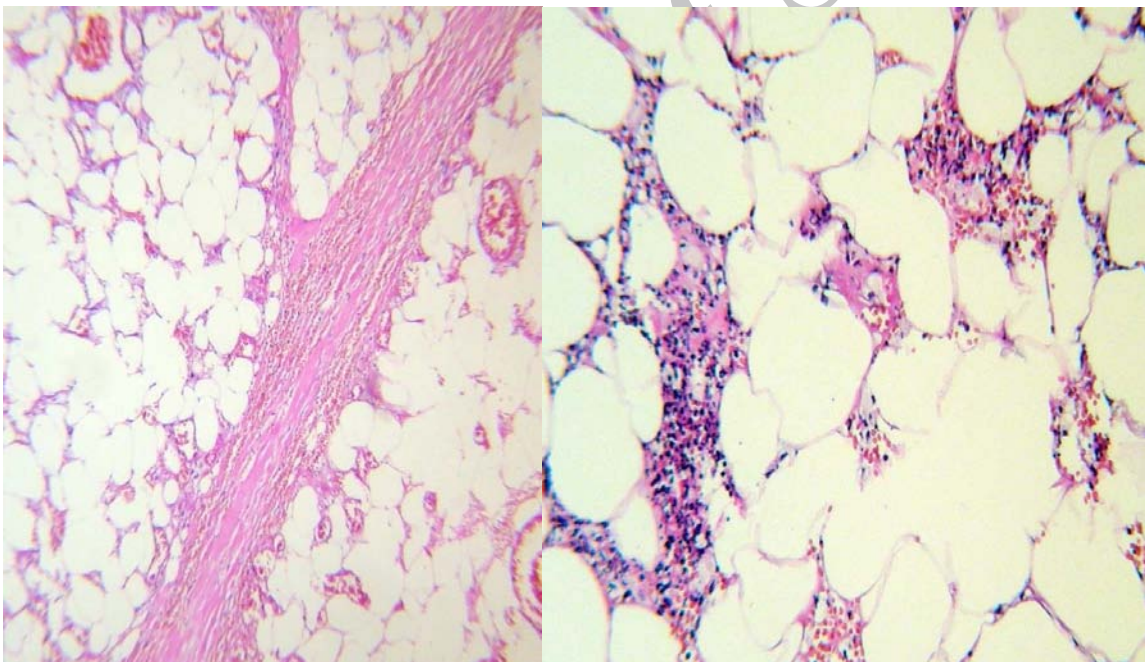


Figure 4. The histological examination showed the characteristics of the colonic lipoma. No evidence of malignancy was detected.

Discussion

Colon lipomas are often confused with adenomas and other pathological abnormalities. However, these are rare benign tumors whose incidence is reported in autopsy series to vary from 0.035% to 4.4%. They are slightly more prevalent in women than in men. Colon lipoma occurs more commonly in the fifth and

sixth decades of life.¹⁻³ In the colon, lipomas are mainly right sided. Their prevalence decreases from the cecum to ascending colon and to sigmoid colon.³ They usually occur solitarily but multiple lipomas can be seen in 15% of the cases.² While about 90% of colon lipomas originate from submucosa, some have subserosal or intermucoserosal origins.^{1,2}

These lesions are encapsulated and are either sessile or pedunculated.^{1,2} They can cause significant clinical symptoms such as rectal bleeding, abdominal pain, obstruction, intussusceptions. In addition, spontaneous expulsion of the lipoma has rarely been reported.¹⁻³ The most common symptoms are bleeding and abdominal pain. Clinical symptoms may be related to the tumor size making patients with a tumor of 3.5 cm in symptomatic and those with a tumor of 1.8 cm asymptomatic.¹ In general, lipomas of greater than 2 cm in diameter seem to be capable of producing symptoms.² Since barium enema is nonspecific for round and regular filling defects, the only definitive diagnosis is endoscopic diagnosis. The characteristic findings include the mucosa being elevated over the lipoma with the biopsy forceps (tent sign), indentation of the lipoma with the biopsy forceps (so-called "cushion sign" or "pillow sign"), or the "naked fat sign" where the fat can be extruded after removal or serial biopsy.⁴ Surgical or endoscopic removal is indicated for such lesions.⁵ Tamura et al. suggested that lipomas greater than 20 mm in diameter should be resected surgically. They also advocated utilizing magnifying videoscopy and endoscopic ultrasonography to aid in diagnosis.⁶ A detailed endoscopic examination of the base of the lesion is necessary (magnifying videoscopy and endoscopic ultrasonography are proposed) to decide whether endoscopic resection is possible (histopathology on all lipomas that resulted in perforation contained portions of muscularis propria and serosa invaginated into the pedicle). However, the indication of endoscopic resection of colonic lipoma is still a subject of controversy.

Endoscopic removal of large colonic lipomas is technically difficult because of their vascular nature, large pedicle, and size.⁵ However, endoscopic removal of lipomas of 2-4 cm or greater in diameter has been associated with a high risk of perforation⁷ and increased morbidity compared with retrieving adenomatous polyps. It might be due to the fact that fatty tissue does not conduct electric-

ity well and increasing the power to assist the completion of the polypectomy leads to increased heat production which damages the adjacent bowel wall with subsequent perforation (lipomatous tissue contains a lower water content and therefore conducts electrosurgical current less efficiently).⁸ Endoloop ligation of colonic lipomas appears to be a promising new technique in the management of patients with large colonic lipomas who are otherwise referred for surgery to avoid the high risk of perforation associated with snare cautery. Further validation of this technique is required. Endoloops have been successful in the management of masses arising from the muscularis propria (big and long stalk) using the "ligate and let go" technique (without endoscopic resection).⁹ Sessile or broad semipedunculated lesions preclude endoloop placement. If the pedicle is 4 mm or less in diameter, the loop cannot be tightened sufficiently to ensure hemostasis. Therefore, it is doubtful that a loop is useful in this situation. Moreover, for extremely broad semipedunculated or sessile lesions, closure of the loop beneath the planned resection margin may be impossible since the intended resection margin may lie beneath the loop closure.¹⁰ If there is a large visible blood vessel in the stalk, then placing a hemoclip before or after polypectomy is possible to decrease post-procedure bleeding.⁸

Conclusion

Colonic lipomas are benign tumors typically being incidentally diagnosed during colonoscopy. In the case of small pedunculated lipomas, there is no increased risk of removal compared to pedunculated adenomatous polyps. Despite endoscopic removal being technically difficult because of the vascular nature, large pedicle, and size of the colonic lipomas, we believe that it is safe, feasible and effective to use standard polypectomy technique for endoscopic removal of colonic lipomas larger than 2 cm with the availability of endoloop (in case of long stalk) and hemoclips (in case of bleeding) to prevent uneventful complications.

Conflict of Interests

Authors have no conflict of interests.

Authors' Contributions

AK selected the case and planned the report. SMRH and KG assisted in case selection. MRF conducted the study and wrote and finalized the report. HRZ assisted in writing the report. All authors have read and approved the final draft of the paper.

References

1. Rogy MA, Mirza D, Berlakovich G, Winkelbauer F, Rauhs R. Submucous large-bowel lipomas--presentation and management. An 18-year study. *Eur J Surg* 1991; 157(1): 51-5.
2. Hancock BJ, Vajcner A. Lipomas of the colon: a clinicopathologic review. *Can J Surg* 1988; 31(3): 178-81.
3. Castro EB, Stearns MW. Lipoma of the large intestine: a review of 45 cases. *Dis Colon Rectum* 1972; 15(6): 441-4.
4. Pfeil SA, Weaver MG, Abdul-Karim FW, Yang P. Colonic lipomas: outcome of endoscopic removal. *Gastrointest Endosc* 1990; 36(5): 435-8.
5. Kim CY, Bandres D, Tio TL, Benjamin SB, Al-Kawas FH. Endoscopic removal of large colonic lipomas. *Gastrointest Endosc* 2002; 55(7): 929-31.
6. Tamura S, Yokoyama Y, Morita T, Tadokoro T, Higashidani Y, Onishi S. "Giant" colon lipoma: what kind of findings are necessary for the indication of endoscopic resection? *Am J Gastroenterol* 2001; 96(6): 1944-6.
7. Bar-Meir S, Halla A, Baratz M. Endoscopic removal of colonic lipoma. *Endoscopy* 1981; 13(3): 135-6.
8. Bahadursingh AM, Robbins PL, Longo WE. Giant submucosal sigmoid colon lipoma. *Am J Surg* 2003; 186(1): 81-2.
9. Kaltenbach T, Milkes D, Friedland S, Soetikno R. Safe endoscopic treatment of large colonic lipomas using endoscopic looping technique. *Dig Liver Dis* 2008; 40(12): 958-61.
10. Matsushita M, Hajiro K, Takakuwa H, Kusumi F, Maruo T, Ohana M, et al. Ineffective use of a detachable snare for colonoscopic polypectomy of large polyps. *Gastrointest Endosc* 1998; 47(6): 496-9.