

# Epidemiology of venomous and semi-venomous snakebites (Ophidia: Viperidae, Colubridae) in the Kashan city of the Isfahan province in Central Iran

Rouhollah Dehghani<sup>1</sup>, Omid Mehrpour<sup>2</sup>, Morteza Panjeh Shahi<sup>3</sup>, Mehrdad Jazayeri<sup>3</sup>, Parissa Karrari<sup>2</sup>, Dan Keyler<sup>4</sup>, Nasim Zamani<sup>5</sup>

<sup>1</sup>Department of Environmental Health, School of Health, Kashan University of Medical Sciences, Kashan, <sup>2</sup>Atherosclerosis and Coronary Artery Research Center, Birjand University of Medical Science, Medical Toxicology and Drug Abuse Research Center, Birjand University of Medical Sciences, Birjand, <sup>3</sup>Health Center of Kashan University Medical Sciences and Health Services, Kashan, <sup>4</sup>Department of Experimental and Clinical Pharmacology, College of Pharmacy, University of Minnesota, Minneapolis Medical Research Foundation, Minneapolis, Minnesota, MN, United States, <sup>5</sup>Department of Clinical Toxicology, Loghman Hakim Hospital, Shahid Beheshti University of Medical Sciences, Tehran, Iran

**Background:** Information on the epidemiology of venomous snake species responsible for envenomation to humans in Iran has not been well documented. In the Kashan city, venomous snakebite remains a recurring medical problem. Information providing the correct identification of snake species responsible for envenomation in this geographic region would be useful to regional medical clinics and personnel for the effective and optimal management of the patients. **Materials and Methods:** In this cross-sectional study, all patient data was collected from Kashan city and its suburbs. The specific data relating to the taxonomic identification of snakes responsible for envenomation were evaluated. A general approach to the diagnosis and management of patients was also provided. Snakes responsible for bites were transported to a laboratory, where their taxonomic classification was confirmed based on key anatomical features and morphological characteristics. **Results:** A total of 46 snakes were examined. Of these, 37 (80%) were non-venomous species, and 9 (20%) were identified as venomous. Seven of the nine venomous snake species (78%) were of the family Viperidae, and two specimens (22%) were in the family Colubridae. Specifically, the viperid species were *Macrovipera lebetina obtusa*, *Pseudocerastes persicus*, *Pseudocerastes fieldi*, and *Echis carinatus*. The two colubrid species were *Malpolon monspessulanus insignitus* and *Psammophis schkari*. **Conclusion:** Five different species of venomous snakes responsible for envenomation in the Kashan city region were confirmed. The viper, *P. fieldi*, was reported for the first time in the central part of Iran.

**Key words:** Epidemiology, iran, kashan city, snake, snakebite

**How to cite this article:** Dehghani R, Mehrpour O, Shahi MP, Jazayeri M, Karrari P, Keyler D, Zamani N. Epidemiology of venomous and semi-venomous snakebites (Ophidia: Viperidae, Colubridae) in the Kashan city of the Isfahan province in Central Iran. J Res Med Sci 2014;19:33-40.

## INTRODUCTION

Snakes are geographically distributed around the world except for the frozen polar-ice zones and high mountainous altitudes. The majority of species are terrestrial, but others inhabit shorelines, rivers, swamps, and estuaries, and are not found far away from terrestrial environments and habitats.<sup>[1,2]</sup> A few aquatic species inhabit the Pacific and Indo-Pacific oceans and associated waters, and a few are pelagic in nature.<sup>[1,2]</sup>

Approximately, 10% of the approximate 3,500 species of snakes worldwide are considered to be potentially dangerous to humans. Recent estimations of the global toll to humans as a result of venomous snakebite envenomation suggest that 421,000 snake envenomations, and 20,000 deaths occur annually, compared with historical estimates of 5,000,000

snakebites having occurred each year, with greater than 100,000 of them leading to death.<sup>[3]</sup> Regardless of these reported numbers, it is likely that the reported data represent an under-estimation of the true magnitude of the global snakebite problem. Kasturante postulates that given the statistic that envenomation is said to result from one out of every four snakebites, there may be 1.2-5.5 million snakebites occurring annually around the world. Geographically, most cases of venomous snakebite deaths occur in South and Southeast Asia and Sub-Saharan Africa.<sup>[3-5]</sup>

In the country of Iran, 69 indigenous snake species have been identified, of which 36 are non-venomous, 25 are venomous, and 8 are considered semi-venomous.<sup>[6]</sup> Snakebite is a serious public health problem in Iran, particularly in rural areas. The recorded number of snakebites from 2001 to 2009, were approximately 5,000-7,000 per year, of which, approximately seven

**Address for correspondence:** Dr. Omid Mehrpour, Medical Toxicology and Drug Abuse Research Center, Pasdaran Avenue, Birjand University of Medical Sciences, Birjand, Iran. E-mail: [omid.mehrpour@yahoo.com.au](mailto:omid.mehrpour@yahoo.com.au)

**Received:** 26-05-2012; **Revised:** 11-11-2012; **Accepted:** 01-01-2013

deaths were reported each year.<sup>[6]</sup> Snake envenomation patterns, depending on the species, can vary among the four different families common in Iran namely; Colubridae, Elapidae, Viperidae and Hydrophidae. Envenomation can cause a range of symptoms and severity, ranging from mild envenomation where a bite is evidenced by skin punctures and mild swelling to severe symptoms of neurotoxicity, vasculotoxicity, hematological toxicity, and myotoxicity.<sup>[6]</sup>

Iran's venomous snakes have a broad spatial geographic distribution, especially those stretching across great expanses of desert. Venomous snake species within the country are represented by both the Elapidae family (Oxus cobra, *Naja oxiana*) and Viperidae family (Haly's viper, *Gloydius halys*; saw-scaled viper, *Echis carinatus*; Levantine viper, *M. l. obtusa*; Field's horned viper, *Pseudocerastes fieldi*; Persian horned viper, *Pseudocerastes persicus*; Iranian mountain viper, *Vipera albicornuta*). Species that inhabit desert ecosystems are *M. l. obtusa*, *E. carinatus*, *P. fieldi*, *Malpolon monspessulanus* (Montpelier snake), and *Psammodromus schokari* (Sand racer). *P. persicus* and *P. fieldi* inhabit rocky, semi-desert areas mixed with vegetation at elevations up to 2,000 m, and are not found in soft shifting sand areas. Given the varying habitat distribution of the different species, it is thus apparent that, historically, Iranian people have always been exposed to the potential risk of venomous snakebites in any area of the country in which they lived.<sup>[2]</sup>

Snakes in the Viperidae family typically possess curved, tubular-shaped canine teeth that are retractable and canalized located in the upper maxillary region, of the mouth. These specific dentition structures are connected via ducts to an associated venom gland. Viperid snakes usually have a triangular-shaped head and obviously narrowed neck. Their tails tend to be short and their crawling locomotion is slow. Species such as *P. fieldi* and *P. persicus* move in a side-winding motion. The family Viperidae is subdivided into two subfamilies, Viperinae (true vipers) and crotalinae (pit vipers). These two subfamilies are differentiated by the presence of a heat-sensing foramen or "Pit" bilaterally located between each eye and nostril, which is easily distinguishable from the nasal orifice. This anatomical feature is not present in the vipers' native to Middle East geographic regions, as true viper species inhabit the region. The dorsal cranial portions of their viper heads have small and non-symmetrical scales, but in a few species there are symmetrical scales. The eyes of all Iranian viper species have a vertically elliptical pupil. Recognizing these subtle features may be difficult for amateurs and non-herpetologically trained individuals. A unique anatomical feature of *P. persicus* and *P. fieldi* is the presence of scales that form horns above the eye (suprocular shields). However, knowledge of the unique habitat characteristics, which are specific for each snake species, is an important factor aiding in correct species identification,

and minimizing confusion with non-venomous species in the identification process. Thus, the anatomical features, geographical distribution of different snake species, their preferred habitat and associated vegetation types, show unique characteristics for each species. Consequently, the snakes of each geographical region inhabit a specific ecological niche.<sup>[1,2,7]</sup>

Severity of envenomation falls into three general categories of mild, moderate, and severe. In mild envenomation, symptoms include swelling, pain, and tenderness. A moderate envenomation manifests with swelling, pain, tenderness, and systemic effects such as nausea, vomiting, tremor, mild hypotension with evidence of coagulopathy, but without clinical bleeding. In severe envenomation, the complications that develop are shock, profound bradycardia, tachypnea, or respiratory failure, and coagulation disorders characterized by bleeding, and other related manifestations.<sup>[6]</sup> The mainstay in the treatment of envenomation is antivenin. In Iran, of three types of antivenin, including mono-, tetra-, and polyvalent, up to now polyvalent are produced by the Razi Vaccine and Serum Research Institute and have been specifically developed for the treatment of snakebite patients. The polyvalent product can neutralize the venom of six different venomous snake species.<sup>[6]</sup> In general, treatment of mild, moderate, and severe cases require, 2-5 vials, 5-10 vials, and 10-20 vials of antivenin, respectively. However, in extreme cases, as many as 45 vials may be required.<sup>[6]</sup>

Kashan city is located in the north of Isfahan province with an approximate distance of 220 km from Isfahan city. It is in the vicinity of Semnan and Qom province from North, Markazi Province from East, and the central plain from West. Kashan city has two distinct climate-habitats, mountainous and plains. The plains are of a typical desert climate with very hot dry summers and mild winters, while the mountainous area has a semi-arid to arid climate with mild, dry summers and cold winters. Rainfall in both areas is minimal and the desert climate is more prominent with very low rainfall and increasing temperature in the summer being significant complications. Overall, intense dry weather conditions are the outstanding climatic characteristics for the region.

In a previous study performed in Kashan city, the incidence of snakebite was reported to be 2.5 cases per 100,000, which is lower than the average number of snakebites reported for the country of Iran as a whole (6.9 cases per 100,000). The majority of snakebite patients were male (96%), and 68% of snakebites occurred in rural areas of Kashan. The greatest rate of snakebite occurred in 15-24-year-old people, an age range that also represented the largest working group. The highest incidence of snakebites was observed during the summer (60%). Limbs are at higher risk of snakebites compared with the head and trunk.<sup>[6]</sup>

Management of venomous snakebite patients has always been a major health-problem within the country. The diversity of envenomation profiles resulting from bites by snakes with this wide geographic distribution, ranging from the southern island in the Persian Gulf to the northern area of Iran, presents a medical problem that requires caution and pause for medical personnel when considering treatment of the envenomated patient.<sup>[8,9]</sup> Reporting the specific identity of animal species, especially venomous snake species is therefore, important and allows critical evaluation as to which are the more medically important species, leading to more enhanced medical care of patients' envenomated by certain snake species. This study was performed in Kashan city, in the Isfahan Province of central Iran, and the study's aim was to determine the species of snakes responsible for snakebite in this region of Iran, and those impacting human health. We also aimed to provide general diagnostic and treatment guidelines to treat the envenomation by these snakes.

## MATERIALS AND METHODS

This was a cross-sectional study of snakebite reports from Kashan city of the Isfahan Province in Central Iran for the period from 2004 to 2010. All snake specimens, living or non-living, were collected in both active and passive ways for evaluation. Non-living specimens were preserved in ethanol, labeled with date, geographic locality, and specific place of collection documented. All specimens were sent to Kashan city, Department of Environmental Health, Kashan city, and University of Medical Sciences, Laboratories, Iran. Snakes were identified by Dr. Rohollah Dehghani, and classified taxonomically based on specific morphological features, and anatomical characteristics with the use of taxonomic identification keys for assignment to proper genus and species, and classified as non-venomous, semi-venomous, or venomous.<sup>[2,10]</sup>

Uniform questionnaires were used for data collection and filled out by individuals who collected the snake specimens. All questionnaires were reviewed and relevant data extracted for determination of: (1) where snakes were collected geographically (urban, suburban, or rural), (2) type of habitat environment where collected (desert, mountain, forest), (3) collection site (indoors, outdoors, abandoned homes and factories), (4) date and time of collection (day, night, hour), (5) specimen disposition (alive, dead, preserved, killed), (6) snake morphological features (body length, triangular head shape, vent to tip of tail length, body color and pattern), (7) classification to Family, Genus and species, and (8) species confirmed as venomous, semi-venomous, or non-venomous. Individual snake collector status with respect to type of career work was documented, and whether they were bitten or unharmed during the specimen/snake collection process was also recorded. Medical details of envenomation were not collected.

## RESULTS

A total of 46 snakes were collected and presented to the laboratory (32 presented alive), for evaluation. The majority of specimens, 32 snakes (70%) were collected from rural areas, none were collected in suburban areas, and 14 snakes, (30%) were from urban areas. Non-venomous specimens were the most common and accounted for 37 (80%) of the total number of snakes evaluated.

Seven (15%) specimens were confirmed as venomous species of the Viperidae family: *M. l. obtusa* ( $n = 3$ ), *P. persicus* ( $n = 2$ ), *P. fieldi* ( $n = 1$ ), and *E. carinatus* ( $n = 1$ ). Two specimens (4%), *Malpolon monspessulanus insignitus* and *P. schokari* were classified as semi-venomous. All venomous snakes were collected from non-residential rural areas.

*M. l. obtusa*, was the most frequently collected venomous snake species, and specimens were collected from Armack, Naragh, and Niasarsar [Figure 1]. *P. persicus* were collected from Nyasar, Mashhad Ardehal [Figure 2]. The single *P. fieldi* specimen represents the first such specimen to be collected, reported, and documented in central Iran [Figures 3a, b]. *E. carinatus* was collected from Ghamsar [Figure 4]. *M. m. insignitus* was collected in the rural area between Mashkan and Khoragh, in the vicinity of a milk pasteurizing factory [Figure 5]. Non-venomous snakes collected were represented by eleven different species, primarily of the genus *Coluber*. See Table 1 and Figure 6 for occurrence and distribution details.

## DISCUSSION

The significance of this study's results relate to the confirmation that four species of venomous snakes, and two species of semi-venomous snakes, belonging to the Viperidae and Colubridae families, respectively, are currently found in the Kashan city in Isfahan Province, Iran. Additionally, there are eight other non-venomous species present in the region. Classification of venomous, semi-venomous, and non-venomous snakes can be performed in several ways.

The most confirmative method to distinguish the differences between non-venomous, semi-venomous, or venomous species, involves the inspection of a snakes' dentition (anatomical fang structures or lack of fang structures). Non-venomous snakes are aglyphous in that they have simple rows of shorter, conical-shaped teeth, which are not canaliculated or grooved, and are not connected to a secretory or venom gland. There is no pronounced enlargement of the anterior or posterior maxillary teeth. The semi-venomous snakes *M. m. insignitus* and *P. schokari* are opisthogyphous, possessing posterior maxillary teeth, which are larger and more prominent

**Table 1: Occurrence of snakes in urban and rural Kashan city, Isfahan province, Iran represent the total number of snakes collected in urban and rural environments**

Genus spices	Toxicology	No.	Urban (14)	Rural (32)	Habitate	Collection site	Collection time
<i>Macrovipera lebetina obtusa</i>	Venomous	3		Armak Naragh Niasar	Mountain Semi-desert	Non-residential	Morning
<i>Pseudocerastes persica</i>	Venomous	2		Mashhad Ardehal Niasar	Mountain Semi-desert	Non	Morning
<i>Pseudocerastes fieldi</i>	Venomous	1		Khozagh	Semi-desert	Non	Morning
<i>Echis carinatus</i>	Venomous	1		Ghamsar	Mountain	Non	Morning
<i>Malpolon monspessulanus</i>	Semi.venomous	1		Khaveh village	Hilly Semi-desert	Non	Morning
<i>Pasmomphis schokari</i>	Semi.venomous	1				Non	Morning
<i>Coluber jugularis</i>	Non-venomous	37	Aran	Ghamsar	Semi-desert	Nonresidential and residential	Morning and evening
<i>Coluber ravergieri</i>			Bidgol	Hosseiniabad			
<i>Coluber rhodorachis</i>			Kashan	Mashkan			
<i>Coluber najadum</i>			Niasar	Niasar			
<i>Coluber karelini</i>			Ravand	Taherabad			
<i>Erix elegans</i>							
<i>Erix miliaris</i>							
<i>Lycodon striatus</i>							
<i>Natrix tessellate</i>							
<i>Spalerosophis diadema</i>							
<i>Spalerosophis microlepis</i>							

**Figure 1:** *Macrovipera lebetina obtusa* (Picture by Dehghani R)**Figure 2:** *Pseudocerastes persicus* (Picture by Dehghani R)**Figure 3a:** *Pseudocerastes persicus* (Picture by Dehghani R)**Figure 3b:** *Pseudocerastes fieldi* (Picture by Dehghani R)



Figure 4: *Echis carinatus* (Picture by Keyler D)



Figure 5: *Malpolon monspessulanus insignitus*

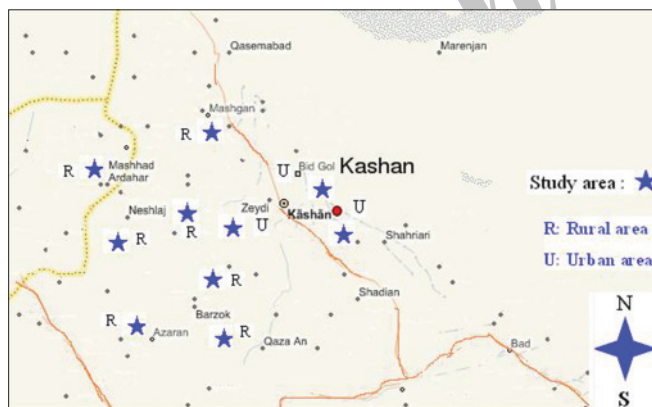


Figure 6: Map of Kashan and study areas

than the anterior teeth, and connected to glands that are of a lesser defined anatomical structure. Viperid snakes are solenoglyphous, possessing retractile fangs that are canaliculated (having a hollow lumen).

Climatic conditions and weather patterns occurring in different parts of the mountane and desert regions of this

defined geographic Kashan city area are highly variable, providing favorable conditions and habitats for multiple different snake species. In this study, the most abundant venomous species collected was *M. l. obtusa*, and it is a species known to tolerate a spectrum of climatic weather conditions from the northern to southern and eastern to western parts of its range.<sup>[1,2,11]</sup> Fatehi-Hassanabad et al.<sup>[12]</sup> have previously reported that the bite of this species can be dangerous to humans, and of significant medical importance.<sup>[12]</sup> *P. persicus* was the second most frequently collected venomous snake species in this study. Surveying for collection of this species involved unique habitat search strategies in rural country involving cemetery grave-stones, hedges, fence lines, and wall cracks/spaces of abandoned old thatch cottages. The distribution of this species has been previously reported in Khorasan, Sistan, Yazd, Esfahan, Fars, Semnan, Markazi, Khuzestan, and Zanjan, provinces.<sup>[1,2,12,13]</sup> *E. carinatus* was responsible for a single bite in this study, and has been previously reported from Semnan, Khorasan, Sistan, Kerman, Fars, Hormozgan, Khuzestan, and Mazandaran Provinces.<sup>[1,2]</sup> More recent confirmation of this viperid species's presence in Iran has been reported by Stümpel et al.<sup>[11]</sup> It is interesting; however, that prior to this study, there were no reports confirming the biological activity or existence of *E. carinatus* in Isfahan Province. Of all the specimens collected, *P. fieldi* was the most surprising, for despite this species having been reported from Kermanshah City,<sup>[1,2]</sup> and Fars Province.<sup>[14]</sup> But, it has never been confirmed present in the Isfahan Province.<sup>[1,2,14]</sup> Thus, the confirmation of *P. fieldi* here represents the first reporting of the viperid species in Isfahan Province, and suggests that the species has a quite limited geographic distribution in Iran. *M. m. insignitus* represents the only semi-venomous colubrid species responsible for snakebite to a human in this case series. It does have enlarged rear fangs, a functional secretory gland, and an aggressive behavior. Although this subspecies is reported as semi-venomous, a bite in France by *M. monspessulanus* has been reported to cause significant neurological symptoms following envenomation.<sup>[15]</sup> Distribution of this species has been reported in eastern and western Azarbaijan, and Ardabil, Markazi, Tehran, Khorasan, Hamedan, Kermanshah, Hormozgan, Khuzestan, Mazandaran and Ghazvin provinces. Furthermore, we have previously reported this species from Isfahan Province, and the documentation represents current confirmation of the species in the Province.<sup>[1,2]</sup> *P. schokari*, inhabits the arid Kavir desert, the great salt desert of Central Iran, and is a fast moving snake. Although it possesses enlarged posterior maxillary teeth and is considered semi-venomous, the consequences of its bite are not known to be documented.

Clinical signs and symptoms associated with bites from the less venomous snakes of the Colubridae family include local swelling, bleeding from the fang marks and

sometimes fainting, and ecchymosis in rare instances.<sup>[16]</sup> Envenomation following bites by the dangerous colubrids of Africa (*Dispholydus typus* and *Thelotornis* spp.) can result in delayed vomiting, colicky abdominal pain and headache, widespread systemic bleeding with extensive ecchymoses, incoagulable blood, intravascular haemolysis, and kidney failure. These may develop slowly over several days.<sup>[16,17]</sup>

Viperidae (sub-families Crotalinae and Viperinae) envenomation can be evidenced by severe local signs and symptoms. Swelling may become detectable within 15 min, but in unusual circumstances may be delayed for several hours. Generally, swelling spreads rapidly and may involve the whole limb and adjacent trunk, with pain and tenderness in regional lymph nodes exist, bruising, blistering, and necrosis developing during the next few days. Blood pressure abnormalities are a consistent feature of envenoming by Viperidae. Spontaneous systemic haemorrhage is most often detected in the gums, but may also be seen as epistaxis, haematemesis, cutaneous ecchymoses, haemoptysis, sub-conjunctival, retroperitoneal, and intracranial haemorrhages. Direct involvement of the heart muscle is suggested by an abnormal electro cardiogram (ECG) or cardiac arrhythmia.<sup>[16,17]</sup>

Laboratory values indicating signs of snake envenomation include raised peripheral neutrophil count (up to 20,000 cells/ $\mu$ L). Initial hemo-concentration resulting from extravasation of plasma, followed by anemia due to bleeding or haemolysis, and thrombocytopenia. A useful test for venom-induced defibrin (ogen) ation is the simple whole blood clotting test. A few millilitres of venous blood is placed in a new, clean, dry, glass test tube, left undisturbed for 20 min at ambient temperature, and then tipped to see if it has clotted. Incoagulable blood indicates systemic envenoming. Patients with generalized rhabdomyolysis show a rise in serum creatine kinase, myoglobin, and potassium. Black or brown urine may suggest generalized rhabdomyolysis or intravascular haemolysis. Urine should be examined for blood/haemoglobin, myoglobin and protein and for microscopic haematuria and red cell casts.

While removing the patients to the nearest medical facility, movements of the bitten limb should be avoided by a splint or sling. Local incisions and suction, vacuum extractors, potassium permanganate and cryotherapy, tourniquets, and compression bands should also be avoided. In cases of elapid envenoming (such as cobra), the pressure immobilization method (firm but not tight bandaging of the entire bitten limb with a crepe bandage 4-5 m long by 10 cm wide starting over the site of the bite and incorporating a splint) may be useful. This method is not warranted in viperid snakebites where local swelling,

necrosis, and coagulopathy are the main venom-induced features (e.g., *M. l. obtusa*).

Patients being transported to the hospital should be laid on their side to prevent aspiration of vomit or excessive salivary secretions. Syncope, shock, angio-oedema and other anaphylactic symptoms are treated with 0.1% adrenaline by subcutaneous injection (0.5 mL for adults, 0.01 mL/kg body weight for children), and an antihistamine such as chlorpheniramine (or diphenhydramine 50 mg) is given by slow intravenous injection (10 mg for adults, 0.2 mg/kg body weight for children). The intravenous route is preferred.

Patients should be admitted to hospital for at least 24 h of observation. The most important medical decision is whether or not to administer antivenom. General indications for antivenom include haemostatic abnormalities such as spontaneous systemic bleeding and profound thrombocytopenia, neurotoxicity, hypotension and shock and/or abnormal ECG, impaired consciousness, and generalized rhabdomyolysis. Local swelling involving more than half the bitten limb, extensive blistering or bruising, bites on digits, and rapid progression of swelling are other indications for antivenom. It is important in the decision process for antivenom administration to consider the prognosis in the absence of antivenom therapy, as a therapeutic goal with antivenom use is to neutralize venom toxins, and prevent the worsening of venom-induced toxicological problems.

Mono-specific (monovalent) antivenom (antivenom containing antibodies against the venom of a single snake species) is ideal for treatment if the biting species is known. However, poly-specific or polyvalent antivenoms (antivenom containing antibodies against the venom toxins of multiple snake species) are generally used and advantageous because identification of the snake responsible for a bite may be difficult and uncertain. Antivenom treatment is indicated as long as signs of systemic envenoming persist; however, it is most effective when given as soon as signs of envenomation appear. Intravenous infusion of antivenom diluted in approximately 5 mL of isotonic fluid/kg body weight allows for a more easily regulated controlled delivery, and it is more safe than intravenous "push" injection of undiluted antivenom. Furthermore, controlled administration of diluted antivenom, usually reduces the risk of adverse allergic reactions.<sup>[18]</sup>

In most countries the dosing of antivenom is empirical. Use of antivenin is usually recommended in patients suffering severe envenomation, but in some patients it's use may cause life-threatening hypersensitivity reactions.<sup>[18]</sup> Marked symptomatic improvement may be seen soon after antivenom infusion has been completed. In patients suffering

shock, the blood pressure may rise and consciousness return. Neurotoxic signs may improve within 30 min, but this usually takes several hours. Spontaneous systemic bleeding usually stops within 15-30 min, and blood coagulability is restored within 6 h of antivenom. More antivenom should be given if severe signs of envenoming persist after 1-2 h or if blood coagulability is not restored within about 6 h. Systemic envenoming may recur hours or days after an initially good response to antivenom. This is explained by continuing redistribution of venom from tissues following its initial distribution, residual venom distributed from the injection site, and the pharmacokinetic differences in venom and antivenom clearance from the blood. Envenomed patients should therefore, be assessed daily for at least 3 or 4 days, and followed with outpatient visits for 2-3 weeks.

Bullae can be aspirated/drained with a fine sterile needle. If signs of necrosis appear, surgical debridement, and broad-spectrum antimicrobial coverage provided. In rare instances split skin grafting may be required. Once specific antivenom has been given, and neutralization of venom procoagulants, restoration of coagulability and platelet function established, fresh whole blood, fresh frozen plasma, cryoprecipitates or platelet concentrates further correct insufficiencies.<sup>[15]</sup>

## CONCLUSION

The majority of snakebites occurring in the urban areas of Kashan are non-venomous. In contrast, patients presenting to clinics bitten in rural areas have a greater probability of suffering from a venomous snakebite. Knowledge of the characteristics, geographic distribution, and environmental habitats of venomous snakes is of value to physicians for rapidly recognizing species potentially responsible for the snakebite in a specific geographic region; thus, allowing for the timely and correct treatment based on identification with respect to the presence or absence of a given snake species in the specific region.

Medical personnel have a significant role, by their permanent presence and medical practice in regions of high snakebite risk. Although they can initiate treatment following a bite, providing knowledge to medical professionals for explaining general information about venomous snakes to the locally native people would potentially decrease the risk of snakebite with consequent reduction in morbidity and mortality associated with venomous snakebite. Education of native people and their children to increase awareness about the possibility of venomous snakes being present where they live, and that the risk of snakebite is greater during the warm months of the year is important. The four venomous viperid species in the Kashan city area of the Isfahan Province (*P. fieldi*, *M. l. obtuse*, *P. persicus*, and

*E. carinatus*) possess venom toxins that may cause severe hematological complications following envenomation.

Finally, general awareness for those who intend to hike or camp in areas known to be inhabited by venomous snake species is a potentially important preventive measure for reducing the risk of a venomous snakebite.

## ACKNOWLEDGMENTS

This study was supported by a grant from the Kashan University of Medical Sciences (Research project No. 9010). Mr Varasteh, Hossein Kha, Abdolloahi, and Geranmaye at the Environmental Health Laboratories and Audiovisual Center at the Kashan University of Medical Sciences contributed to the successful completion of the study. Multiple clinical centers were involved in patient care.

## REFERENCES

1. Farzanpey R. Ophiology. Tehran: Central University. Publications no. 523, biology 13; 1990. p. 1-12. (in Persian, with Latin index).
2. Latifi M. The Snakes of Iran. 3<sup>rd</sup> Persian ed. Tehran: Environment Protection organization; 2000. p. 27-92. (in Persian, with Latin index).
3. Kasturiratne, A., Wickremasinghe, A.R., de Silva, N., Gunawardena, N.K., Pathmeswaran, A., Premaratna, R., Savioli, L., Lalloo, D.G., de Silva, H.J., 2008. Estimating the global burden of snakebite: A literature analysis and modelling based on regional estimates of envenoming and deaths. *PLoS Medicine* 5 (11), e218.
4. Trape JF, Pison G, Guyavarch E, Mane Y. High mortality from snakebite in south-eastern Senegal. *Trans R Soc Trop Med Hyg* 2001;95:420-3.
5. Bawaskar HS, Bawaskar PH. Profile of snakebite envenoming in western Maharashtra, India. *Trans R Soc Trop Med Hyg* 2002;96:79-84.
6. Dehghani R, Rabani D, Panjeh Shahi M, Jazayeri M, Sabahi Bidgoli M. Incidence of snake bites in Kashan, Iran during an Eight-year period (2004-2011). *Archives of Trauma Research* 2012;1:67-71.
7. Zare Mirakabadi A, Teimourzadeh S. Venomous Snakes of Iran, Prevention, First aids and Treatment.: Teimourzadeh and Taieb publication; 2008. p. 31-56. (in Persian, with Latin index).
8. Avicenna H. The Canon of Medicine. Book 5. 2<sup>nd</sup> print. Translated from Arabic into Persian by Abdu l-Rahman Sharaf-Kandi (Hazhar). Sourosh publication; 1988. p. 55-72. (in Persian)
9. Dehghani R. Environmental Toxicology. 1<sup>st</sup> ed.,: Tak Derakhat and of Kashan University of Medical Science Publications; 2010. p. 391-410. (in Persian, with Latin index).
10. Fathinia B, Rastegar-Pouyani N. On the Species of Pseudocerastes (Ophidia: Viperidae) in Iran. *Russian J Herpetology* 2010;17:275-279.
11. Stümpel N, Joger U. Recent advances in phylogeny and taxonomy of near and middle eastern vipers—An update. *ZooKeys* 2009;31:179-91.
12. Fatehi-Hassanabad Z, Fatehi M. Characterisation of some pharmacological effects of the venom from *Vipera lebetina*. *Toxicon* 2004;43:385-91.
13. Bostanchi H, Anderson SC, Kami HG, Papenfuss TJ. A new species of Pseudocerastes with elaborate tailornamentation from western Iran (Squamata: Viperidae). *Proc California Acad Sci* 2006;57:443-50.
14. Gholamifard A, Esmaili HR. First record and range extension of field's horned viper, *pseudocerastes fieldi* schmidt, 1930 (squamata:

- Viperidae), from Fars province, southern Iran. *Turk J Zool* 2010;34:551-2.
15. Pommier P, de Haro L. Envenomation by Montpellier snake (*Malpolon monspessulanus*) with cranial nerve disturbances. *Toxicon* 2007;50:868-9.
  16. Weinstein SA, Warrell DA, White J, Keyler DE. *Venomous Bites from Non-Venomous Snakes: A Critical Analysis of Risk and Management of Colubrid Snake Bites*. Burlington, MA: Elsevier; 2011. p. 30-135.
  17. Warrell DA. Clinical Features of Snake Bite. Retrieved from: [http://www.ilo.org/safework\\_bookshelf/english?content&nd=857170487](http://www.ilo.org/safework_bookshelf/english?content&nd=857170487). Accessed on December 20<sup>th</sup>.
  18. Gawarammana I, Keyler D. Dealing with adverse reactions to snake antivenom. *Ceylon Med J* 2011;56:87-90.

**Source of Support:** Kashan University of Medical Sciences (Research project No. 9010), **Conflict of Interest:** None declared.

Archive of SID