

# A successful treatment of rhinocerebral mucormycosis due to *Rhizopus oryzae*

Rasoul Mohammadi, Mehdi Nazeri<sup>1</sup>, Sayed Mohammad Amin Sayedayn<sup>2</sup>, Hassan Ehteram<sup>3</sup>

Department of Medical Parasitology and Mycology, Faculty of Medicine, Isfahan University of Medical Sciences, Isfahan, <sup>1</sup>Department of Parasitology, <sup>3</sup>Department of Pathology, School of Medicine, Kashan University of Medical Sciences, Kashan, <sup>2</sup>General Practitioner, Isfahan University of Medical Sciences, Isfahan, Iran

Mucormycosis is an invasive fungal infection caused by filamentous fungi of the Mucoraceae family. The genera most commonly responsible are *Mucor* or *Rhizopus*. The disease occurs mostly in association with diabetic ketoacidosis. Mucormycosis has an extremely high death rate even when aggressive surgery is done. Death rates range from 25-85% depending on the body area involved. A case of rhinocerebral mucormycosis in a 65-year-old diabetic male patient typically presenting as headache, especially in parietal and frontal lobes, with nose and left eye discharge. After clinical and laboratory examination, mucormycosis was diagnosed, and *Rhizopus oryzae* was isolated. Systemic therapy with amphotericin B administered intravenously then replaced by posaconazole by a combination of aggressive surgery. The patient was treated and followed up for one year. We emphasize the importance of early detection and aggressive treatment in the management of this fatal disease.

**Key words:** Diabetes, *Rhizopus oryzae*, rhinocerebral mucormycosis

**How to cite this article:** Mohammadi R, Nazeri M, Sayedayn SM, Ehteram H. A successful treatment of rhinocerebral mucormycosis due to *Rhizopus oryzae*. J Res Med Sci 2014;19:72-4.

## INTRODUCTION

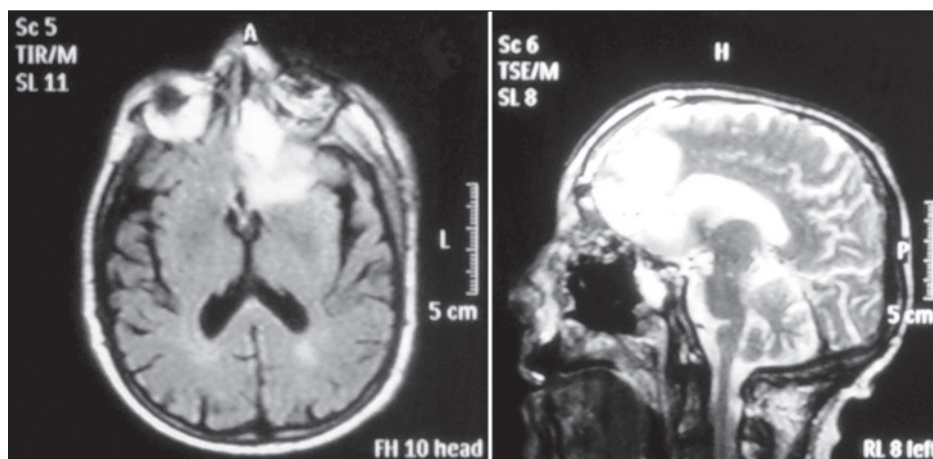
Mucormycosis is a rare and potentially lethal infection. It is caused by one of the members of the Mucoraceae family, including the *Absidia*, *Mucor*, and *Rhizopus* which may be found in decaying food, in the soil, or other organic matter, such as animal excreta.<sup>[1]</sup> They have the ability to rapidly grow and release large numbers of spores that become airborne and gain entrance to the human body through inhalation or ingestion. However, it rarely causes an infection in one with an intact immune system which can phagocytize the spores.<sup>[2]</sup> Rhinocerebral mucormycosis is associated with immunocompromised patient state, hemochromatosis, desferrioxamine therapy, malignancy, diabetes mellitus with or without ketoacidosis, organ transplantation, severe burns, trauma and prolonged corticosteroid therapy.<sup>[3]</sup> Because rhinocerebral mucormycosis occurs infrequently it may pose a diagnostic and therapeutic problems for those who are not familiar with its clinical presentation. Early clinical recognition of this potentially fatal disease followed by aggressive debridement, systemic antifungal therapy, and control of underlying co-morbid factors is the mainstay of therapy.<sup>[4]</sup> In this presentation we report a rhinocerebral mucormycosis in a diabetic male he was treated after appropriate therapy.

## CASE REPORT

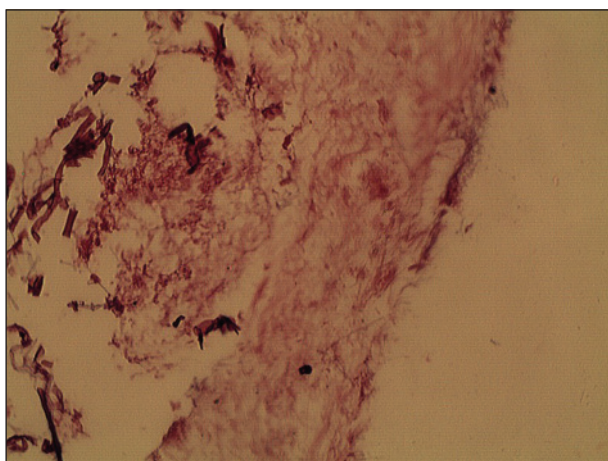
A 65-year-old man with diabetes mellitus type 2 typically had headache (especially in parietal and frontal lobes), nose and the left eye discharge, was admitted in 2012 in Al-Zahara hospital in Isfahan, Iran. He had a fifteen-year's history of diabetes, hypertension, hyperlipoproteinemia, and kidneys dysfunction. He suffered from nightly headache even was not healed with opioid drugs such as morphine and methadone. Each episode of headache has been survived about four hours accompanied by nose and eye discharge. There was no fever, nausea, vomiting, dizziness, diplopia, blurred vision, and memory dysfunction. Proptosis of the left orbit occurred. Brain MRI found the left ethmoidal and maxillary sinusitis and subperiosteal abscess in left orbit. There was a signal change in the left frontal lobe as high signal intensity on T2 FLAIR with edema and minimal mass effect [Figure 1]. Endoscopy of the nose and paranasal sinuses was performed and sampling from tissue and discharges was done and then transferred to the clinical laboratory. Both culture results and the characteristic hyphae in sections [Figure 2] confirmed mucormycosis. The isolate was identified as *Rhizopus oryzae* by sequence analysis (Gene Bank accession number is KF228585). The patient was transferred to the Department of Otolaryngology (ENT)

**Address for correspondence:** Dr. Rasoul Mohammadi, Department of Medical Mycology and Parasitology, Isfahan Medical School, Isfahan University of Medical Sciences, Isfahan, Iran. E-mail: Dr.rasoul\_mohammadi@yahoo.com

**Received:** 02-07-2013; **Revised:** 15-08-2013; **Accepted:** 04-09-2013



**Figure 1:** The brain MRI study with sagittal and coronal plane. There is a signal change in the left frontal lobe as high signal intensity on T2 FLAIR with edema and minimal mass effect, asymmetry of the left orbit compared to the right side. Small vessel ischemia and maxillo-ethmoidal sinusitis are noticed



**Figure 2:** Broad and aseptate hyphae in necrotic tissue (H and E stain,  $\times 40$ )

and amphotericin B (50 mg/day) was prescribed for him, and debridement of sphenoid sinus walls was performed. Because of renal failure of the patient, drug regimen changed to posaconazole (PCZ)(5 mg/kg). After 20 days, headache recommenced and brain MRI showed invasion to the frontal lobe. He was nominated for craniotomy surgery and finally enucleation of the left eye was accomplished. At last, after revision of paranasal sinuses for assurance of eradication of the disease, the patient was released from hospital with drug regimen of posaconazole (5 mg/kg) for two weeks. We followed up him for one year and he is still alive.

## DISCUSSION

Mucormycosis is primarily a disease of subjects with altered host defenses associated with the underlying conditions and predisposing factors such as diabetes mellitus, hematologic malignancies, chemotherapy, corticosteroid therapy, organ transplantation, and so on. Diabetic patients are predisposed to mucormycosis because of the decreased ability of their neutrophils to phagocytize and adhere to

endothelial walls. High blood sugar level may also alter the ability of macrophages.<sup>[9]</sup> Rhizopus, Mucor, Absidia are the most common isolated from patients with mucormycosis. Rhizopus is responsible for about 90% of rhinocerebral mucormycosis as seen in our study. We reconfirmed our results using the sequence analysis (Gene Bank accession number is KF228585). The first case of mucormycosis was described in 1885 by Paltauf, who created the term mycosis mucorina.<sup>[6]</sup> Infection occurs following inhalation of spores of Mucorales into the oral and nasal mucosa. Their germination is preferred by low oxygen, high glucose, acidic medium and high iron levels.<sup>[7]</sup> In rhinocerebral mucormycosis, generally the infection starts in the nasal tissues and spreads by direct extension into the paranasal sinuses and then to the orbit. As seen in our case, the diabetic patient with poor controlled blood sugar who developed rhinocerebral mucormycosis typically presented with headache, nose and left eye discharge, edema, unilateral proptosis of left orbit. Because the disease provokes the diffuse tissue necrosis, the fungi can easily invade the wall of blood vessels, leading to thrombosis and tissue ischemia.<sup>[8]</sup> Imaging studies like Magnetic resonance imaging (MRI) are important to evaluate the extent of the disease. MRI can demonstrate soft tissue lesions better than CT scan, especially in diagnosis of cavernous sinus thrombosis. When the orbit is invaded, increased density of the orbital fat and venous gulping may be seen, similar to our case patient. In this patient, the infection began in the paranasal sinuses and progressed to the orbit and the brain. Definitive diagnosis requires identification of the fungus histologically in tissue specimens or recovery of the fungus by culture. Mucorales appear as irregularly shaped, broad (10-50  $\mu\text{m}$ ), aseptate hyphae with right-angle branching.<sup>[9]</sup> Treatment of rhinocerebral mucormycosis should consist of prompt control of hyperglycemia and ketoacidosis, aggressive surgical debridement of involved tissue, and administration of parenteral amphotericin B.<sup>[10]</sup> Renal functions are monitored to document the amphotericin B

induced nephrotoxicity. This monitoring helped us to replace posaconazole instead of amphotericin B because of our patient's renal failure. Aggressive surgical debridement of all necrotic tissue until normal well-perfused bleeding tissue is ideal. Orbital evisceration is advised if ophthalmoplegia and loss of vision has occurred, so that we did.

## ACKNOWLEDGEMENT

We appreciate from Isfahan and Kashan University of Medical Sciences and Shafa Laboratory (Isfahan) personnel collaborated with us in this study.

## REFERENCES

1. Kwon-Chung KJ. Taxonomy of Fungi Causing Mucormycosis and Entomophthoromycosis (Zygomycosis) and Nomenclature of the Disease: Molecular Mycologic Perspectives. *Clin Infect Dis* 2012;54:S8-15.
2. Casqueiro J, Casqueiro J, Alves C. Infections in patients with diabetes mellitus: A review of pathogenesis. *Indian J Endocrinol Metab* 2012;16:S27-36.
3. Prabhu Rm, Patel R. Mucormycosis and entomophthoromycosis: A review of the clinical manifestations, diagnosis and treatment. *Clin Microbiol Infect* 2004;10:31-47.
4. Onyango JF, Kayima JK, Owen WO. Rhinocerebral mucormycosis: Case report. *East Afr Med J* 2002;79:390-3.
5. Peleg AY, Weerathna T, McCarthy JS, Davis TM. Common infections in diabetes: Pathogenesis, management and relationship to glycaemic control. *Diabetes Metab Res Rev* 2007;23:3-13.
6. Ammari L, Kilani B, Tiouiri H, Kanoun F, Goubontini A, Mnif E, *et al.* Mucormycosis: Four case reports. *La Tunis Med* 2008;86:165-8.
7. Alan MS. Mucormycosis. *Clin Infect Dis* 1992;14:126-9.
8. Artal R, Agreda B, Serrano E, Alfonso JI, Vallés H. Rhinocerebral mucormycosis: Report on eight cases. *Acta Otorrinolaringol Esp* 2010;61:301-5.
9. Spellberg B, Walsh TJ, Kontoyiannis DP, Edwards J Jr, Ibrahim AS. Recent advances in the management of mucormycosis: From bench to bedside. *Clin Infect Dis* 2009;48:1743-51.
10. Kok J, Gilroy N, Halliday C, Lee OC, Novakovic D, Kevin P, *et al.* Early use of posaconazole in the successful treatment of rhino-orbital mucormycosis caused by *Rhizopus oryzae*. *J Infect* 2007;55:e33-6.

Source of Support: Nil. Conflict of Interest: None declared.

Archive of SID