

Amyand's hernia in a neonate: A case report

Xiao-Feng Sun, Dian-Bo Cao¹, Ting Zhang, Ying-Qiao Zhu

Departments of Ultrasonics, ¹Department of Radiology, The First Hospital of Jilin University, Changchun, China

Acute appendicitis secondary to hernia incarceration presenting as scrotal swelling is exceptionally rare in neonates. We report a neonate who presented with tender swelling in the right scrotum. Ultrasonography detected features of a rare Amyand's hernia. Surgical exploration and histopathological examination confirmed the diagnosis.

Key words: Amyand's hernia, appendicitis, neonate, scrotal swelling, ultrasonography

How to cite this article: Sun XF, Cao DB, Zhang T, Zhu YQ. Amyand's hernia in a neonate: A case report. *J Res Med Sci* 2014;19:193-5.

INTRODUCTION

Amyand's hernia is a rare presentation of acute appendicitis, in which an incarcerated or perforated appendix is found in the right inguinal canal.^[1] The incidence ranges from 0.07% to 0.13% of all cases of appendicitis.^[2] Pain in the inguinal region or in the flank is the most common presentation.^[3] It is seldom diagnosed preoperatively due to its unusual and infrequent clinical presentation.^[4] Only a few cases have been diagnosed either by computed tomography (CT) or ultrasonography^[5] before operation. We report a 24-day-old neonate who presented atypically with tender swelling in the right scrotum. Ultrasonography findings suggested Amyand's hernia preoperatively, which was confirmed by histopathological examination following surgery.

CASE REPORT

A 24-day-old male neonate presented at the Department of Pediatric Surgery of The First Hospital of Jilin University in Changchun, China with right scrotal swelling for 4 days. There was no history of fever, vomiting, abdominal distension, or diarrhea. Local examination revealed a firm, tender swelling of 3.0 × 2.0 × 2.0 cm in the right inguinal region extending into the scrotum. The skin over the swelling was red and there was no fluctuation. The left scrotum and testis were normal. The neonate's total leukocyte count was increased (11.9 × 10⁹/L). Ultrasonography detected a colon-type echo in the right inguinal canal [Figure 1] measuring 30.0 × 5.0 mm. The wall of the colon-type structure measured 3.5 mm in diameter and was thickened. There were

moving hyperechoes in the lumen. The right testis measured 9.9 × 5.2 mm with an anechoic region of 7.0 × 12.0 mm anterior to the right testis [Figure 2]. The left testis was 8.3 × 4.1 mm without any abnormalities. An ultrasonic diagnosis of right inguinal hernia and right encapsulated hydrocele of the tunica vaginalis was considered.

Since the patient's presentation was not typical of a hernia, a primary clinical diagnosis of testicular tumor or epididymitis was considered. Because the neonate was considered to have epididymitis, he was started on antibiotics for 2 days. The tenderness subsided, but the right testicular swelling reduced minimally. Repeat ultrasonography showed similar features as before, including right inguinal hernia and encysted hydrocele in the right scrotum.

The neonate underwent surgical exploration after the second ultrasonic examination. Surgical exploration revealed swollen tunica vaginalis of the right testis. In addition, the tunica vaginalis, right testis and epididymis were found to be hyperemic and swollen with discharge of purulent material. The tunica vaginalis also contained a colon-type structure adhering to the swollen and inflamed right testis and epididymis. This colon-type structure extended into the right inguinal region and was identified as the appendix. An appendectomy was performed through the inguinal incision alone, and the right hernia sac was ligated.

Histopathological examination of the appendix specimen revealed fibrous tissue hyperplasia in the interstitium, with acute and chronic inflammatory cell

Address for correspondence: Dr. Ying-Qiao Zhu, Departments of Ultrasonics, The First Hospital of Jilin University, Changchun - 130 021, China.
E-mail: zhuyingqiaozyq@163.com

Received: 25-01-2013; **Revised:** 26-05-2013; **Accepted:** 31-07-2013

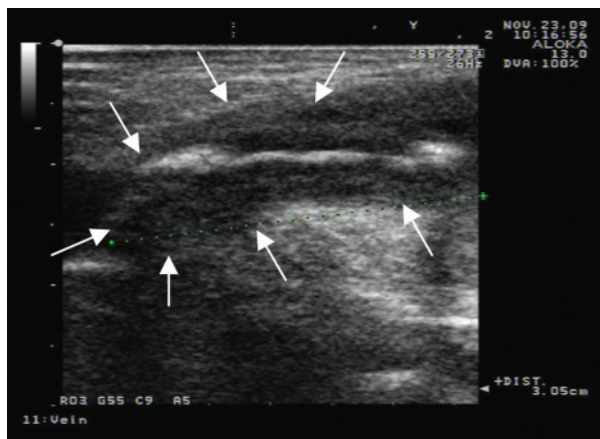


Figure 1: Longitudinal ultrasonography view of the incarcerated appendix (arrows)

infiltration, vasodilatation, and congestion. This confirmed the diagnosis of appendicitis. The post-operative period was uneventful. An ultrasonography scan 1 week later revealed a normal scrotum and testes on both sides, and the patient was discharged from the hospital.

DISCUSSION

Amyand's hernia presenting as scrotal swelling without any other symptoms is extremely rare. There have been fewer than 200 cases of Amyand's hernia in the literature; however, only two cases have presented as scrotal swelling.^[6,7] Most cases of Amyand's appendicitis occur in the inguinal canal or abdominal wall. Although acute scrotum is a common clinical presentation of torsion of the testis or its appendages and epididymo-orchitis, incarcerated hernia and scrotal and/or inguinal abscess should also be considered in the differential diagnosis. Clinical presentations of torsion caused by undescended testes may be quite similar to those observed in Amyand's hernia.^[8] Ultrasonography is useful in distinguishing torsion of undescended testes from Amyand's hernia because of its high efficiency, low exposure, and real-time properties.

Ultrasonography exhibits several advantages in differentiating Amyand's hernia and other acute scrotum conditions. First, ultrasonography can characterize hernias and differentiate hernias from other structures. Ultrasonography can detect hernias with sacculations and moving content of the colon. In this case, ultrasonography detected a soft tissue structure similar to a thick wall of the colon without sacculations, and the hernia contained an isolated soft tissue with a thick wall and moving contents in the inguinal canal. Additionally, the cecum was superior to the testes. Second, ultrasonography, due to its real-time monitoring, can identify the moving content in the intestine. Third, ultrasonography can recognize normal testes and

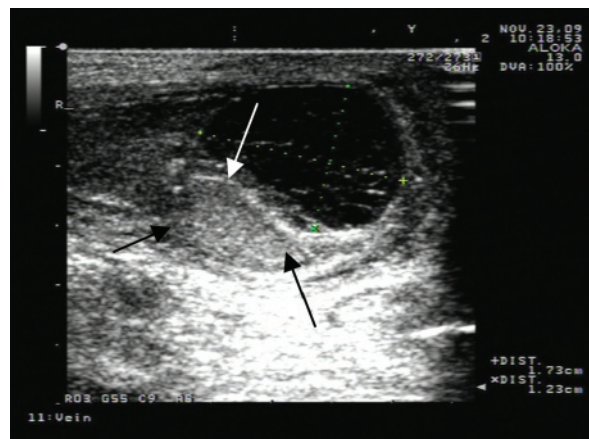


Figure 2: Ultrasonogram demonstrates the right testis (arrows) and hydrocele of the right testis

epididymides. Testicular tumors and epididymitis can be reasonably excluded even though these conditions have similar symptoms. In the present case, ultrasonography identified an inflamed appendix and encapsulated fluid around the right testis that was confirmed by surgery as transudate due to appendicitis.

In this case, a neonate presented with right scrotal swelling without any signs of peritonitis. This was most likely because inflammatory transudate surrounded only the testis, and thus irritated the testis and its surrounding tissues. Since the appendix, rather than the colon, was incarcerated in the inguinal canal, symptoms of intestinal rhythm alteration were not present. Therefore, the patient presentation was misleading. Ultrasonography helped diagnose the condition more accurately. Specifically, ultrasonography revealed the presence of an echogenic intestinal canal in the right inguinal canal and encapsulated hydrocele of the tunica vaginalis. In conclusion, we would like to highlight that ultrasonography might be a valuable tool in the preoperative diagnosis of Amyand's hernia.

REFERENCES

1. Tycast JF, Kumpf AL, Schwartz TL, Coln CE. Amyand's hernia: A case report describing laparoscopic repair in a pediatric patient. *J Pediatr Surg* 2008;43:2112-4.
2. Sharma H, Gupta A, Shekhawat NS, Memon B, Memon MA. Amyand's hernia: A report of 18 consecutive patients over a 15-year period. *Hernia* 2007;11:31-5.
3. Priego P, Lobo E, Moreno I, Sánchez-Picot, Sánchez-Picot S, Gil Olarte MA, et al. Acute appendicitis in an incarcerated crural hernia: Analysis of our experience. *Rev Esp Enferm Dig* 2005;97:707-15.
4. D'Alia C, Lo Schiavo MG, Tonante A, Taranto F, Gagliano E, Bonanno L, et al. Amyand's hernia: case report and review of the literature. *Hernia* 2003;7:89-91.
5. Coulier B, Pacary J, Broze B. Sonographic Diagnosis of Appendicitis within a Right Inguinal Hernia (Amyand's Hernia). *J Clin Ultrasound* 2006;34:454-7.

6. Armas Alvarez AL, Taboada Santomil P, Pradillos Serna JM, Rivera Chávez LL, Estévez Martínez E, Méndez Gallart R, *et al.* Infantile Amyand's hernia presenting as acute scrotum. *Cir Pediatr* 2010;23:250-2.
7. Juan YH, Ko KH, Chen YL, Liu CH, Yu CY, Chang WC, *et al.* Amyand's hernia with scrotal abscess presenting as acute scrotum. *J Chin Med Assoc* 2013;76:57-9.
8. Kumar R, Mahajan JK, Rao KL. Perforated appendix in hernial sac mimicking torsion of undescended testis in a neonate. *J Pediatr Surg* 2008;43:9-10.

Source of Support: Nil, **Conflict of Interest:** None declared.

Archive of SID