

Bronchial stump closure with amniotic membrane in animal model

Gholamreza Mohajeri, Mohammad Omid, Hamid Melali, Mitra Heidarpour¹, Amir Hosein Davarpanah Jazi²

Departments of Thoracic Surgery and ¹Pathology, ²Medical Education Research Center, Isfahan University of Medical Sciences, Isfahan, Iran

Background: Coverage of the bronchial stumps (BSs) with adjacent tissues can improve healing and reduce bronchial complications in complex thoracic surgery. There is no evidence for the application of human amnion allograft for prevention of air leak from the BS. The comparison of the amniotic membrane (AM) and pleural patch for BS healing after lobectomy in dogs was our aim in this study. **Materials and Methods:** A total of eight males and females 12-24-month-old dogs between 17 and 22 kg body-weight were used in this study in 2010, Isfahan University of Medical Sciences. Animals were separated into two groups: group A ($n = 4$; amniotic membrane) and group P ($n = 4$; pleural patch) according to the BS closure technique performed. After lobectomy of the right middle lobe, the BS was closed, while a small bronchopleural fistula (BPF) was created by inserting a catheter via edges of closed stump. Then, it was covered with a piece of AM 3×3 cm in group A and with a pedicle graft of pleura in group P. Rethoracotomy was performed after 15 days of observation, and the BS was removed for histological examination. Histological healing was classified as complete or incomplete healing. Neoangiogenesis was measured by Von Willebrand expression using immunohistochemistry (IHC). Data were analyzed by SPSS version 15 using Fisher's exact test, Mann-Whitney test, and T tests. **Results:** BPF complications were not seen during observation period. There was no significant difference in histological healing between two groups. Similarly, no significant difference was observed between the groups in terms of neoangiogenesis based on IHC examination (P value = 0.69). **Conclusion:** Human amnion allograft could be as effective as pleural patch for BS wrapping following pulmonary resections.

Key words: Amniotic membrane, bronchial stump, bronchopleural fistula, pneumonectomy

How to cite this article: Mohajeri G, Omid M, Melali H, Heidarpour M, Davarpanah Jazi AH. Bronchial stump closure with amniotic membrane in animal model. *J Res Med Sci* 2014;19:211-4.

INTRODUCTION

Bronchopleural fistula (BPF) is an important complication after lung surgery, following failure of the bronchial stump (BS) to heal. This failure to heal may be from improper initial closure, inadequate blood supply, infection at the BS, or residual malignant tumor at the BS. The incidence of BPF varies from 0% to 12%.^[1] Right-sided resection, pneumonectomy (especially, right pneumonectomy), mediastinal lymph node resection, high dose preoperative radiation therapy, and residual or recurrent carcinoma at the BS as technical factors are predisposing to BPF in patients undergoing pulmonary resections for lung cancers. Other risk factors are diabetes, hypoalbuminemia, using corticosteroid^[2] and more than 24 h ventilation after pneumonectomy.^[3] For prevention of BPF; BS is covered with adjacent tissues like intercostal muscle,^[4] pericardial fat,^[5] diaphragm,^[6] pericardial flap,^[7] azygous vein, pleura, and omentum.^[8]

Some surgeons suggest using of muscle flap in high-risk patients for supporting BS. Latissimus dorsi,

pectoralis major, and serratus anterior are used for this purpose.^[9]

Release of pulmonary adhesions in repeated thoracotomy can damage visceral pleura and pulmonary parenchyma and cause air leak subsequently. Some researchers consider using of amnion allograft as a biological cover on the site of damage for controlling air leak.^[10]

As we know there isn't any report about using amniotic membrane (AM) for covering and supporting BS. In this study, we compare the effect of AM and pleura on BS healing.

MATERIALS AND METHODS

A total of eight males and females 12-24-month-old dogs between 17 and 22 kg body-weight were used in this study during 2011-2012 in Isfahan University of Medical Sciences (project number: 389398). Fasting time before surgery was 12 h. Preanesthesia was done with intramuscular injecting of Acepromazine maleate (0/5 mg/kg) and ketamine hydrochloride (5 mg/kg).

Address for correspondence: Dr. Mohammad Omid, Department of Surgery, Al Zahra Hospital, Soffeh St, Isfahan, Iran. E-mail: omid@mail.mui.ac.ir

Received: 12-04-2013; **Revised:** 27-11-2013; **Accepted:** 01-01-2014

The dogs were anesthetized and continued with halothane 1% after the administration of thiopental Na [15 mg/kg intravenous (IV)]. Respiration was ensured by mechanical ventilation (15 mL/kg tidal volume, respiration rate 15/min, and 25 cm H₂O alveolar pressure).

Animals were separated into two groups: group A ($n = 4$) and group P ($n = 4$). In both groups, right thoracotomy via fourth intercostal space and lobectomy of middle lobe was done. A sterile catheter with 3 mm diameter was inserted into the BS and the end of the BS was sutured with a simple interrupted suture pattern using 3-0 vicryl and then the catheter was removed in order to creation of BPF. Then, the BS and fistula was covered with a piece of human AM (3×3 cm) in group A and with a pedicle graft of parietal pleura in group P. This additional layer was fixed around the BS with simple interrupted sutures using 5-0 vicryl. Then, the pleural space was filled with warm sterile saline. The BS was evaluated after applying 20 cm H₂O endobronchial pressure and if air leakage was present, extrasimple sutures using 5-0 vicryl was applied to control it. Saline was aspirated and a 28-French thoracostomy tube was inserted into the pleural cavity. The tube was fixed to the skin and a one-way handmade valve (made by tying a Penrose drain around the chest tube) was connected to the tube for pleural drainage. Carprofen (5 mg/kg/d SC) was used for analgesia and Cefazoline (20 mg/kg IV tid) was used for 5 days. Tube thoracostomy was removed 5 days after operation under anesthesia with IM Ketamin injection. Postoperative care was carried out in compliance with The Ethical Principles for Animal Experiments of the International council for Animal Protection.

The dogs were observed for 15 days and then rethoracotomy was done, and BS was removed in all subjects, and remained stump were closed by 5-0 vicryl interrupted sutures. Post operative care was similar to the first operation. The BS was fixed in formalin 10% and embedded in paraffin. Five micrometer thick sections from these samples were placed on slides and stained with hematoxylin and eosin for microscopic examination. Histological healing was classified as complete or incomplete healing. Granulation tissue formation, and new vessel formation with phagocytosis of suture material, was indicating to complete healing. Incomplete healing was marked when sever neutrophil infiltration or purulent bronchitis was seen.^[11] Neoangiogenesis was measured by Von Willebrand expression.^[12] In each samples, number of the capillaries in five high magnification fields as counted and the mean of these was considered as the count of capillaries in each samples.

AM used in this study was taken from Imam Musa Kazem hospital of Isfahan. In this hospital, human AM was prepared and used for burned patient. In mentioned hospital, AM was being achieved in a sterile manner from

pregnant women that had no history of contagious disease after cesarean section. The placenta was being put in a pail containing normal saline and gentamicine (80 mg/L). AM was being isolated from chorion, cleaned, and put in normal saline solution contained gentamicine (80 mg/L) again. It was being preserved in 4°C.

All data were analyzed by SPSS version 15 using Fisher's exact test, Mann-Whitney test, and T-test. *P* values less than 0.05 considered statistically significant.

RESULTS

Histological examinations revealed complete healing in all BSs in group A. Granulation tissue formation with new vessel formations as well as continued phagocytosis of the suture material was seen around them. There was no evidence of necrosis and abscess and neutrophil infiltration [Figure 1].

Also in all cases of group P, bronchial stamp healing was complete. So in both groups, healing state was the same and Fisher's exact test showed no difference.

BPF did not occur in none of groups.

The mean of micro vessel count based on immunohistochemistry (IHC) for Von Willebrand expression in each high magnification field was 18.5 (2.9) in group A and 19 (1.4) in group P [Table 1].

The independent T-test showed that the mean of vessel count of two groups did not have significant difference (*P* value = 0.77).

DISCUSSION

Our result showed no significant difference in histological healing between two groups. Similarly, no significant

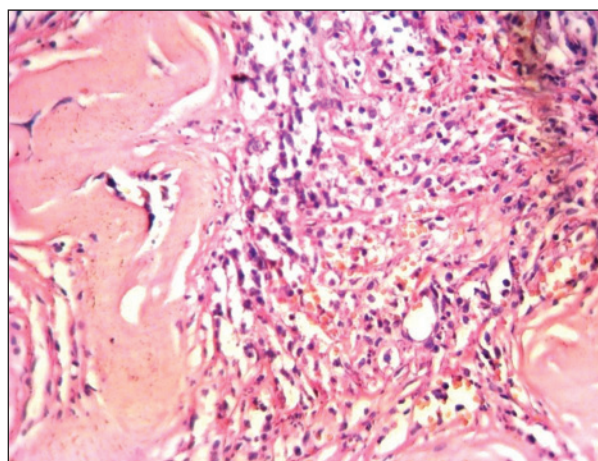


Figure 1: Histology of bronchial stump in group A after surgery (x400)

Table 1: The count of the microvessel in both groups based on expression of Von Willebrand expression on immunohistochemistry

Group	Microvessel count			
	Mean	SD	Minimum	Maximum
Group A	18.5	2.9	15	20
Group P	19	1.4	17	22

difference was observed between the groups in terms of neoangiogenesis based on IHC.

Wrapping the bronchial suture line or BSs to protect and revascularize these structures is gaining wide acceptance.^[8]

Surgeons have used different tissues to cover BS such as pleura, omentum, azygous vein, pericardial flap, intercostal muscle, latissimus dorsi, pectoralis major, serratus anterior flap, pericardial fat, and diaphragm.^[9]

But to the best of our knowledge, there is no evidence for the application of human amnion allograft for this purpose. Although its use for prevention and treatment of the air leak from pulmonary parenchyma after metastasectomy and after releasing of pulmonary adhesions in rethoracotomies has been reported.^[10] In their study, the researchers have applied deep-frozen and radiation sterilized human amnion as a biological dressing, on damaged pulmonary parenchyma and has reported that it has been a safe and effective method in preventing postsurgical air leak in thoracic surgery.^[10]

AM has some exclusive properties that make it very attractive for tissue engineering (TE). Epithelial cells derived from the AM have the advantages of stem cells, yet are a more suitable source of cells for TE than stem cells. The extracellular matrix components of the basement membrane of the AM create an almost native scaffold for cell seeding in TE. In addition, the AM has other biological properties important for TE, including anti-inflammatory, antimicrobial, antifibrosis, antiscarring, as well as reasonable mechanical property and low immunogenicity.^[13]

AM has been used in several clinical practices such as treatment of deep ulceration of the cornea or sclera, treatment of burn injuries, varicose ulcers, decubitus ulcers, open ulcers, infected wounds, tympanic membrane grafts, management of severe epistaxis, replacing the nasal mucosa in Rendu-Osler-Weber disease and reconstruction of the vagina, and ureter.^[10]

In this study, we have compared the effect of AM and pleura on BS healing and have concluded that there is no significant difference between them in terms of BS healing, BPF incidence, and amount of angiogenesis. The most important advantage of AM utilizing is that releasing

and preparing the adjacent tissues for BS wrapping can cause some complications in addition to wasting the time. For example, using the intercostal muscle flap cause increased bleeding and postoperative pain in comparison to usual pneumonectomy.^[14] Diaphragmatic flap may cause diaphragmatic hernia.^[6] In addition to pericarditis, pericardial flap can cause tamponade especially, if the flap was large and consequent reconstruction was tightening.^[15] Furthermore in advance malignancies, pericardial and pleural involvement is probable, so they cannot be suitable choices for BS wrapping consequently.

CONCLUSION

AM can be effective in BS healing and prevention of the BPF.

REFERENCES

1. Klepetko W, Taghavi S, Pereszlenyi A, Birsan T, Groetzner J, Kupilik N, *et al.* Impact of different coverage techniques on incidence of postpneumonectomy stump fistula. *Eur J Cardiothorac Surg* 1999;15:758-63.
2. Asamura H, Naruke T, Tsuchiya R, Goya T, Kondo H, Suemasu K. Bronchopleural fistulas associated with lung cancer operations: Univariate and multivariate analysis of risk factors, management, and outcome. *J Thorac Cardiovasc Surg* 1992;104:1456-64.
3. Javadpour H, Sidhu P, Luke DA. Bronchopleural fistula after pneumonectomy. *Ir J Med Sci* 2003;172:13-5.
4. Sonett JR, Suntharalingam M, Edelman MJ, Patel AB, Gamliel Z, Doyle A, *et al.* Pulmonary resection after curative intent radiotherapy (>59 Gy) and concurrent chemotherapy in non-small-cell lung cancer. *Ann Thorac Surg* 2004;78:1200-5.
5. Ichinose Y, Asoh H, Yano T, Yokoyama H, Inoue T, Tayama K, *et al.* Use of a pericardial fat pad flap for preventing bronchopleural fistula: An experimental study focusing on the angiogenesis and cytokine production of the fat pad. *Surg Today* 1995;25:811-5.
6. Lardinio D, Horsch A, Krueger T, Dusmet M, Ris HB. Mediastinal reinforcement after induction therapy and pneumonectomy: Comparison of intercostal muscle versus diaphragm flaps. *Eur J Cardiothorac Surg* 2002;21:74-8.
7. Taghavi S, Marta GM, Lang G, Seebacher G, Winkler G, Schmid K, *et al.* Bronchial stump coverage with a pedicled pericardial flap: An effective method for prevention of postpneumonectomy bronchopleural fistula. *Ann Thorac Surg* 2005;79:284-8.
8. Zonüzi F, Ercan S. Comparison of the omentum, pleura and diaphragm for tracheal autograft neovascularization in rats. *Turk Respir J* 2000;1:60-2.
9. Fell SC, DeCamp MM. Technical Aspects of Lobectomy. In: Shields TW, Locicero J, Reed CE, Feins RH. *General Thoracic Surgery*. 17th edition. Philadelphia. Williams Lippincott & Wilkins. 2009:430-5.
10. Żmijewski M, Pietraszek A. The application of deep-frozen and radiation-sterilized human amnion as a biological dressing to prevent prolonged air leakage in thoracic surgery. *Ann Transplant* 2005;10:17-20.
11. Salci H, Bayram AS, Ozyigit O, Gebitekin C, Gorgul OS. Comparison of different bronchial closure techniques following pneumonectomy in dogs. *J Vet Sci* 2007;8:393-9.
12. Carbognani P, Corradi A, Bobbio A, Cantoni AM, Mazzei M, Pazzini L, *et al.* Histological and immunohistochemical study of the bronchial stump with flap coverage in an animal model. *Eur Surg Res* 2003;35:54-7.

13. Toda A, Okabe M, Yoshida T, Nikaïdo T. The potential of amniotic membrane/amnion-derived cells for regeneration of various tissues. *J Pharmacol Sci* 2007;105:215-28.
14. Maniwa T, Saito Y, Kaneda H, Imamura H. Bronchial stump reinforcement with the intercostal muscle flap without adverse effects. *Eur J Cardiothorac Surg* 2006;30:652-6.
15. Yamamoto R, Inoue K, Hori T, Takehara S, Kaji M, Kinoshita H. Intercostal muscle pedicle flap for prophylaxis against bronchopleural fistula after pulmonary resection. *Osaka City Med J* 1994;40:99-105.

Source of Support: Nil, **Conflict of Interest:** None declared.

Archive of SID