

Comparison of postoperative bleeding between submucosal uvulopalatopharyngoplasty and tonsillectomy

Elif Ayanoglu Aksoy, Gediz Murat Serin, Senol Polat, Ömer Faruk Ünal, Hasan Tanyeri

Department of Otorhinolaryngology, Acibadem University, Faculty of Medicine, Istanbul, Turkey

Background: The aim of this study was to compare the incidence of postoperative secondary hemorrhage for tonsillectomy and submucosal uvulopalatopharyngoplasty (smUPPP). **Materials and Methods:** In this retrospective case series, the medical records of 404 patients who underwent tonsillectomy with unipolar electrocautery and smUPPP at our institution between January 2001 and December 2010 were reviewed. The patients were divided into two groups: Group 1 (198 patients) underwent tonsillectomy; Group 2 (206 patients) underwent smUPPP. Main outcome measures were incidence of bleeding or complications after tonsillectomy and smUPPP and the need for revision surgery. **Results:** The mean age of Group 1 patients was 38.1 (± 2.58) years and that of Group 2 was 37.7 (± 2.25) years. Males were 51.3% of Group 1 and 46.7% of Group 2. No statistically significant difference in age or gender distribution was found between Groups 1 and 2. The incidence of secondary, delayed hemorrhage was 5.05% (10 patients) in Group 1 and 1.45% (three patients) in Group 2 ($P = 0.05$). The incidence of delayed hemorrhage requiring surgical treatment was 4.54% (nine patients) in Group 1 and 0.97% (two patients) in Group 2. **Conclusion:** In adults, smUPPP, which includes tonsillectomy, has a lower incidence of postoperative delayed hemorrhage than does tonsillectomy with unipolar cautery.

Key words: Postoperative bleeding, smUPPP, tonsillectomy

How to cite this article: Aksoy EA, Serin GM, Polat S, Ünal ÖF, Tanyeri H. Comparison of postoperative bleeding between submucosal uvulopalatopharyngoplasty and tonsillectomy. J Res Med Sci 2014;19:310-3.

INTRODUCTION

Tonsillectomy is a commonly performed procedure. Although perioperative mortality from tonsillectomy and submucosal uvulopalatopharyngoplasty (smUPPP) with tonsillectomy has decreased significantly, postoperative bleeding is still an important complication. The incidence of bleeding after tonsillectomy is approximately 0.5%-10%, with death occurring in 1 in 20,000 patients.^[1-2] Primary bleeding refers to that occurring within the first 24 h postoperatively, and bleeding occurring 5-10 days after surgery has been classified as secondary or delayed bleeding.^[3] Factors such as age, gender, and surgical technique have been evaluated as risk factors for posttonsillectomy bleeding.^[4-8] To date, no study has specifically compared the rate of bleeding after tonsillectomy and smUPPP. We reviewed the medical records of all patients at our institution who underwent unipolar cautery tonsillectomy alone or in conjunction with smUPPP during the last 10 years to compare the incidence of secondary, delayed postoperative hemorrhage between the two procedures.

PATIENTS AND METHODS

In this retrospective study, following approval from the institutional review board, we reviewed the medical records of 404 patients who underwent tonsillectomy and smUPPP procedures at our institution between January 2001 and December 2010. The patients were divided into two groups according to the surgical intervention they had gone through. Group 1, who underwent tonsillectomy, consisted of 198 patients; Group 2, who underwent smUPPP, consisted of 206 patients.

Patients younger than 18 years of age or those who underwent a tonsillectomy as part of the treatment of carcinoma of the head or neck were excluded from the study. All postoperative secondary, delayed (5-10 days after surgery) hemorrhage which required intervention, such as electrocautery under local anesthesia or a second surgery under general

smUPPP and tonsillectomy

anesthesia for both groups was recorded. Postoperative secondary bleeding from the tonsillectomy regions

Address for correspondence: Dr. Elif Ayanoglu Aksoy, Acibadem University, Faculty of Medicine, Acibadem Maslak Hospital Büyükdere cad. No:40 Maslak, Istanbul, Turkey. E-mail: elifayanoglu@yahoo.com

Received: 23-08-2012; **Revised:** 22-10-2013; **Accepted:** 12-12-2013

were recorded and compared. Bleeding from the palate was excluded.

The smUPPP technique used in this study is described by Friedman *et al.*^[9] It is based on standard surgical principles of epithelial preservation and tension-free closure of the epithelium. Most of the mucosa of the soft palate and the anterior and posterior pillars are preserved. Elimination of redundant palatal and pharyngeal tissue is accomplished by subepithelial and muscular stretching and closure. The smUPPP technique comprises two steps: Step 1, tonsillectomy and excision of the soft palate and redundant tissue; and Step 2, reconstruction. A detailed description of the technique is as follows. The patient is orally intubated, and the head is hyperextended with a Crowe-Davis tonsillectomy mouth gag in place. Intravenous dexamethasone (8-12 mg) is administered perioperatively. The surgeon is seated at the patient's head with headlight illumination. First, the tonsils are excised using the electrocautery technique described by Drezner.^[10] The tonsil is grasped with a curved allis forceps and pulled medially. This helps to assess the lateral extent of the tonsil and the proper plane of dissection. The needle tip is then used in 35 W cutting mode to expose the tonsil capsule via a curvilinear incision. To further identify the capsule, Yankauer suction is used to push the palate superiorly as the surgeon pulls the tonsil medially. The dissection proceeds using a bovie in 35 W coagulation mode to separate the tonsil capsule from the superior constrictor muscle and to cauterize the blood vessels entering the tonsil. Constant traction of the tonsil is maintained, allowing the tissue to be separated as it is cauterized by the bovie. The removal of the tonsil proceeds within its anatomical boundaries, with the musculature of the tonsil fossa left intact. Dissection proceeds inferiorly toward the base of the tongue until the tonsil is free of all attachments. At the end of the tonsillectomy, the tonsillar fossa is dry.

smUPPP and tonsillectomy

and the muscle fibers are still covered by fascia. After the removal of both tonsils, the palate is addressed. The uvula is grasped with allis forceps and retracted anteriorly for an optimal approach to the posterior surface of the soft palate. A curvilinear horizontal incision is made on the mucosa at the base of the uvula posteriorly, preserving almost the entire posterior soft palate mucosa. Using the needle tip in cautery coagulation mode, the mucosa is separated from the muscle, releasing the posterior soft palate mucosa. Using the needle tip in cutting mode, a trapezoid incision is outlined at the anterior mucosa of the soft palate at a level previously identified below the "dimpled" area, as visualized preoperatively on the awake patient. The incision is extended bilaterally and horizontally across the soft palate to the downward slope of the anterior pillar. The uvula and

the submucosal tissue of the lower edge of the soft palate are excised. The redundant pharyngeal folds are eliminated by approximation of the muscular tissue of the tonsillar fossa and the soft palate using interrupted 3-0 vicryl sutures through these muscles. The mucosal flap edges are loosely approximated, without undermining, using 3-0 vicryl sutures. Particular attention is paid to the inferior parts of the tonsillar fossa, where the majority of secondary bleeding occurs. Bipolar cautery is used to cauterize these parts, after which the inferior parts of the tonsillar fossas are sutured using inferolateral pharyngoplasty. Inferolateral pharyngoplasty involves at least four interrupted sutures with 3-0 vicryl to tack the inferior pharyngeal redundancy laterally. This is accomplished by suturing the muscle layer of the inferior tonsillar fossa laterally to the base of the tongue as the first layer. The second layer of mucosal epithelial interrupted sutures then overlies this layer.

During soft palate excision, particular attention is paid to the base of the uvula on both sides where the uvular artery enters the soft palate. This location on both sides is cauterized

smUPPP and Tonsillectomy

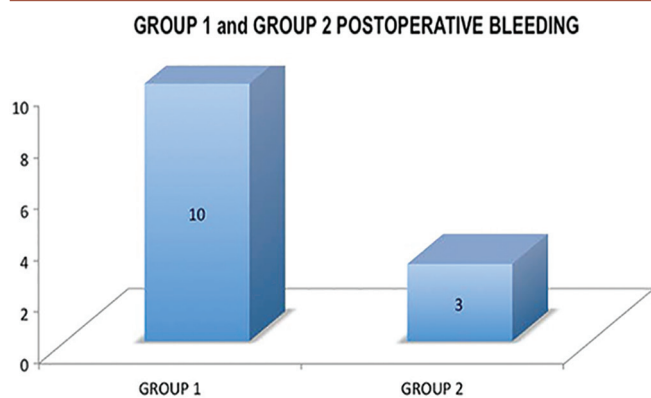
using bipolar cautery. Bipolar cauterization followed by tacking with 3-0 vicryl sutures may have decreased the incidence of postoperative bleeding compared with routine tonsillectomy.

The tonsillectomy technique used in Group 1 patients is also the same electrocautery technique and instrumentation described by Drezner,^[10] and the tonsillar fossae are left intact for secondary healing [Videos 1-2].

The χ^2 test was used for statistical analysis. except in cases with expected sample sizes of fewer than five, for which the Fisher's exact test was used. (SPSS Statistics Desktop, V22.0.0 is used for data analysis. $P \leq 0.05$ is the level of significance).

RESULTS

The mean age of Group 1 patients was 38.1 (± 2.58) years, and that of Group 2 was 37.7 (± 2.2) years. Males were 51.3% of Group 1 and 46.7% of Group 2. No statistically significant difference in age or gender distribution was found between Groups 1 and 2 ($P > 0.05$). There were 198 patients in the tonsillectomy with unipolar electrocautery group (Group 1) and 206 in the smUPPP group (Group 2). The incidence of secondary, delayed hemorrhage was 5.05% (10 patients) in Group 1 and 1.45% (3 patients) in Group 2 ($P = 0.05$) showing statistically significant difference. The incidence of delayed hemorrhage requiring surgical treatment was 4.54% (nine patients) in Group 1 and 0.97% (two patients) in Group 2 [Graph 1].

Graph 1: Postoperative bleeding

DISCUSSION

The rate of post-tonsillectomy hemorrhage reported in the literature is variable due to the lack of consensus on what is considered significant postoperative hemorrhage. In many studies, only if surgical intervention under general anesthesia is required to control the bleeding will a case be considered as having significant hemorrhage,^[11-14] and the studies that take this view find lower hemorrhage rates.^[15] But in our study, all patients who required

smUPPP and tonsillectomy

medical attention for control of bleeding were considered as having postoperative hemorrhage, regardless of whether they required hemorrhage control under local anesthesia or full surgery under general anesthesia. Posttonsillectomy hemorrhage incidence in adults is reported in the literature to be 1.5%-18.0%, but the more commonly given range is between 3.0% and 5.0%.^[5,12,16-21] In our study, the postoperative bleeding rate of the tonsillectomy group was similar to the rates mentioned in the literature. Our bleeding rate after electrocautery tonsillectomy was 5.05%. In the literature, rates of hemorrhage after smUPPP have not been studied as extensively as those after tonsillectomy. The range encountered in the literature varies from 0.6% to 14.0%,^[22-25] and in our study, the bleeding rate after smUPPP was 1.45% which falls within that range. In the present study, when electrocautery tonsillectomy and smUPPP groups were compared, a significant difference in the rate of hemorrhage was apparent. The incidence of bleeding after smUPPP was lower than that after tonsillectomy alone. Although the tonsillectomy portion of the procedures was performed in an identical manner for both of our study groups, the postoperative bleeding rates differed. Some studies have found an increased rate of posttonsillectomy hemorrhage in males compared with females,^[7,14,19] but the gender distribution did not differ between study groups, which agrees with several other studies.^[5-6,18,21] The increased rate of hemorrhage in the

tonsillectomy group could not be attributed to any factor other than the operative techniques used. However, the bleeding rates for tonsillectomy and smUPPP patients remained significantly higher among tonsillectomy patients whose muscular tissue of the tonsillar fossa was not approximated using interrupted 3-0 vicryl sutures through the tissue. The mucosal flap edges were also not approximated. Suturing both the muscular and mucosal layers of the tonsillar fossa in smUPPP seemed to decrease the incidence of postoperative bleeding. Furthermore, bipolar cauterization followed by tacking with 3-0 vicryl sutures may have.

smUPPP and tonsillectomy

decreased the incidence of postoperative bleeding. Suturing of the tonsillar pillars is the only influencing factor detected that may have lowered the bleeding incidence. Double-layer closure and approximating muscular and mucosal layers after tonsillectomy might help postoperative oropharyngeal healing, resulting in decreased bleeding incidence.

CONCLUSION

Submucosal tonsillectomy, which is a part of smUPPP, has a lower incidence of postoperative delayed hemorrhage compared with tonsillectomy using unipolar cautery in adult patients. We suggest routine use of the suturing technique for smUPPP in all tonsillectomy patients to reduce the rate of postoperative hemorrhage.

REFERENCES

1. Krishna P, Lee D. Post-tonsillectomy bleeding: A meta-analysis. *Laryngoscope* 2011;111:1358-61.
2. Kim MK, Lee JW, Kim MG, Ha SY, Lee JS, Yeo SG. Analysis of prognostic factors for postoperative bleeding after tonsillectomy. *Eur Arch Otorhinolaryngol* 2012;269:977-81.
3. Lee SW, Kim YS, Song TH, Cha YJ, Lee BD, Chang HS. Clinical analysis of postoperative hemorrhage after tonsillectomy. *Korean J Otolaryngol* 1998;41:1590-3.
4. Lowe D, van der Meulen J; National prospective tonsillectomy audit Tonsillectomy technique as a risk factor for postoperative haemorrhage. *Lancet* 2004;364:697-702.
5. Wei JL, Beatty CW, Gustafson RO. Evaluation of posttonsillectomy hemorrhage and risk factors. *Otolaryngol Head Neck Surg* 2000;123:229-35.
6. Tami TA, Parker GS, Taylor RE. Post-tonsillectomy bleeding: An evaluation of risk factors. *Laryngoscope* 1987;97:1307-11.
7. Collison PJ, Mettler B. Factors associated with posttonsillectomy hemorrhage. *Ear Nose Throat J* 2000;79:640-2, 644, 646 passim.
8. Kumar VV, Kumar NV, Isaacson G. Superstition and post-tonsillectomy hemorrhage. *Laryngoscope* 2004;14:2031-3.
9. Friedman M, Landsberg R, Tanyeri H. Submucosal uvulopalatopharyngoplasty. *Op Tech Otolaryngol Head Neck Surg* 2000;11:26-9.
10. Drezner DA. Bipolar bovie tonsillectomy. *Op Tech Otolaryngol Head Neck Surg* 1997;8:56-60.

11. Windfuhr JP, Chen YS, Remmert S. Hemorrhage following tonsillectomy and adenoidectomy in 15,218 patients. *Otolaryngol Head Neck Surg* 2005;132:281-6.
12. Clark MP, Waddell A. The surgical arrest of post-tonsillectomy haemorrhage: Hospital episode statistics. *Ann R Coll Surg Engl* 2004;86:411-2.
13. Hopkins C, Geyer M, Topham J. Post-tonsillectomy haemorrhage: A 7-year retrospective study. *Eur Arch Otorhinolaryngol* 2003;260:454-5.
14. Windfuhr JP, Ulbrich T. Post-tonsillectomy hemorrhage: Results of a 3-month follow-up. *Ear Nose Throat J.* 2001;80:790, 795-8, 800 passim.
15. Demars SM, Harsha WJ, Crawford JV. The effects of smoking on the rate of postoperative hemorrhage after tonsillectomy and uvulopalatopharyngoplasty. *Arch Otolaryngol Head Neck Surg* 2008;134:811-4.
16. Carmody D, Vamadevan T, Cooper SM. Post tonsillectomy haemorrhage. *J Laryngol Otol* 1982;96:635-8.
17. Liu JH, Anderson KE, Willging JP, Myer CM 3rd, Shott SR, Bratcher GO, *et al.* Posttonsillectomy hemorrhage: What is it and what should be recorded? *Arch Otolaryngol Head Neck Surg* 2001;127:1271-5.
18. Bhattacharyya N. Evaluation of post-tonsillectomy bleeding in the adult population. *Ear Nose Throat J* 2001;80:544-9.
19. Windfuhr JP, Chen YS. Incidence of post-tonsillectomy hemorrhage in children and adults: A study of 4,848 patients. *Ear Nose Throat J* 2002;81:626-8, 630, 632 passim.
20. Evans AS, Khan AM, Young D, Adamson R. Assessment of secondary haemorrhage rates following adult tonsillectomy — a telephone survey and literature review. *Clin Otolaryngol Allied Sci* 2003;28:489-91.
21. Alexander RJ, Kukreja R, Ford GR. Secondary post-tonsillectomy haemorrhage and informed consent. *J Laryngol Otol* 2004;118:937-40.
22. Haavisto L, Suonpaa J. Complications of uvulopalatopharyngoplasty. *Clin Otolaryngol Allied Sci* 1994;19:243-7.
23. Mickelson SA, Hakim I. Is postoperative intensive care monitoring necessary after uvulopalatopharyngoplasty? *Otolaryngol Head Neck Surg* 1998;119:352-6.
24. Riley RW, Powell NB, Guilleminault C, Pelayo R, Troell RJ, Li KK. Obstructive sleep apnea surgery: Risk management and complications. *Otolaryngol Head Neck Surg* 1997;117:648-52.
25. Kim JA, Lee JJ, Jung HH. Predictive factors of immediate postoperative complications after uvulopalatopharyngoplasty. *Laryngoscope* 2005;115:1837-40.

Source of Support: Nil, **Conflict of Interest:** None declared.

Archive of SID