

How may Doppler indices help in the differentiation of obstructive from nonobstructive hydronephrosis?

Maryam Riahinezhad¹, Amir Hossein Sarrami¹, Alaleh Gheisari², Omid Shafaat^{1,3}, Alireza Merikhi², Mehdi Karami¹, Maryam Farghadani¹, Masoud Moslehi⁴

¹Department of Radiology, Alzahra Hospital, Isfahan University of Medical Sciences, ²Department of Pediatrics, Emam Hossein Children Hospital, Isfahan University of Medical Sciences, Departments of ³Neurointerventional Radiology and ⁴Medical Physics, Isfahan University of Medical Sciences, Isfahan, Iran

Background: We assess the potency of different Doppler indices in the differentiation of obstructive and nonobstructive hydronephrosis. **Materials and Methods:** In this study, infants and children who were referred for the evaluation of unilateral hydronephrosis were enrolled. Ultrasonography for the assessment of the degree of hydronephrosis and a voiding cystourethrogram for the exclusion of vesicoureteral reflux was performed. Then, Doppler ultrasonography was done for both kidneys of each patient using four classic Doppler indices as well as the difference (delta) of each index between to kidneys. Diuretic renography with 99 mTc-ethylene dicysteine (99 mTc-EC) was performed for each patient. **Results:** Thirty-nine patients met the inclusion criteria. After diuretic renography, 29 (74.35%) patients had shown a nonobstructive pattern, and ten (25.65%) patients had a partial (intermediate) or complete obstruction. Using receiver operating characteristic (ROC) curve, none of the classic indices of Doppler duplex (i.e., resistive index [RI], resistance index, end diastolic velocity, and peak systolic velocity) had the ability to make a difference between obstructive and nonobstructive hydronephrosis. However, by calculating the difference (delta) of these indices between two kidneys of each patient, delta RI could differentiate the nonobstructive condition, significantly ($P = 0.006$). A cutoff value of 0.055 has 60% sensitivity and 82.8% specificity. The area under the ROC curve for delta RI is 0.795 (standard error: 0.086, 95% confidence interval [CI]: 0.626, 0.964). Furthermore, RI ratio between two kidneys of each patient could differentiate the nonobstructive condition, significantly ($P = 0.012$). A cutoff point of 1.075 has 70% sensitivity and 82.8% specificity. The area under the ROC curve for RI ratio was 0.769 (standard error: 0.104, 95% CI: 0.565, 0.973). **Conclusion:** This study shows that RI ratio and delta RI with a high specificity could differentiate nonobstructive hydronephrosis and therefore it is a promising way to use especially in the follow-up of children with hydronephrosis.

Key words: Doppler, hydronephrosis, pediatric, radioisotope renography, ultrasonography, ureteropelvic junction obstruction

How to cite this article: Riahinezhad M, Sarrami AH, Gheisari A, Shafaat O, Merikhi A, Karami M, et al. How may Doppler indices help in the differentiation of obstructive from nonobstructive hydronephrosis? J Res Med Sci 2018;23:76.

INTRODUCTION

Nowadays, imaging modalities have a crucial role in the diagnosis and follow-up of the urinary tract disorders in pediatrics. The widespread use of prenatal ultrasonography offers the early detection of some of these disorders and provides a guide for further evaluation.^[1] Ureteropelvic junction obstruction (UPJO) is the most common cause of

upper urinary tract obstruction in children.^[2] In this disorder, lack of normal urine passage from the renal pelvis to ureter is considered, mainly because of a functional insufficiency. The increased pressure of renal pelvis due to the accumulation of obstructed urine may result in a progressive decrease in renal function. Ultrasonography is a beneficial tool in the prenatal as well as postnatal detection of hydronephrotic kidneys.^[3] Furthermore, it has been used in the monitoring of the alteration in the degree

This is an open access journal, and articles are distributed under the terms of the Creative Commons Attribution-NonCommercial-ShareAlike 4.0 License, which allows others to remix, tweak, and build upon the work non-commercially, as long as appropriate credit is given and the new creations are licensed under the identical terms.

For reprints contact: reprints@medknow.com

Access this article online	
Quick Response Code: 	Website: www.jmsjournal.net
	DOI: 10.4103/jrms.JRMS_627_17

Address for correspondence: Dr. Amir Hossein Sarrami, Department of Radiology, Alzahra Hospital, Isfahan University of Medical Sciences, Soffeh Street, Isfahan 81744, Iran. E-mail: sarrami@semums.ac.ir

Received: 05-10-2017; **Revised:** 07-02-2018; **Accepted:** 15-05-2018

of hydronephrosis, assessment of cortical thinning or scar, and exclusion of other obstructive etiologies in children with hydronephrosis. However, ultrasonography fails to provide the essential information about the physiologic and functional state of the kidney which is required to confirm the diagnosis of UPJO.^[4-7]

Nuclear renogram has become the standard modality for the assessment of renal function and urinary flow in children with a primary diagnosis of UPJO. This study is usually delayed until the 2nd month after birth to allow for stabilization of glomerular filtration rate and often is performed after a voiding cystourethrogram (VCUG) excludes vesicoureteral reflux (VUR).^[8,9] Diagnosis of UPJO by nuclear renography may be based on decreased differential renal function (<40%) or a reduction in washout time of radioisotope agent.^[10] Besides this controversy on the definition of UPJO which causes intraobserver and interobserver variability in different centers, nuclear renography has its own false negative and positive results. In fact, UPJO is neither uniform nor straightforward diagnosis, even by applying multiple modalities include nuclear renography. Indications of follow-up nuclear renography in known cases of UPJO are another subject of debate in pediatric urology.^[10]

Duplex Doppler ultrasound is a tool which can provide useful information about hemodynamics of kidneys while it is nonionizing modality. It has been demonstrated that obstruction causes a decrease in vascular flow due to increasing in vascular resistance.^[11-13] Resistive index (RI) is the most valuable duplex index used in the obstructive renal states. Diagnostic value of RI has been studied in the evaluation of hydronephrosis in children as well as in adults.^[14,15] In children with unilateral obstruction, increase of RI in intraparenchymal arteries may be a remarkable finding.^[16] However, RI is a nonspecific index and increased renal RI may be seen in urinary obstruction, parenchymal injury, and also vascular abnormality. Moreover, RI is an age-dependent parameter, and applying the adult's threshold value in young children can be misleading.^[17,18]

It has been shown that the utility of RI ratio and a comparison of RI values between the kidneys of each patient are more reliable than using an RI cutoff value in the evaluation of children with unilateral obstruction.^[18]

In this study, we assess the potency of different duplex indices to find their value in the differentiation of obstructive and nonobstructive hydronephrosis. This study may provide an adjunct strategy to resolve controversial renogram results or to decrease the frequency of renograms in the follow-up of known cases of UPJO.

MATERIALS AND METHODS

Patient selection

In a prospective study between January 2014 and March 2015, children aged older than 2 months who were referred by pediatric urologist or nephrologist to the Radiology Department for evaluation of unilateral hydronephrosis were enrolled, consecutively. Primary diagnosis of UPJO was considered using the gray-scale US in the patients with unilateral hydronephrosis (anteroposterior diameter of pelvis >7 mm), beaking of UPJ, and normal diameter of ureter without evidence of pelvicalyceal calculus. All patients underwent a standard VCUG^[19] for the exclusion of VUR or any probable anatomical malformation. In this study, we applied the normal contralateral kidney as a control for each case to compare indices. Therefore, patients with bilateral UPJO, horseshoe kidney, or any other developmental abnormalities (including multicystic dysplastic kidney, contralateral VUR, megaureter, retrocaval ureter, or vascular malformations) were excluded from the study. Furthermore, the cases with long-standing severe UPJO in which no parenchyma for detecting vessels was available were excluded from the study. The ethics committee approved this study, and written informed consent was obtained from all subjects.

Doppler duplex study

All infants and children were well fed or hydrated before the survey. The Doppler US was done during slow breathing and sometimes under sedation with oral administration of 0.5–1 cc/kg chloral hydrate. Both gray-scale and Doppler examination were performed using a Voluson E8 ultrasound machine (GE Healthcare), by the use of the linear and curved transducers. For localization of vessels, color Doppler with a 2–4 mm Doppler gate was used. In the initial evaluation by color Doppler, any evidence of bridging artery, microaneurysm, stenosis, or thrombosis in the course of both renal arteries from their origin to arcuate branches was excluded.

All waveforms were measured on the lowest velocity scale (to maximize the waveform sizes) and achieved without obscuring background noise. The angle between the ultrasound beam and the direction of blood flow was adjusted as close as possible to 0°. The average of highest and lowest velocity of three similar consecutive waveforms was selected as peak systolic velocity (PSV) and end diastolic velocity (EDV).

Pulsatility index defined as PSV minus EDV divided by mean velocity. RI was defined as PSV minus EDV divided by PSV. It was measured manually and also by the automatic option of the ultrasound setting in the arcuate and interlobular branches of the upper and lower poles

and interpolar parenchyma. Waveforms were obtained at least three times for each kidney and values from these waveforms averaged to obtain mean values for each kidney. These steps were all performed for both kidneys of each patient. Then, the difference between Doppler indices of kidneys of each patient was calculated and recorded. RI ratio was defined as the ratio of RI in the hydronephrotic kidney to that in the healthy contralateral kidney.

Diuretic renography

If the patient had a diuretic renography in recent 3 months, he/she was exempted from a repeat of the renography. In other children, diuretic renography was offered and only the renography which was performed within 1 month since Doppler ultrasonography was accepted and other patients were excluded from the study. In those with new diuretic renography before the Doppler study, the radiologist remained unaware of renography results during ultrasonography to avoid probable bias.

All the diuretic renography was performed in a university hospital center and interpreted by a specialist in the nuclear medicine who was unaware of the Doppler results.

Infants aged under 1 year were well fed by milk 15–30 min before the scan. Other children were orally hydrated with up to 500 ml of water. The parents were asked to ensure about voiding of the child just before the start of the test. The diuretic renography was performed using a Philips (ADAC) Forte Dual Head Gamma Camera equipped with low-energy all-purpose collimators. After the intravenous injection of 4.2 MBq/kg (0.12 mCi/kg) of ^{99m}Tc-ethylene dicycysteine (^{99m}Tc-EC) (with a maximum dose of 555 MBq) image acquisition was started immediately. Dynamic acquisition at 64 × 64 matrix was acquired 2 s per frame for 1 min and 1 min per frame for 30 min, from posterior view in the supine position. At 15th frame, the furosemide was intravenously injected (1 mg/kg, the maximum dose of 20 mg). We did not insert a Foley catheter into the bladder, unless occasionally in the noncooperative children. Postvoiding static 1 min images were acquired to quantify excretion.

After grouping the dynamic images, a region of interest over each kidney and the urinary collecting systems was drawn manually. The background radiation was subtracted. Using renogram time-activity curves on the images, obstruction was defined. Clearance half-life <10 min was defined as nonobstructive, 10–19 min defined as intermediate (partial), and >20 min was defined as the obstructive value finding.

Statistical analysis

All analyses were performed in IBM SPSS Statistics (version 20, IBM, Somers, NY, USA). We used receiver operating characteristic (ROC) curve for obtaining

the cutoff points. Demographic findings were reported by descriptive tests (mean and standard deviation). For comparing the mean values between two groups, the independent student *t*-test was used. $P < 0.05$ was considered statistically significant.

RESULTS

Of 51 patients who met the inclusion criteria, 39 patients were willing to complete the offered workup and their diuretic renography was performed within the expected time. Twenty-six (66.7%) were male and 13 (33.3%) were female. Their age was ranged from 2 months to 13 years. Twenty (51.3%) were under 2 years and 34 (87.2%) were under 8 years. Figure 1 shows the age distribution of the patients. Hydronephrosis in 32 (82.1%) cases was in left kidney, and 7 (17.9%) was in right kidney. After diuretic renography, 29 (74.35%) patients had shown a nonobstructive pattern (12.82%), 5 patients had an intermediate (partial) obstruction (12.82%), and 5 patients showed a complete obstructive pattern.

Table 1 demonstrates Doppler indices in both nonobstructive and obstructive cases. Using ROC curve, none of the classic indices of Doppler duplex (i.e., resistive index [RI], pulsatility index [PI], EDV, and PSV) had the ability to make a difference between obstructive and nonobstructive hydronephrosis. However, by calculating delta of these indices between two kidneys of each patient, delta RI could differentiate the nonobstructive condition, significantly ($P = 0.006$). A cutoff value of 0.055 has 60% sensitivity and 82.8% specificity. The area under the ROC curve for delta RI is 0.795 (standard error: 0.086, 95% confidence interval [CI]: 0.626, 0.964).

Furthermore, RI ratio between two kidneys of each patient could differentiate the nonobstructive condition,

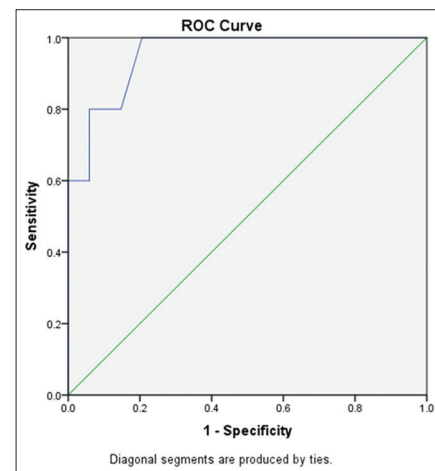


Figure 1: Potency of resistive index ratio for diagnosis of obstructive hydronephrosis

Table 1: Renal Doppler indices in patients with hydronephrosis

Doppler Indices	Patients with nonobstructive hydronephrosis (n=29)		Patients with partial or complete UPJO (n=10)		P value for comparing the means*
	Range	Mean±SD	Range	Mean±SD	
RI	0.60-0.79	0.68±0.05	0.62-0.84	0.71±0.07	0.167
PI	0.20-1.80	1.16±0.34	0.85-1.90	1.20±0.35	0.853
EDV (cm/s)	3.0-28	14.18±5.87	4.7-26	15.08±7.93	0.117
PSV (cm/s)	11.0-87	41.92±17.62	13.0-67	45.20±18.29	0.697
RI ratio	0.71-1.15	1±0.07	0.95-1.31	1.11±0.125	0.054
Delta RI	0.00-0.08	0.02±0.02	0.02-0.20	0.08±0.06	0.00
Delta PI	0.00-0.80	0.23±0.20	0.00-0.90	0.31±0.28	0.273
Delta EDV	0.00-13	3.46±2.94	0.00-24	7.09±7.50	0.001
Delta PSV	0.00-33	11.26±7.92	1.00-41	16.40±13.28	0.045

*Independent t-test. PSV=Peak systolic velocity; EDV=End diastolic velocity; PI=Pulsatility index; RI=Resistive index; UPJO=Ureteropelvic junction obstruction; SD=Standard deviation

Table 2: Valuable renal Doppler indices based on receiver operating characteristic curves for diagnosis of obstructive hydronephrosis

Renal Doppler index	RI ratio	Delta RI
Cutoff point	1.075	0.055
Sensitivity (%)	70	60
Specificity (%)	85.8	82.8
Mean area under the curve±SE	0.769±0.104	0.795±0.086
95% CI	0.565-0.973	0.626-0.964
P	0.012	0.006

SE=Standard error; CI=Confidence interval; RI=Resistive index

significantly ($P = 0.012$). A cutoff point of 1.075 has 70% sensitivity and 82.8% specificity. The area under the ROC curve for RI ratio was 0.769 (standard error: 0.104, 95% CI: 0.565, 0.973) [Figures 2 and 3] [Table 2].

DISCUSSION

In this study, we assess the potency of Doppler indices in the differentiation of obstructive from nonobstructive hydronephrosis in children. Our results show that RI ratio and delta RI with a high specificity could differentiate nonobstructive hydronephrosis, and therefore, it is a promising way to use in the follow-up of children with hydronephrosis.

In our practice, a large number of children with the typical gray-scale appearance of UPJO have normal urine passage in diuretic renography. Moreover, in the follow-up of known cases of stable noncomplete UPJO, interobserver variation about the grading of hydronephrosis sometimes leads to a repeat of a diuretic renography, in the absence of true change in the patient's condition. Another issue is permanent dilatation of pyelocaliceal system in some UPJO children after pyeloplasty, despite the removal of the obstruction. These repetitive conflicts rise the rate of inopportune diuretic renography, as well as health expenditure and parental concern.

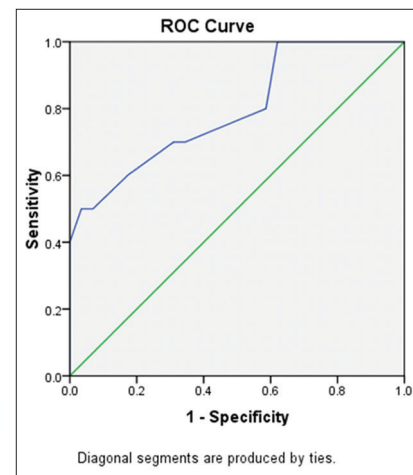


Figure 2: Potency of delta resistive index for diagnosis of obstructive hydronephrosis

Doppler ultrasound has been introduced as an available, nonionizing, low-cost modality in the assessment of some urinary tract diseases in pediatrics. During the past decades, several studies have been done to find the association of alterations in renal arterial waveform and indices with renal parenchymal injury, urinary obstruction, VUR, and vascular disorders.^[11,13,20] Renal RI has been introduced as an angle-independent index for quantifying the changes in blood flow that may occur with different parenchymal or collecting system pathologies.^[14] Based on the most of the studies, a standard mean renal RI is about 0.60. However, 0.70 is the acceptable upper limit of normal RI in adults. In children at the early 4 years of life, it is frequently seen that mean RI may go more than 0.70.^[21,22]

In this study, we measured other Doppler indices further than RI, such as PI which is valuable in Doppler study of some splanchnic arteries. However, none of them could differentiate obstructive from nonobstructive conditions.

The efficacy of Doppler sonography in the management of partial UPJO is restricted. Chen *et al.*^[23] illustrated that

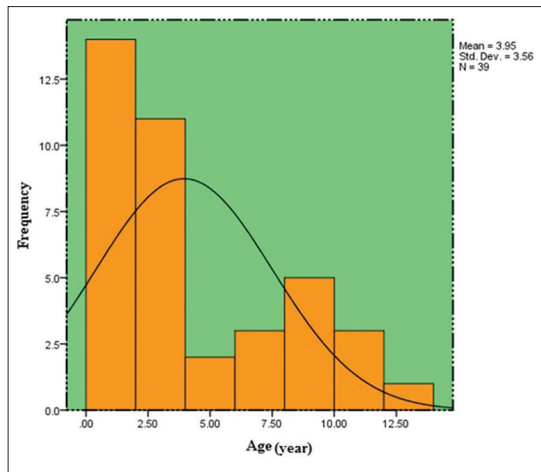


Figure 3: Age distribution of the patients

RI is often elevated at complete or high-grade UPJO, but most cases with incomplete or low-grade UPJO had normal RIs. Furthermore, Cole *et al.*^[24,25] in two separate animal experimental studies in pig and rabbit models demonstrated the limitation of Doppler sonography to detect low-grade UPJO.

Several studies have shown that the sensitivity of Doppler sonography in partial UPJO may improve by doing the study after force diuresis (diuretic Doppler sonography).^[26,27] Although this modality is not approved by general radiology or urology committees yet, recent studies illustrate a technical support of diuretic Doppler sonography in the evaluation of UPJO. The high false-negative rate of this technique may be due to low-grade or partial UPJO, extremely early obstruction or forniceal rupture. In these cases, with severe chronic obstruction, arterial stretchability would be affected because interstitial pressures are normal.

In a study by Riccabona *et al.*,^[28] children with complete obstruction of UPJ showed a significantly increased and asymmetric mean RI which returned to normal value after the operation. In their study, other noncomplete UPJO cases who have not an indication for surgery on diuretic renography showed a normal and symmetrical mean RI. In our study, RI could not differentiate obstructive from nonobstructive cases.

Lim *et al.* in a study evaluated the usefulness of the RI ratio in differentiation between obstructive or nonobstructive upper urinary tract dilation in children. They demonstrated that an RI ratio (which compares the RI of the dilated kidney with the RI of the normal, contralateral kidney) cut-off value of ≥ 1.10 appears to be a useful parameter for evaluation and follow-up of unilateral obstructive hydronephrosis in children.^[18] In our study, RI ratio of ≤ 1.075 could differentiate nonobstructive hydronephrosis with 82.8% specificity.

In a study by Lee *et al.*, RI and delta RI had limitations in the diagnosis of unilateral obstructive uropathy due to very low sensitivity. They declared that elevated RI might indicate an acute and severe obstructive uropathy; nevertheless, it is a poor indicator of chronic or partial obstruction.^[29]

In the present study, we used ^{99m}Tc -EC as radioisotope agent. ^{99m}Tc -EC has been used as a substitute for Tc DTPA with apparently more accurate results than that obtained from ^{99m}Tc -DTPA.^[30]

Limitations regarding this study should be implied. Some of our patients did not desire to continue the workup or discontinue the follow-up, so our initial sample size decreased. The study patients show a relatively wide age range. In our series, there was a small percentage of older children with recently detected hydronephrosis which were referred for workup and enrolled in the study. Although it was preferable only to enroll the infants, the concentration of patients' age is in early childhood, as shown in Figure 1. Moreover, considering the use of both the indices and their delta between two kidneys, the effect of age on our results seems not to be significant.

In this study, we used contralateral kidney as a control in each patient, and we measured RI ratio and delta RI for overcoming the potential bias of RI include of dependency to age group and systemic conditions. Our results show that both RI ratio and delta RI are reliable indices with equal value in the diagnosis of nonobstructive hydronephrosis. However, in children with any urinary tract disease or malformation in contralateral kidney, these two indices may have questionable value.

CONCLUSION

Diuretic renography is used to diagnosis of renal function and urinary obstruction, but the interpretation of its results and the definition of obstruction is controversial in different centers. Furthermore, the indications of diuretic renography in the follow-up of hydronephrosis are another subject of debate. Doppler ultrasound is a practical and safe modality which can use in differentiating nonobstructive hydronephrosis. This study shows that RI ratio and delta RI with a high specificity could differentiate nonobstructive hydronephrosis, and therefore it is a promising way to use especially in the follow-up of children with hydronephrosis. Further extensive studies are helpful for determining whether Doppler ultrasound can replace diuretic renography in the follow-up of children after pyeloplasty or not.

Financial support and sponsorship

Nil.

Conflicts of interest

There are no conflicts of interest.

REFERENCES

- Longpre M, Nguan A, Macneily AE, Afshar K. Prediction of the outcome of antenatally diagnosed hydronephrosis: A multivariable analysis. *J Pediatr Urol* 2012;8:135-9.
- Hashim H, Woodhouse CR. Ureteropelvic junction obstruction. *Eur Urol Suppl* 2012;11:25-32.
- Vandervoort K, Lasky S, Sethna C, Frank R, Vento S, Choi-Rosen J, *et al.* Hydronephrosis in infants and children: Natural history and risk factors for persistence in children followed by a medical service. *Clin Med Pediatr* 2009;3:63-70.
- Gordon I, Dhillon HK, Gatanash H, Peters AM. Antenatal diagnosis of pelvic hydronephrosis: Assessment of renal function and drainage as a guide to management. *J Nucl Med* 1991;32:1649-54.
- Lidefelt KJ, Herthelius M, Soeria-Atmadja S. Antenatal renal pelvis dilatation: 2-year follow-up with DMSA scintigraphy. *Pediatr Nephrol* 2009;24:533-6.
- Keays MA, Guerra LA, Mihill J, Raju G, Al-Asheeri N, Geier P, *et al.* Reliability assessment of society for fetal urology ultrasound grading system for hydronephrosis. *J Urol* 2008;180:1680-2.
- Szymanski KM, Al-Said AN, Pippi Salle JL, Capolicchio JP. Do infants with mild prenatal hydronephrosis benefit from screening for vesicoureteral reflux? *J Urol* 2012;188:576-81.
- Moon DH, Park YS, Jun NL, Lee SY, Kim KS, Kim JH, *et al.* Value of supranormal function and renogram patterns on 99mTc-mercaptoacetyltriglycine scintigraphy in relation to the extent of hydronephrosis for predicting ureteropelvic junction obstruction in the newborn. *J Nucl Med* 2003;44:725-31.
- Lidefelt KJ, Ek S, Mihocsa L. Is screening for vesicoureteral reflux mandatory in infants with antenatal renal pelvis dilatation? *Acta Paediatr* 2006;95:1653-6.
- Taylor A Jr., Clark S, Ball T. Comparison of Tc-99m MAG3 and Tc-99m DTPA scintigraphy in neonates. *Clin Nucl Med* 1994;19:575-80.
- Geavlete P, Georgescu D, Cauni V, Nița G. Value of duplex Doppler ultrasonography in renal colic. *Eur Urol* 2002;41:71-8.
- Kiliç S, Altinok MT, Ipek D, Beytur A, Baydinç YC, Güneş G, *et al.* Color Doppler sonography examination of partially obstructed kidneys associated with ureteropelvic junction stone before and after percutaneous nephrolithotripsy: Preliminary report. *Int J Urol* 2005;12:429-35.
- Tublin ME, Bude RO, Platt JF. Review. The resistive index in renal Doppler sonography: Where do we stand? *AJR Am J Roentgenol* 2003;180:885-92.
- Piazzese EM, Mazzeo GI, Galipò S, Fiumara F, Canfora C, Angiò LG, *et al.* The renal resistive index as a predictor of acute hydronephrosis in patients with renal colic. *J Ultrasound* 2012;15:239-46.
- Okada T, Yoshida H, Iwai J, Matsunaga T, Yoshino K, Ohtsuka Y, *et al.* Pulsed Doppler sonography of the hilar renal artery: Differentiation of obstructive from nonobstructive hydronephrosis in children. *J Pediatr Surg* 2001;36:416-20.
- Wong SN, Lo RN, Yu EC. Renal blood flow pattern by noninvasive Doppler ultrasound in normal children and acute renal failure patients. *J Ultrasound Med* 1989;8:135-41.
- Keller MS. Renal Doppler sonography in infants and children. *Radiology* 1989;172:603-4.
- Lim GY, Jang HS, Lee EJ, Lim YS, Jung SE, Lee JM, *et al.* Utility of the resistance index ratio in differentiating obstructive from nonobstructive hydronephrosis in children. *J Clin Ultrasound* 1999;27:187-93.
- Fernbach SK, Feinstein KA, Schmidt MB. Pediatric voiding cystourethrography: A pictorial guide. *Radiographics* 2000;20:155-68.
- de Bessa J Jr., Dénes FT, Chammas MC, Cerri L, Monteiro ED, Buchpiguel CA, *et al.* Diagnostic accuracy of color Doppler sonographic study of the ureteric jets in evaluation of hydronephrosis. *J Pediatr Urol* 2008;4:113-7.
- Bude RO, DiPietro MA, Platt JF, Rubin JM, Miesowicz S, Lundquist C, *et al.* Age dependency of the renal resistive index in healthy children. *Radiology* 1992;184:469-73.
- Andriani G, Persico A, Tursini S, Ballone E, Cirotti D, Lelli Chiesa P, *et al.* The renal-resistive index from the last 3 months of pregnancy to 6 months old. *BJU Int* 2001;87:562-4.
- Chen JH, Pu YS, Liu SP, Chiu TY. Renal hemodynamics in patients with obstructive uropathy evaluated by duplex Doppler sonography. *J Urol* 1993;150:18-21.
- Cole TC Jr., Brock JW 3rd, Pope JC 4th, Schrum FF, Milam DF, Flickinger JE, *et al.* Evaluation of renal resistive index, maximum velocity, and mean arterial flow velocity in a hydronephrotic partially obstructed pig model. *Invest Radiol* 1997;32:154-60.
- Coley BD, Arellano RS, Talner LB, Baker KG, Peterson T, Mattrey RF, *et al.* Renal resistive index in experimental partial and complete ureteral obstruction. *Acad Radiol* 1995;2:373-8.
- Bertolotto M, Moro U, Gioulis E, Lodolo C, Lissiani A. Changes of renal resistive index in response to hydration and diuretic administration in normal subjects and in patients with small ureteral stone. *J Ultrasound Med* 1999;18:819-25.
- Shokeir AA, Provoost AP, El-Azab M, Dawaba M, Shokeir MA, Nijman RJ, *et al.* Renal Doppler ultrasonography in children with equivocal obstructive uropathy: Effect of intravenous normal saline fluid load and frusemide. *Br J Urol* 1997;80:313-8.
- Riccabona M, Ring E, Fueger G, Petritsch P, Villits P. Doppler sonography in congenital ureteropelvic junction obstruction and multicystic dysplastic kidneys. *Pediatr Radiol* 1993;23:502-5.
- Lee HJ, Kim SH, Jeong YK, Yeun KM. Doppler sonographic resistive index in obstructed kidneys. *J Ultrasound Med* 1996;15:613-8.
- Lima MC, de Lima ML, Pepe CF, Etchebehere EC, Santos AO, Amorim BJ, *et al.* Technetium-99m-L, L-ethylenedicysteine is more effective than technetium-99m diethylenetriamine penta-acetic acid for excluding obstruction in patients with pyelocalicinal dilation. *Urology* 2010;76:283-8.