

## Estimation of Right Atrial Pressure from the Inspiratory Collapse of the Inferior Vena cava in Pediatric Patients

Hamid Amoozgar, MD; Khobiar Zare, MD; Gholamhossein Ajami, MD; Mohammad Borzooe, MD and Saeed Abtahi, MD

Division of pediatric cardiology, Shiraz University of Medical Sciences, Shiraz, Iran

Received: May 28, 2009; Final Revision: Dec 14, 2009; Accepted: Dec 30, 2009

### Abstract

**Objective:** Paucity of data exists between mean right atrial pressure (RAP) and inferior vena cava (IVC) size and collapsibility in pediatric patients with congenital heart disease.

**Methods:** In a prospective study, fifty consecutive pediatric patients with different congenital heart diseases who had right side cardiac catheterization were studied, comparing right atrial pressure with simultaneous M-mode echocardiographic measurement of inferior vena cava diameter. Mean age of the patients was  $4.96 \pm 4.05$  years (30 male and 20 female). Patients were categorized into two groups according to their right atrial pressure (RAP) as measured by cardiac catheterization: Group 1 (40 patients) were those with mean RAP  $< 8$  mmHg and group 2 (10 patients) who had a mean RAP  $\geq 8$  mmHg.

**Findings:** In M-mode echocardiography IVC size was statistically different ( $P=0.004$  and  $0.009$ ) in inspiration and expiration in the two groups. Mean RAP was estimated to be  $> 8$  mmHg when IVC diameter in inspiration was  $> 3.6$  (sensitivity of 100%, specificity of 47.5%,  $+LR=1.9$ ) or if IVC diameter was  $> 6$  mm in expiration (sensitivity of 70%, specificity of 87%,  $+LR=4.67$ ).

**Conclusion:** This study showed that measurement of IVC size in inspiration and expiration can be used as a reliable method for estimation of mean right atrial pressure.

*Iranian Journal of Pediatrics, Volume 20 (Number 2), Jun 2010, Pages: 206-210*

**Key Words:** Heart atrium; Echocardiography; Inferior vena cava; Pressure

### Introduction

Noninvasive measurement of right ventricular pressure, pulmonary pressure and left atrial pressure with Doppler echocardiography is a widely accepted technique in most

echocardiographic laboratories. This is accomplished by applying the modified Bernoulli principle to the peak tricuspid regurgitation velocity, which reflects the instantaneous pressure gradient between the right atrium and right ventricle or right atrium and left atrium

\* Corresponding Author;

Address: Department of Pediatrics, Nemazee Hospital, Shiraz, Iran; 7193711351.

E-mail: amozgah@sums.ac.ir

© 2010 by Pediatrics Center of Excellence, Children's Medical Center, Tehran University of Medical Sciences, All rights reserved.

through defected inter-atrial septum [1-5]. The accuracy of this technique depends on making an accurate estimate of right atrial pressure (RAP) during mid systole [6]. In addition the estimation of right ventricular filling pressures is important clinically for the diagnosis and management of various hemodynamic conditions with decreased or increased preload [7-10].

Although clinical evaluation of jugular venous pulsations is usually used for estimate of RAP, however it may not be easy in children with a short neck, and such an examination may not always be feasible in a busy echocardiography laboratory [8,9].

A few studies in selected adult and pediatric patients have evaluated the hemodynamic correlates of right atrial and right ventricular filling dynamics [11-14]. On the other hand, studies on the changes in the diameter of the inferior vena cava in response to negative intrathoracic pressure have demonstrated a significant correlation of this index with RAP in adults [15-18].

Such an approach, however, requires the patient's cooperation and has been limited in mechanically ventilated individuals [17]. A comprehensive evaluation of the relation of echocardiographic size of inferior vena cava (IVC) to mean RAP in pediatric patients with a variety of congenital heart defects and different clinical conditions has not been studied. This study was undertaken to assess the correlation of inferior vena cava diameter changes to mean RAP in 50 consecutive pediatric patients with various congenital heart diseases undergoing measurement of RAP.

## Subjects and Methods

In a prospective study from April 2007 until June 2008, fifty consecutive pediatric patients who needed right sided interventional or diagnostic cardiac catheterization in affiliated hospitals of Shiraz University of Medical Sciences, Shiraz, Iran (Nemazee and Faghihi Hospitals) were enrolled in this study. Patients with Common atrium or large atrial septal defects or interrupted IVC were excluded from the study.

Echocardiography was performed with a GE vivid 3, 3 MHz probe. IVC size was recorded by M-mode echocardiography in sub-costal view in inspiration and expiration. Pressure measurements were done by Siemens 449 xi set (Siemens, Munich, Germany) and GE (Imaging technique, USA), angiographic machines.

Patients were categorized into two groups according to their mean right atrial pressure (RAP) that was measured by cardiac catheterization, Group 1 were those with mean RAP <8 mmHg and group 2 who had mean RAP  $\geq$  8mmHg. Echocardiographic data obtained from each patient were compared with the result of cardiac catheterization.

The study was approved by the ethics committee at the Shiraz University of Medical Sciences and written informed consents were obtained from the parents. All data are expressed as means  $\pm$  one standard deviation (SD); linear regression was used to examine the relationship between echocardiographic parameters and angiographic mean right atrial pressure. Pearson product moment correlation was used to compare values obtained by the two methods. Linear correlation was also tested using the Spearman rank method (correlation coefficient with 95% confidence interval). A receiver operating characteristic (ROC) curve was generated for statistically significant echocardiographic parameters, varying the discriminating thresholds of these parameters to determine the ability of mean right atrial pressure to discriminate between patients with a high right atrial pressure and those without it. Statistical analysis was done using MedCalc® 8.0 software.

## Findings

From fifty pediatric patients who enrolled in this study 30 patients were males and 20 were females. Mean age of the patients  $\pm$  one standard deviation was 4.96 ( $\pm$ 4.05) years, mean body surface area of 0.56 ( $\pm$ 0.25) and the following is the list of the clinical diagnoses of these patients: tetralogy of Fallot [23 patients (pts)], ventricular

septal defect (10 pts), pulmonary stenosis (3 pts), atrial septal defect and pulmonary stenosis (2 pts), primary pulmonary hypertension (4 pts), dilated cardiomyopathy (1 pt), ventricular and atrial septal defect (2 pts), coronary fistula (1 pt), patent ductus arteriosus (1 pt), patent ductus arteriosus and coarctation of aorta (1 pt), transposition of great artery and pulmonary stenosis (2 pts).

Patients were categorized into two groups according to their mean right atrial pressure (RAP) that was measured by cardiac catheterization, Group 1 (40 patients) were those with mean RAP <8 mmHg and group 2 (10 patients) who had a mean RAP  $\geq$  8mmHg.

Mean IVC size in inspiration was  $0.42 \pm 0.19$  cm and  $0.28 \pm 0.06$  cm,  $P=0.004$  in group 1 and 2 respectively; mean IVC size in expiration were  $0.83 \pm 0.26$  cm and  $0.61 \pm 0.14$  cm,  $P=0.009$  respectively. The ratio of mean IVC size to body surface area in inspiration in group 1 and 2 were  $0.83 \pm 0.48$  and  $0.64 \pm 0.12$ ,  $P=0.118$ ; in expiration these ratios were  $1.62 \pm 0.69$  and  $1.31 \pm 0.25$ ,  $P=0.117$  respectively.

ROC curves showed that if IVC size in inspiration was more than 3.6 mm right atrial pressure was more than 8 mmHg with a sensitivity and specificity of 100%, 47% and +likelihood ratio (LR)=1.9 respectively (Fig. 1).

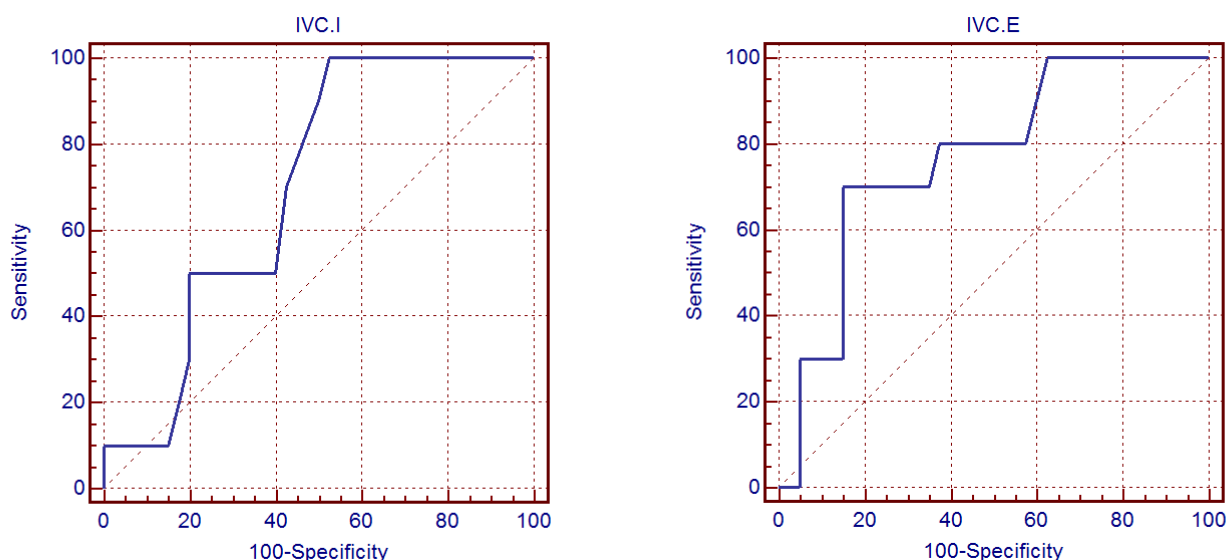
If IVC size in expiration was more than 6 mm, right atrial pressure was more than 8 mmHg with a sensitivity and specificity of 70%, 85% and +LR=4.67 respectively (Fig. 1).

Pearson correlation between percent of IVC collapse during respiratory phase and mean right atrial pressure showed  $r=0.23$ ,  $P=0.108$ .

## Discussion

This study reveals that IVC size in inspiration and expiration in children, easily measured in sub-costal view can predict high atrial pressure in patients with different types of congenital heart diseases.

Estimation of RAP is helpful in the overall management of patients with hemodynamic disorders and in the derivation of pulmonary artery pressure or left atrial pressure with Doppler echocardiography [5]. Several methods have been proposed for estimation of right atrial pressure for which right ventricular systolic pressure should be measured echocardiographically. Clinical estimation of the venous pressure has been used, but prospective studies have shown that it is inaccurate<sup>[19,20]</sup>. A constant



**Fig. 1:** Sensitivity and specificity of IVC diameter in inspiration (left) and expiration (right) for estimation of RA pressure

value of 14 mm Hg has been derived from a regression analysis comparing the tricuspid regurgitant velocity with direct catheter measurement of right ventricular systolic pressure in a large number of patients [21].

However, this method is not applicable to individual patients, especially those with abnormal pulmonary artery and right atrial pressures [6].

Measurement of IVC diameters and its changes during an inspiratory effort, commonly known as a sniff test, is used frequently in echocardiography laboratories to estimate RAP [16]. Its use however is limited in tachypneic patients and those on mechanical ventilation [17].

Another limitation is the difficulty of standardizing the inspiratory effort. Previous studies have demonstrated a good correlation between the collapse index of the inferior vena cava and RAP in adult patients without assisted ventilation [16]. In patients with mechanical ventilation, however, IVC collapse has been shown to correlate poorly to mean RAP ( $r=0.13$  and maximal caval diameter has only a weak correlation with mean RAP in these patients ( $r=0.58$ ) [17].

In a study by Kircher BJ, et al in adult patients caval index greater than or equal to 50% indicated RA pressure less than 10 mmHg, and caval indexes less than 50% indicated RA pressure greater than or equal to 10 mmHg [16].

A critical value of the index of the inspiration diameter of the inferior vena cava greater than or equal to 10 mm indicated patients with a pathologically elevated pressure in the right atrium with a 100% sensitivity and 88.9% specificity. Measurement of the diameter of the inferior vena cava and its respiratory variations is a suitable method for estimation of the mean right atrial pressure in adults [22]. Presented study demonstrated that a net value of IVC size larger than 6 mm can predict a mean right atrial pressure of more than 8 mmHg with sensitivity and specificity of 70%, 85% and  $+LR=4.67$  which is not as accurate as those in adults. This discrepancy may be due to different patient size and differences in hemodynamics in various congenital heart diseases.

Ultrasonographic measurements of IVC diameter and inspiratory movements are

quantifiable and reliable method for assess onset of hypervolemia associated with congestive heart failure.

Normalization of inspiratory IVC collapse movement correlates with successful diuretic therapy and can be reliably used for bedside assessment and monitoring treatment in patients with CHF [23].

Caval index was inversely correlated with mean central venous pressure (CVP). A caval index  $> 20\%$  indicated normal CVP. A caval index  $< 20\%$  is related to an elevated value of CVP. This method appears to be useful for accurate noninvasive estimation of mean CVP [24].

The present study showed poor correlation between IVC caval index and RA pressure but relatively fine correlation between IVC size in inspiration and expiration and mean RA pressure, this difference with previous studies in adult patients may be due to heterogeneity of congenital heart anomalies, difference in body size, rapid and uncontrollability of respiratory cycle in pediatric patients.

The relatively small sample size, different pathologic CHD, and wide age range may be a limitation of this study; hopefully, this report may initiate more research in this field.

## Conclusion

It is emphasized that the noninvasive method described here can be used in children with various CHD for estimation of RAP when invasive methods are not desirable.

## Acknowledgment

The authors thank the Office of Vice Chancellor for Research of Shiraz University of Medical Sciences for financial support of this study. They also thank Professor Gholamhossein Amirhakimi for thoughtful reviewing of the manuscript.

**Conflict of Interest:** None.

## References

- Kimball RT, Michelfelder EC. Echocardiography. In: Allen HD, Driscoll DJ, Shaddy RE, Feltes TF (editors). *Moss and Adams' Heart Disease in Infants, Children, and Adolescents: Including the Fetus and Young Adults*, 7<sup>th</sup> ed. Lippincott Williams & Wilkins. 2008; Pp: 95-158.
- Miyatake K, Okamoto M, Kinoshita N, et al. Pulmonary regurgitation studied with the ultrasonic pulsed Doppler technique. *Circulation*. 1982;65(5):969-76.
- Yock PG, Popp RL. Noninvasive estimation of right ventricular systolic pressure by Doppler ultrasound in patients with tricuspid regurgitation. *Circulation*. 1984;70(4):657-62.
- Currie PJ, Seward JB, Chan KL, et al. Continuous wave Doppler determination of right ventricular pressure: a simultaneous Doppler-catheterization study in 127 patients. *J Am Coll Cardiol*. 1985;6(4):750-6.
- Chan KL, Currie PJ, Seward JB, et al. Comparison of three Doppler ultrasound methods in the prediction of pulmonary artery pressure. *J Am Coll Cardiol*. 1987;9(3):549-54.
- Ommen SR, Nishimura RA, Hurrell DG, et al. Assessment of right atrial pressure with 2-dimensional and Doppler echocardiography: A simultaneous catheterization and echocardiographic study. *Mayo Clin Proc*. 2000;75(1):24-9.
- Fujii J, Yazaki Y, Sawada H, et al. Noninvasive assessment of left and right ventricular filling in myocardial infarction with a two dimensional Doppler echocardiographic method. *J Am Coll Cardiol*. 1985;5(5):1155-60.
- Nishimura RA, Abel MD, Hatle LK, Tajik AJ. Assessment of diastolic function of the heart: background and current applications of Doppler echocardiography, part II: clinical studies. *Mayo Clin Proc*. 1989;64(2):181-204.
- Klein AL, Hatle LK, Burstow DJ, et al. Comprehensive Doppler assessment of right ventricular diastolic function in cardiac amyloidosis. *J Am Coll Cardiol*. 1990;15(1):99-108.
- Goldstein JA, Tweddell JS, Barzilai B, et al. Right atrial ischemia exacerbates hemodynamic compromise associated with experimental right ventricular dysfunction. *J Am Coll Cardiol*. 1991; 18(6):1564-72.
- Sivaciyan V, Ranganathan N. Transcutaneous Doppler jugular venous flow velocity recording. *Circulation*. 1978;57(5):930-9.
- Appleton CP, Hatle LK, Popp RL. Demonstration of restrictive ventricular physiology by Doppler echocardiography. *J Am Coll Cardiol*. 1988; 11(4):757-68.
- Hatle LK, Appleton CP, Popp RL. Differentiation of constrictive pericarditis and restrictive cardiomyopathy by Doppler echocardiography. *Circulation*. 1989;79(2):357-70.
- Amozgar H, Zare K, Ajami GH, et al. Relation of mean right atrial pressure to Doppler parameters of right atrial and hepatic venous flow in pediatric patients with congenital heart disease. *Iran J Pediatr*. 2009;19(3):224-30.
- Simonson JS, Schiller NB. Sonospirometry: a new method for noninvasive estimation of mean right atrial pressure based on two-dimensional echographic measurements of the inferior vena cava during measured inspiration. *J Am Coll Cardiol*. 1988;11(3):557-64.
- Kircher BJ, Himelman RB, Schiller NB. Noninvasive estimation of right atrial pressure from the inspiratory collapse of the inferior vena cava. *Am J Cardiol*. 1990;66(4):493-6.
- Jue J, Chung W, Schiller NB. Does inferior vena cava size predict right atrial pressures in patients receiving mechanical ventilation? *J Am Soc Echocardiogr*. 1992;5(6):613-9.
- Luca L, Mario P, Giansiro B, et al. Non invasive estimation of mean right atrial pressure utilizing the 2D-Echo transverse diameter of the left hepatic vein. *Int J Card Imaging*. 1992;8(3):191-5.
- Eisenberg PR, Jaffe AS, Schuster DP. Clinical evaluation compared to pulmonary artery catheterization in the hemodynamic assessment of critically ill patients. *Crit Care Med*. 1984; 12(7):549-53.
- Yock PG, Popp RL. Noninvasive estimation of right ventricular systolic pressure by Doppler ultrasound in patients with tricuspid regurgitation. *Circulation*. 1984;70(4):657-62.
- Currie PJ, Seward JB, Chan KL, et al. Continuous wave Doppler determination of right ventricular pressure: a simultaneous Doppler-catheterization study in 127 patients. *J Am Coll Cardiol*. 1985;6(4):750-6.
- Veselka J, Mrázek V, Bartůněk P. Estimation of the mean right atrial pressure using echocardiography. *Vnitr Lek*. 1997;43(2):70-3.
- Hollerbach S, Schultze K, Muscholl M, Scholmerich J. Ultrasonography of the inferior vena cava (IVC) in the diagnosis and monitoring of therapy in patients with chronic congestive heart failure. *Dtsch Med Wochenschr*. 2001; 126(6):129-33.
- Minutiello L. Non-invasive evaluation of central venous pressure derived from respiratory variations in the diameter of the inferior vena cava. *Minerva Cardioangiol*. 1993;41(10):433-7.