

Diphallus with Imperforate Anus and Complete Duplication of Recto-Sigmoid Colon and Lower Urinary Tract

Alireza Mirshemirani^{1*} MD; Fatollah Roshanzamir¹ MD; Shahnaz Shayeghi²MD;
Leily Mohajerzadeh¹ MD and Shaghayegh Hasas-yeganeh¹MD

1. Pediatric Surgery Research Center, Mofid Children's Hospital, Shaheed Beheshti University of Medical Sciences, Tehran, IR Iran
2. Department of Pediatric Anesthesiology, Mofid Children's Hospital, Shaheed Beheshti University of Medical Sciences, Tehran, IR Iran

Received: Mar 06, 2009; Final Revision: Aug 23, 2009; Accepted: Sep 06, 2009

Abstract

Background: Diphallus is a rare anomaly and accompanying anomalies vary from bifid scrotum, bladder exstrophy, imperforate anus and colo-rectal anomaly such as duplication, and other associated anomalies.

Case Presentation: A 2-day old infant is reported with imperforate anus and complete duplication of recto-sigmoid colon, rectal pouch, doubling of the genitalia with completely formed penis (diphallus), double bladder, urethra and hypospadias. No family history of abnormalities was noted. The patient underwent several operations: laparotomy and colostomy at 3rd day of life, and after clinical and paraclinical investigations, cystoplasty, ureteral reimplantation and resection of left phallus were carried out when 4 months old. At the age of 1 year, after colostogram and total colon evaluation, laparotomy, resection of duplicated recto-sigmoid colon, and pull-through was carried out; 3 months later colostomy closure was performed and the patient discharged without complications.

Conclusion: The patients with diphallus have to be examined carefully because of the high incidence of other systemic anomalies. Treatment of diphallus usually includes excision of the duplicated penile structure, its urethra, and repair of associated anomalies.

Iranian Journal of Pediatrics, Volume 20 (Number 2), June 2010, Pages: 229-232

Key Words: Imperforate Anus; Hindgut duplication; Double bladder; Diphallus; Colo-rectal anomaly

Introduction

Duplications of the digestive tract are uncommon [1,2]. Rectal duplication is extremely

rare, accounting for only 1% to 8% of duplications. The etiology is due to an alteration during embryonic development, but is still not completely understood [3,4].

* Corresponding Author;

Address: Department of Pediatric Surgery and Research Center, Mofid Children's Hospital, Shariati St, Tehran, IR Iran

E-mail: almirshemirani@gmail.com

© 2010 by Pediatrics Center of Excellence, Children's Medical Center, Tehran University of Medical Sciences, All rights reserved.

Diphallus or duplication of the penis is a rare anomaly that occurs once in every 5 million live births^[5]. The extent of diphallus and the number of accompanying anomalies vary from bifid scrotum, bladder exstrophy and imperforate anus. We herein discuss a 2-day old male newborn with imperforate anus, complete duplication of colon, rectal pouch, diphallus and double bladder and urethra.

Case Presentation

A 2-day old male newborn was referred to us because of distended abdomen, abnormal genitalia and imperforate anus. He was the first child of family after 10 years marriage. The antenatal history was uneventful, and investigations were negative for other associated anomalies postnatally. The birth history was normal. The parents were relatives. Examination of genitalia revealed a well formed double penis with normally located and functioning urethra, left penis had proximal hypospadias.

There were normal penile shaft and bifid scrotum with each compartment containing a testicle (Fig. 1). Perineal examination showed imperforate anus. The values of blood analysis were within normal ranges. Abdominal sonography showed distended bowel loops and bilateral normal kidneys. The day after admission he underwent laparotomy and colostomy, the colon was distended and duplicated (Fig. 2).

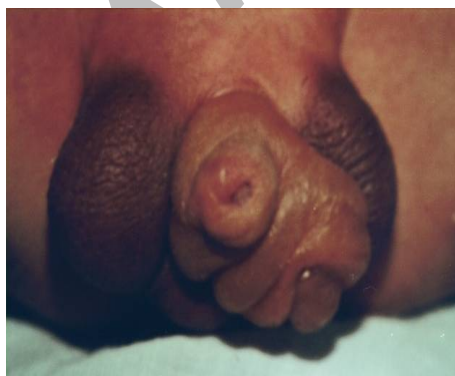

Fig. 1: Diphallus and bifid scrotum

2 months later, we performed an intravenous pyelography which showed normal kidneys and ureters. Voiding-cystourethrography revealed double bladder and urethra, but no vesicourethral reflux.

At 4 months of age surgical exploration of genitourinary tract showed abnormal position of bladder and urethra (Fig. 3). We performed cystoplasty, and reimplantation of left ureter in a single bladder (Fig. 4). Left side urethra with hypospadias was resected and bifid scrotum repaired. Post-operative days passed without complication so that the patient could be discharged 2 weeks later.

At the age of one year, after colostogram and total colon evaluation, laparotomy, resection of duplicated recto-sigmoid colon and pull-through, and 3 months later colostomy closure was carried out. He was under observation until the age of 4 years when his parents decided to leave Iran due to family problems.

Discussion

Duplication of the digestive tract is uncommon^[1,2], and they may be associated with different congenital anomalies such as anorectal malformation and lower genitourinary abnormalities^[6]. The most common type of colorectal duplication is the cystic form, which localizes in the retrorectal area^[7,8] and may therefore be confused with teratoma, dermoid cyst and anterior meningocele^[9,10]. In the

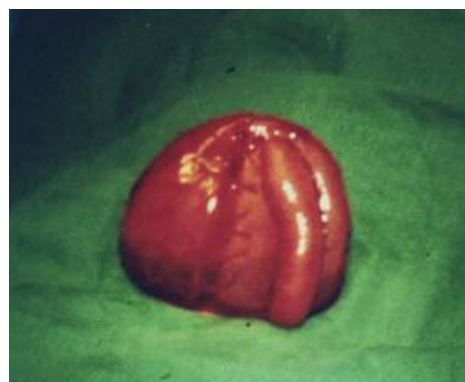

Fig. 2: Distended and duplicated colon

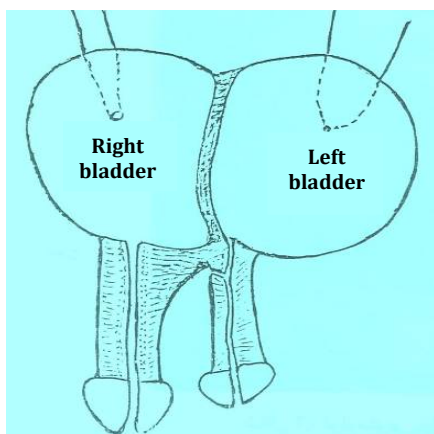


Fig. 3: Abnormalities of bladder and urethra

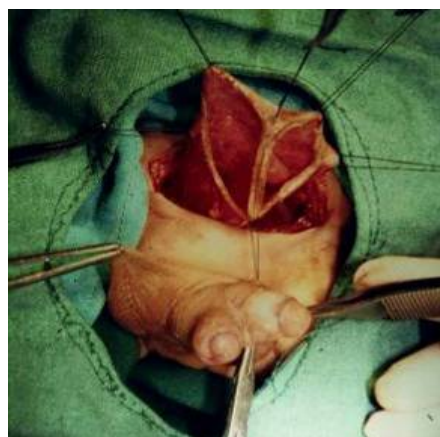

Fig. 4: Double bladder and urethra before reconstruction

present case, colon duplication was of tubular form. The etiology is due to an alternation during embryonic development, but is still not completely understood [3,4]. The surgical treatment of midgut duplication is mandatory [9]. Azmy has reported complete duplication of the hindgut which had two anal openings and a lower urinary tract with diphallus^[11].

In this case, there were complete duplication of recto-sigmoid colon, imperforate anus, doubling of bladder and urethra (diphallus), and bifid scrotum. Diphallus is a rare congenital anomaly occurring once in 5 million live births. The first case was reported in 1609^[12]. Schneider classified diphallus in three groups; diphallus of glans alone, bifid diphallus, and complete diphallus. Vilanova and Raventos have added a fourth category pseudodiphallus^[12,13]. The urethra shows a range of variations, ranging from functioning double urethras to complete absence of urethra in each penis^[14].

The majority has a single corpus cavernosum in each phallus^[12]. The meatus may be normal, epispadic, or hypospadiac, and the scrotum may be normal or bifid^[15]. Associated congenital anomalies are present in the majority of the cases^[11,12,14].

This reported case had imperforate anus, complete recto-sigmoid duplication (tubular type), doubling bladder, functioning double urethras, hypospadias in left side urethra, complete diphallus, and bifid scrotum. In this presented case we had different types of distal

urinary tract anomalies, also complete duplication of recto-sigmoid colon which is rare in literature. Treatment of diphallus usually includes excision of the duplicated penile structure and its urethra^[12,16]. Therefore; all the patients with diphallus have to be examined carefully because of the high incidence of other systemic anomalies.

Conclusion

The patients with diphallus have to be examined carefully because of the high incidence of other systemic anomalies.

Acknowledgment

The authors would like to thank Mr Koushan Kouranloo and Mrs M Saeedi for their kind help in preparing and typing the manuscript.

References

1. Basu R, Forshall I, Rickham PP. Duplications of the alimentary tract. *Br J Surg.* 1960;47(2):477-84.

2. Gross RE, Holcomb GH, Farber S. Duplications of alimentary tract. *Pediatrics*. 1952; 9(4):449-68.
3. Peter JC, Sinclair-Smith C, de Villiers JC. Midline dermal sinuses and cysts and their relationship to the central nervous system. *Eur J Pediatr*. 1991; 1(2):73-9.
4. Ravitch MM. Duplication of gastrointestinal tract. In: KJ Welch, JG Randolph, MM Ravitch, et al (editors). *Pediatric Surgery*. Vol 2. 4th ed. Chicago: Yearbook Med Publ. 1986; Pp: 911-20.
5. Viswanatha RT, Chandrasekharam V. Diphallus with duplications of cloacal derivatives. *J Urol*. 1980; 124:555-8.
6. Sarin YK, Manchanada V, Sharma A, et al. Triplication of colon with diphallus and complete duplication of bladder and urethra. *J Pediatr Surg*. 2006; 41(11):1924-6.
7. Laquaglia MP, Fenis N, Eraklis A, Hendren H. Rectal duplications. *J Pediatr Surg*. 1990; 25(9): 980-4.
8. Craigie, R, Abbarju J, Turnok R. Anorectal malformation with tubular hindgut duplication. *Pediatr Surg*. 2006; 41(6):e31-e34.
9. Sencan A, Mir E, Karaca 1, et al. Antero-lateral rectal duplication: case report. *Turkish J Gastroenterol*. 2000; 12(2):1-4.
10. Shivam Priyadrshi. Diphallus with ectopic bowel segment: a case report. *Ped Surg Int*. 2005; 21(8):681-3.
11. Azmy AF. Complete duplication of the hindgut and lower urinary tract with diphallus. *J Pediatr Surg*. 1990; 25(6): 647-9.
12. Abdulkadir T, Mert A, Unsal O, et al. Complete diphallus in a 14 year old boy. *Marmara Med J*. 2007; 20(3):190-2.
13. Vilanova X, Raventos A. Pseudodiphallia - a rare anomaly. *J Urol*. 1954; 71: 338-46.
14. Torres-Medina E, Sanchez-Puente JC, Tovar A, et al. Diphallia presentation and literature review. *Rev Mex Urol*. 2009; 69(1):32-5.
15. Altug U, Cakam M, Yalcinkay F. Evaluation and reconstruction of an extremely rare genitourinary abnormality. *Int Urol Nephrol*. 2007; 39:1191-3.
16. Carvalho AP, Ramires R, Soares J, et al. Surgical treatment of complete penile duplication. *Actas Urolog ESP*. 2008; 32(9):941-4.

Archive of SID