

Juvenile Churg-Strauss Syndrome as an Etiology of Myocarditis and Ischemic Stroke in Adolescents; a Case Report

Mohammad-Hassan Moradinejad^{1,2}, MD; Amir Rezaei², MD, and Vahid Ziaee^{*1,3}, MD

1. Department of Pediatrics, Tehran University of Medical Sciences, Tehran, Iran
2. Children's Medical Center, Pediatrics Center of Excellence, Tehran, Iran
3. Growth & Development Research Center, Tehran University of Medical Sciences, Tehran, Iran

Received: Mar 13, 2010; Final Revision: Jun 06, 2010; Accepted: Jul 05, 2010

Abstract

Background: Churg-Strauss syndrome (CSS), a systemic vasculitis accompanied by asthma and eosinophilia, almost invariably affects the lung and is frequently associated with cutaneous involvement. It rarely has cardiac involvement. We report an unusual case of CSS with myocardial involvement and stroke.

Case Presentation: A 16-year old female suffered of allergic asthma for 4 years. She was under treatment with oral prednisolone and seretide inhalation. After CSS diagnosis, she developed paroxysmal atrial tachycardia. Serum levels of Troponin I and Troponin T were increased indicating massive myocardial damage probably due to myocarditis. After 5 months she developed acute hemiparesis without any evidence of ischemic or hemorrhagic event. She was treated with IVIg, intravenous pulses of methylprednisone and cyclophosphamide for each complication.

Conclusion: Myocarditis and stroke may also complicate CSS which should be taken in consideration for better management.

Iranian Journal of Pediatrics, Volume 21 (Number 4), December 2011, Pages: 530-534

Key Words: Asthma; Churg-Strauss Syndrome; Vasculitis; Myocarditis; Stroke

Introduction

Churg-Strauss syndrome (CSS) is a multisystem disorder characterized by allergic rhinitis, asthma and peripheral blood eosinophilia^[1]. This systemic vasculitis affects small and medium-sized blood vessels^[2]. The American College of Rheumatology

(ACR) has described 6 clinical diagnostic criteria, 4 of which are necessary for classifying the disease as CSS. These criteria include asthma, eosinophilia (>10% of differential WBC count), mononeuropathy or polyneuropathy, transient pulmonary infiltrates on chest X-ray (CXR), paranasal sinus abnormalities, and nasal mucosa, lung and

* Corresponding Author;

Address: کتبه، خیابان ولیعصر، تهران، ایران
E-mail: v.ziaee@tums.ac.ir

© 2011 by Pediatrics Center of Excellence, Children's Medical Center, Tehran University of Medical Sciences, All rights reserved.

paranasal sinuses in biopsy containing a blood vessel with extravascular eosinophils^[3]. The presence of 4 or more of these 6 criteria yielded a sensitivity of 85% and a specificity of 99.7%. Some cases may only have 2 or 3 criteria; however, their physicians are still comfortable classifying their disease as CSS^[3,4].

CSS is generally reported in adults but very rarely in children^[5]. Both men and women are equally affected^[6]. The disease usually has three sequential phases^[7,8]: (1) the allergic phase which is characterized by allergic inflammation of the nose, paranasal sinuses, and lungs; (2) the hypereosinophilic phase; and (3) the systemic vasculitis phase^[9,10].

The exact etiology of CSS is still unknown, but it probably is multifactorial. Genetics may play a small role, environmental factors such as infection, and exposure to industrial solvents seem to play a more important role in susceptibility to this disease^[11-13]. It is due to the presence of anti-neutrophil cytoplasmic antibodies (ANCA) based on one hypothesis and increased cytokines such as interferon alpha (INF- α), interleukin-1 (IL-1), IL-2, and tumor necrosis factor alpha (TNF- α) based on another hypothesis^[13-15].

Asthma is one of the cardinal features of CSS. Symptoms of asthma and allergic rhinitis may begin before the onset of vasculitis. The second most common involved organ is skin, which presents with rashes and nodules. Cardiac involvement is rare which may be subclinical or present with severe signs and symptoms of arrhythmias, myocarditis, valvulitis, pericarditis, and heart failure^[16-18]. Despite rarity, cardiac involvement is a major cause of morbidity and mortality in patients with CSS^[19,20].

Similar other granulomatous vasculitis such as Takayasu, CSS is a rare vasculitis in Iranian children and there is a few report on this types of vasculitis from Iran^[21,22,23]. Herein we report a young girl with allergic rhinitis and asthma who developed myocardial involvement and stroke in the course of the disease.

Case Presentation

A 16-year-old female with a history of allergic

rhinitis, sinusitis, and chronic asthma since 4 years ago was admitted in our service to rule-out CSS. She was under treatment with oral prednisolone and seretide inhalation to control her severe asthma, and antibiotics for recurrent sinusitis. She had fatigue, malaise, muscle weakness, general musculoskeletal pain, exertion dyspnea, and weight loss at admission.

She also had two previous hospital admissions for pneumonia during the past year. Physical examination at admission revealed auxiliary temperature 37°C, respiratory rate 25/min, pulse rate 90/min and blood pressure 120/80 mmHg. Except for a Cushingoid face, physical findings were unremarkable.

CXR revealed bilateral reticular and alveolar opacities. Heart size was within normal limits. Pulmonary function test (spirometry) was acceptable indicating controlled asthma. Electromyography and nerve conduction velocity also were normal. Bone mass densitometry disclosed osteoporosis.

Laboratory findings at admission showed leukocytosis (WBC count $19.0 \times 10^9/L$) with eosinophilia (eosinophils $8.12 \times 10^9/L$), hemoglobin 11.5 g/dL, normal platelet count, negative rheumatoid factor, normal IgG, IgA, and IgM levels but raised IgE level (157 IU/mL, normal level <144), ESR 72 mm/h (normal range, 4-14 mm/h), C-reactive protein 4.0 mg/dL (normal range, 0.01-2 mg/dL), positive ANCA (C-ANCA 1.5 U/mL, P-ANCA 1.5 U/mL), negative anti-dsDNA, negative F-ANA, and negative cryoglobulin.

We decided to taper the dose of prednisolone because of Cushingoid face and osteoporosis. She developed vomiting and tachycardia (rate 160/min) one week after admission. BP was normal. A systolic murmur grade 2/6 was heard at apex. Electrocardiogram revealed paroxysmal atrial tachycardia (Fig. 1). Echocardiography disclosed dilated cardiomyopathy with systolic and diastolic dysfunction; systolic ejection fraction was about 24%-43%. The patient was transferred to intensive care unit. Serum levels of myocardial enzymes were as follow: Troponin I 0.8 ng/mL (normal value <0.1) and Troponin T 0.45 ng/mL (normal value <0.2) indicating massive myocardial damage probably due to myocarditis.

She received one pulse of intravenous immunoglobulin, three pulses of methyl-

prednisolone and one pulse of cyclophosphamide in addition to cardiac inotropic agents and treatment for heart failure.

High resolution chest CT scan showed nonspecific findings. She was discharged after three weeks with stable cardiac condition.

Five months after the previous admission, she was readmitted for acute hemiparesis of right side of her face and left side of the body in favor of right hemisphere stroke. Brain CT scan did not show any hemorrhagic changes, but brain MRI showed signal changes lesion in cortex of right temporoparietal lobes due to ischemia (Fig. 1). The patient was treated with pulses of methylprednisolone and cyclophosphamide promptly together with physiotherapy. The left lower limb and then her face improved during 10 days but she had some disability in her left arm on discharge.

After control of stroke, the treatment continued with oral prednisolone (1mg/kg) and azathioprine. She also underwent brain magnetic resonance angiography being suspect of vasculitic involvement of brain vessels. Physical rehabilitation continued for hemiparesis and after 2 years follow up, her disease was under control with minimal hemiparesis symptom. Prednisolone was reduced gradually to physiologic dose (7.5 mg/day).

Discussion

Churg-Strauss syndrome is a systemic vasculitis; patients have a history of asthma averaging 28 months (range 6 to 40 months) prior to the initial symptom of vasculitis and marked peripheral blood eosinophilia [1,2]. We described a patient who met 4 diagnostic criteria of CSS in children established by ACR, including a history of severe asthma, recurrent sinusitis, pulmonary infiltrates, and eosinophilia [3]. CSS in our patient coincided with tapering of prednisone dosage leading to cardiac involvement presented with tachycardia and myocarditis.

CSS is an uncommon entity which is rarely reported in children [3-5]. Its etiology is still unknown, allergic or immune complexes are the most important suggested pathogenesis for the disease [10,11]. Asthma is the central feature of CSS and elevated level of serum IgE, as in our patient, is seen in some cases [8,9].

The rate of clinical cardiac involvement in children CSS is not clear but in adults CSS has been reported 44.9% in Neumann et al case series [24]. The rate was 90% by paraclinical investigations in Szczeklik et al study [25]. However, myocarditis as a complication of CSS in children is very rare. The prevalence of myocarditis was 22% and 40% in two case series in adult CSS. Courand et al have

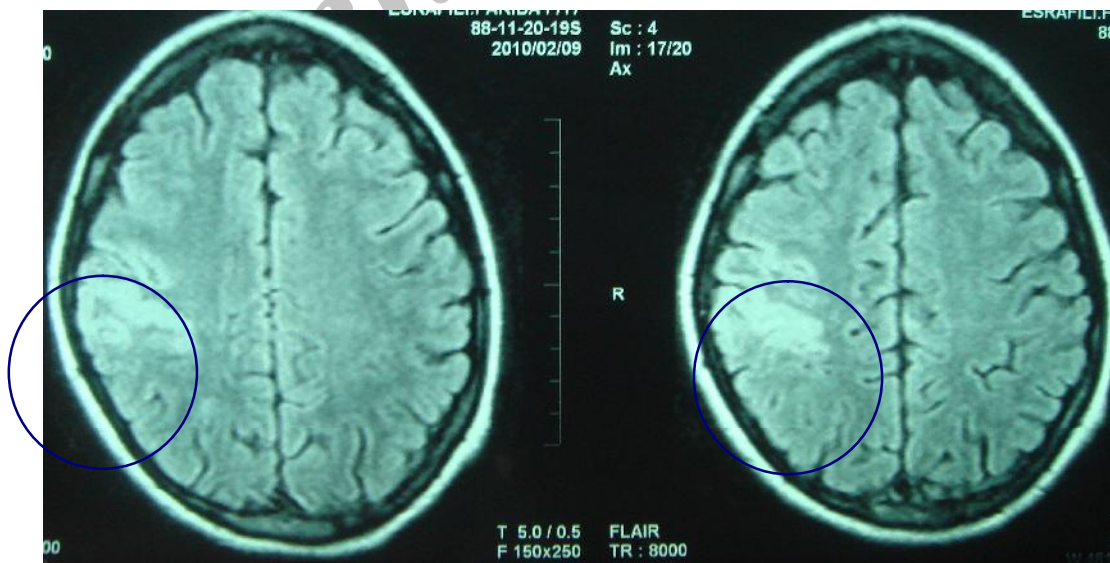


Fig. 1: signal changes lesion in cortical of right temporoparietal lobes due to ischemia in patient with Churg-Strauss syndrome

reported a young man with myocarditis as the first diagnostic presentation of CSS [26]. Myocarditis in CSS may be due to tissue eosinophil infiltration or vasculitis [27]. In our case eosinophilia was controlled by treatment before, so it may be due to vasculitis. There are several reports of using endomyocardial biopsy to determine the cause of decreased ventricular function in CSS [15-17]. Most cases of reported biopsies have been nondiagnostic [12-14]; however, at least one case of myocarditis has been diagnosed by this method [18]. Myocarditis has been diagnosed in our patient with increased serum levels of myocardial enzymes and reduced cardiac ejection fraction.

Cardiac involvement in CSS needs immediate and aggressive therapy by methyl-prednisolone and cyclophosphamide pulse [26]. Our patient responded to this treatment very well.

Extrathoracic manifestations of CSS include gastrointestinal involvement such as eosinophilic gastroenteritis which was not present in our patient. Development of gangrene is a rare complication of CSS which is often seen due to vaso-occlusion in association with anti-phospholipid antibodies [12-14]. This complication did not occur in our patient. CNS involvement and stroke is a rare complication of CSS that is an emergency in vasculitis.

Our patient had stroke as a rare complication of CSS in children. Neurologic involvement is common in adult CSS, but CNS involvement seems to be not common in CSS [28]. It is reported less than 10% in adult CSS and stroke is not a rare complication of CSS [29]. This may be due to primary CNS vasculitis or secondary to cardiac involvement. In addition it can be due to intracerebral bleeding secondary to vasculitis of the intracerebral arteries or abnormal coagulation [28]. We did not find any report on stroke in children and adolescent CSS. Similar other life-threatening complications of CSS, stroke must be treated with intravenous pulses of methylprednisone and cyclophosphamide and sometimes by IVIg and azathioprine [28,30].

Complications of CSS were treated in our patient with IVIg, intravenous pulses of methylprednisone and intravenous pulse of cyclophosphamide, and continued with prednisone and azathioprine. Most patients with CSS respond favorably to corticosteroid therapy.

Many cases will relapse over time, and may require indefinite steroid therapy. If a patient has difficulty being maintained on low dose steroids alone, it is usually preferable to add another immunosuppressive agent to the regimen in order to decrease the dose of the steroids to as low as possible [20]. Additional treatment options include inhaled steroids, cyclophosphamide (Cytoxan), azathioprine (Imuran), and high-dose intravenous immune globulin (IVIg) which has been used in patients with severe disease or diseases unresponsive to corticosteroids. These patients have also been improved with a regimen of corticosteroids and INF- α . Plasma exchange occasionally has been used in conjunction with other therapies [19,20].

Conclusion

Our patient showed the pathogenesis of severe vascular involvement in CSS, with myocarditis and stroke which should be taken into account in any patient for a better management.

Identification of the CSS spectrum will further aid in understanding the pathogenesis of the disease and might have an impact on its management and prognosis

References

1. Churg J, Strauss L. Allergic granulomatosis, allergic angiitis, and periarteritis nodosa. *Am J Pathol* 1951;27(2):277-301.
2. Abril A, Calamia KT, Cohen MD. The Churg Strauss syndrome (allergic granulomatous angiitis): review and update. *Semin Arthritis Rheum* 2003; 33(2):106-114.
3. Masi AT, Hunder GG, Lie JT, et al. The American College of Rheumatology 1990 criteria for the classification of Churg-Strauss syndrome (allergic granulomatosis and angiitis). *Arthritis Rheum* 1990; 33(8):1094-100.
4. Lanham JG, Elkon KB, Pusey CD, Hughes GR. Systemic vasculitis with asthma and eosinophilia: a clinical approach to the Churg-Strauss

- syndrome. *Medicine (Baltimore)* 1984;63(2):65-81.
5. Louthrenoo W, Norasetthada A, Khunamornpong S, et al. Childhood Churg-Strauss syndrome. *J Rheumatol* 1999; 26(6):1387-93.
 6. Harrold LR, Andrade SE, Go AS, et al. Incidence of Churg-Strauss syndrome in asthma drug users: a population-based perspective. *J Rheumatol* 2005; 32(6):1076-80.
 7. Noth I, Streck ME, Leff AR. Churg-Strauss syndrome. *Lancet* 2003; 361(9357):587-94.
 8. Sharma BK, Daga MK, Sharma M. A limited form of Churg-Strauss syndrome presenting without asthma and eosinophilia. *Med J Aust* 2004;181(9): 498-9.
 9. Hellmich B, Ehlers S, Csernok E, Gross WL. Update on the pathogenesis of Churg-Strauss syndrome. *Clin Exp Rheumatol* 2003; 21 (6 suppl 32) :S69-77.
 10. Virgin HW. Host and viral genes that control herpes virus vasculitis. *Cleve Clin J Med* 2002; 69(Suppl 2):7-12.
 11. Naides SJ. Known causes of vasculitis in man. *Cleve Clin J Med* 2002; 69(Suppl 2): SII15-19.
 12. Tervaert JW. Infections in primary vasculitides. *Cleve Clin J Med* 2002; 69(Suppl 2):SII24-6.
 13. Boyer D, Vargas SO, Slattery D, et al. Churg-Strauss syndrome in children: a clinical and pathologic review. *Pediatrics* 2006;118(3):e914-e920.
 14. Gotlib J. Molecular classification and pathogenesis of eosinophilic disorders: 2005 update. *Acta Haematol* 2005;114(1):7-25.
 15. Hasley PB, Follansbee WP, Coulehan JL. Cardiac manifestations of Churg-Strauss syndrome: report of a case and review of the literature. *Am Heart J* 1990;120(4):996-9.
 16. Gross WL. Churg-Strauss syndrome: update on recent developments. *Curr Opin Rheumatol* 2002; 14(1):11-4.
 17. Le Gall C, Pham S, Vignes S, et al. Inhaled corticosteroids and Churg-Strauss syndrome: a report of five cases. *Eur Respir J* 2000;15(5):978-81.
 18. Cooper SM, Libman BS, Lazarovich M. Churg-Strauss syndrome in a group of patients receiving fluticasone for asthma. *J Rheumatol* 2002;29(12): 2651-2.
 19. Cohen P, Guillevin L, Baril L, et al. Persistence of antineutrophil cytoplasmic antibodies (ANCA) in asymptomatic patients with systemic polyarteritis nodosa or Churg-Strauss syndrome: Follow-up of 53 patients. *Clin Exp Rheumatol* 1995;13(2):193-8.
 20. Guillevin L, Jarrousse B, Lok C, et al. Longterm follow up after treatment of polyarteritis nodosa and Churg-Strauss angiitis with comparison of steroids, plasma exchange and cyclophosphamide to steroids and plasma exchange. A prospective randomized trial of 71 patients. The Cooperative Study Group for Polyarteritis Nodosa. *J Rheumatol* 1991;18(4):567-74.
 21. Moradinejad M, Ziaee V, Kiani A, et al. Report on takayasu arteritis in three Iranian children. *Iran J Pediatr* 2009;19(3):307-12.
 22. Otukesh H, Fereshtehnejad S, Hoseini R, et al. Extensive Myocardial Infarction in a Child with Takayasu Vasculitis: Report of a Case. *Iran J Pediatr* 2008;18(4):364-8.
 23. Kashef S, Alyasin S, Kiani M, et al. Churg-strauss syndrome in an 8-year-old girl. *Iran J Allergy Asthma Immunol* 2004;3(1):41-3.
 24. Neumann T, Manger B, Schmid M, et al. Cardiac involvement in Churg-Strauss syndrome: impact of endomyocarditis. *Medicine (Baltimore)* 2009; 88(4):236-43.
 25. Szczeklik W, Miszalski-Jamka T, Mastalerz L, et al. Multimodality assessment of cardiac involvement in Churg-Strauss syndrome patients in clinical remission. *Circ J* 2011;75(3):649-55.
 26. Courand PY, Croisille P, Khouatra C, et al. Churg-Strauss Syndrome Presenting with Acute Myocarditis and Cardiogenic Shock. *Heart Lung Circ* 2011 Sep 29. [Epub ahead of print]
 27. Holle JU, Moosig F, Gross WL. Diagnostic and therapeutic management of Churg-Strauss syndrome. *Expert Rev Clin Immunol* 2009;5(6): 813-23.
 28. Wolf J, Bergner R, Mutallib S, et al. Neurologic complications of Churg-Strauss syndrome--a prospective monocentric study. *Eur J Neurol* 2010;17(4):582-8
 29. Finsterer J. Neurological manifestations of Churg-Strauss syndrome. *Eur J Neurol* 2010;17(4):524-5.
 30. Sairanen T, Kanerva M, Valanne L, et al. Churg-strauss syndrome as an unusual aetiology of stroke with haemorrhagic transformation in a patient with no cardiovascular risk factors. *Case Rep Neurol* 2011;3(1):32-8.