

Perforation of Meckel's Diverticulum by a Peanut Presenting as a Mesentery Abscess

Chia-Hung Su¹, MD; Jui-Ying Lee^{1,2}, MD; Yu-Tang Chang^{*1,2,3}, MD

1. Department of Surgery, Kaohsiung Medical University Hospital, Taiwan
2. Graduate Institute of Medicine, College of Medicine, Taiwan
3. Department of Surgery, Graduate Institute of Medicine, College of Medicine, Kaohsiung Medical University, Kaohsiung, Taiwan

Received: Apr 04, 2011; Accepted: Jan 13, 2012; Final Revision: Jan 12, 2013

Abstract

Background: Perforation of Meckel's diverticulum by a foreign body in children is rarely reported and is usually associated with localized or generalized fibropurulent peritonitis.

Case Presentation: The authors encountered such a case in a 4-year-old boy with perforation of Meckel's diverticulum by a piece of peanut presenting as a mesentery abscess. The diverticulum was wide-based and histology showed a transmural perforation at the tip of the diverticulum.

Conclusion: Local inflammation due to irritation of the foreign body and progressive pressure necrosis at the tip of the diverticulum may be the pathogenesis of mesentery abscess. A search of the English literature did not reveal any similar case.

Iranian Journal of Pediatrics, Volume 23 (Number 2), Apr 2013, Pages: 223-225

Key Words: Meckel's Diverticulum; Peanuts; Intestinal Perforation; Mesentery; Abscess

Introduction

Meckel's diverticulum results from an incomplete obliteration of the omphalomesenteric or vitelline duct and is the most common congenital gastrointestinal anomaly. The incidence of Meckel's diverticulum is about 2% in the general population and most of these are usually asymptomatic. The total life complication rate has been reported to be around 4%^[1]. Inflammation, hemorrhage, and intestinal obstruction are the most common complications. Perforation of Meckel's diverticulum is less common^[2], and the incidence varies between 7.3% and 26.7%^[1,3,4]. Herein, the authors present a case of a 4-year-old boy with perforation of Meckel's diverticulum by a peanut presenting as a mesentery abscess.

Case Presentation

A 4-year-old 19-kg male child suffered from sudden onset of abdominal pain and fever for about 5 days. Parents reported no significant past medical or surgical history. On arrival at our hospital, the patient had stable hemodynamics with a body temperature of 37.4 °C, a pulse rate of 94 beats per minute, a blood pressure of 124/79mm Hg, and a decreased urine output. On physical examination, the abdomen was distended mildly, and bowel sound was absent. Abdominal tenderness to deep palpation in the right upper quadrant without rebounding pain was found. Rectal examination showed yellowish stool that was Hemocult-negative. Laboratory data were as follows: total white blood cell count, $17.2 \times 10^9/L$

*** Corresponding Author;**

Address: Division of Pediatric Surgery, Kaohsiung Medical University, 100 Tzyou 1st Road, Kaohsiung 80708, Taiwan
E-mail: 890300@ms.kmuh.org.tw

© 2013 by Pediatrics Center of Excellence, Children's Medical Center, Tehran University of Medical Sciences, All rights reserved.

www.SID.ir

with a significant left shift; hematocrit, 34.9%; serum amylase, 61U/L; serum lipase, 19U/L and serum C-reactive protein, 78.21 mg/mL. The abdominal radiograph showed normal bowel gas pattern and no abnormal free air was identified. Abdominal sonography showed a hypoechoic mass with debris. A computed tomographic scan of the abdomen with intravenous contrast showed an abscess measuring 22×25×24 mm in the small bowel mesentery (Fig. 1A). The appendix was not swelling.

In light of the abnormal image findings, it was decided that a surgical intervention should be performed; and a laparoscopic approach was elected. Laparoscopy was performed in supine position with a 5-mm Hasson port at the umbilicus and two 5-mm ports at the right upper and left lower quadrants. Video laparoscopy was performed with a 5-mm 30° laparoscope (Karl Storz GmbH, Tuttlingen, Germany). The cecum was initially identified and the entire small bowel was examined. Some serous fluid was observed in the peritoneal cavity. There was an abscess located in the small bowel mesentery right side of the abdomen. Then, the cavity of the abscess was opened attentively and the content was sucked out completely. A piece of peanut was found lying free in the cavity of the abscess (Fig. 2B), and the ileal loop and omentum had walled off an inflamed and perforated Meckel's diverticulum (Fig. 2B). Diverticulectomy and wedge resection of the ileum were performed. The anastomosis of the ileum was performed intracorporeally.

Histology confirmed the diagnosis of a perforated Meckel's diverticulitis with abscess formation. Macroscopically, the specimen

consisted of one enteric segment measuring 50 mm in length and maximal 20 mm in diameter (Fig. 2C). A perforation was found at the tip. On microscopic examination, it showed ulcerative intestinal mucosa with diffusely necrotizing inflammation, with acute and chronic inflammatory cells infiltrating transmurally and fibrinoid substance coating on the serosa. No recognizable ectopic mucosa was identified. The patient was discharged 4 days after operation and remains healthy without any sequelae on one-year follow-up at our outpatient clinic.

Discussion

Foreign bodies accidentally ingested are a potentially serious problem that peaks in children aged six months to three years^[5]. However, up to 90 percent of foreign bodies pass through the gastrointestinal tract without any consequences, regardless of their size, shape and composition^[5]. Such serious morbidity as bowel obstruction, perforation, and erosion into adjacent organs occur in less than one percent of all pediatric patients in the United States^[6]. Most perforations occur at the narrowing and angulations of the gastrointestinal tract, and the most common abdominal sites of perforation are the ileocecal and rectosigmoid regions^[7,8].

Perforation of Meckel's diverticulum is rare, representing only 0% and 1.6% of the total perforations of the gastrointestinal tract secondary to ingestion of foreign bodies in two

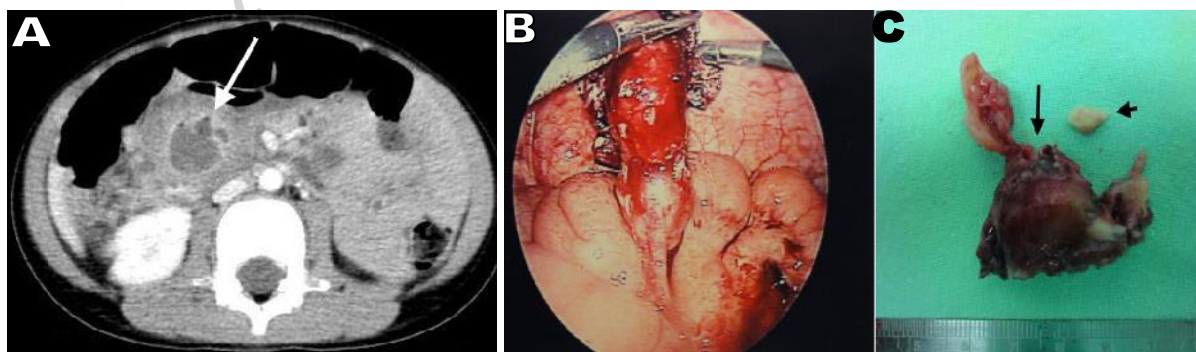


Fig. 1: A) An abdominal CT scan showing a peripheral-enhanced hypodense mass in the small bowel mesentery (arrow). B) At operation, an acutely inflamed Meckel's diverticulum was found. C) Resected specimen and a piece of peanut seed with sharp margins (arrowhead). Meckel's diverticulum had a demonstrably wide base and a perforation at the tip (arrow).

large series^[7,8]. In a large review of 52 complicated diverticula in adulthood, 8% were resected due to perforation by a foreign body^[9]. In addition, most are case reports and presented as local or diffuse fibropurulent peritonitis^[10]. Many bizarre foreign bodies have been reported to cause perforation and fish bones are the most common (55%)^[11]. Since a definitive preoperative history of ingestion of a foreign body is usually uncertain and the ingested foreign body would not be identified on image, an accurate diagnosis before operation may be difficult^[5]. However, all these cases eventually required a laparotomy and the postoperative recovery was excellent.

Small foreign bodies are not infrequently mis-swallowed by children. However, perforation of Meckel's diverticulum by a foreign body in childhood is extremely rarely seen. On reviewing the literature from 1965 to 2010, only 4 such cases have been reported, including a fish bone, a chicken bone and two button batteries^[12-15]. In the present case, a 4-year-old boy presented with symptoms of an intra-abdominal abscess, and laparoscopy revealed a perforation at the tip of Meckel's diverticulum and a piece of peanut in the abscess cavity. Upon further questioning, his parents stated that he had eaten peanuts two months before the onset of the symptoms.

Peanuts are found in a wide range of grocery products and were not thought to be ingested unintentionally by the boy. However, incomplete chewing while eating or a voracious appetite may lead to incomplete digestion thereby resulting in peanuts with sharp points and margins (Fig. 1). Besides, the diverticulum in the present case is a pouch with a wide base, and a small foreign body may move toward the tip of the diverticulum due to peristalsis. In the literature, impaction of an endocapsule and perforation may occur when a capsule remains in the gastrointestinal tract for more than 2 weeks^[16]. If an undigested peanut stays long-term in the Meckel's diverticulum, the impact of its sharp margin against the tip of the diverticulum might shatter the wall. Therefore, the location of the impaction/perforation and the length of retention time strongly suggest that the perforation was caused by the retained peanut. Moreover, local inflammation due to irritation of the foreign body and pressure necrosis of the wall secondary to attempts by peristalsis may thus be the pathogenesis of mesentery abscess.

Conclusion

The case report presented a rare complication in a child of Meckel's diverticulum perforated by a piece of peanut. Local inflammation and pressure necrosis of the wall may be the pathogenesis of mesentery abscess. Laparoscopic wedge resection and intracorporeal anastomosis were performed smoothly and the postoperative course was uneventful.

References

1. Uppal K, Tubbs RS, Matusz P, et al. Meckel's diverticulum: a review. *Clin Anat* 2011;24(4):416-22.
2. Chang YT, Lin JY, Huang YS. Spontaneous perforation of Meckel's diverticulum without peritonitis in the newborn: report of a case. *Surg Today* 2006;36(12):1114-7.
3. Yahchouchy EK, Marano A, Etienne JC, et al. Meckel's diverticulum. *J Am Coll Surg* 2001;192(5):658-62.
4. Matsagas MI, Fatouros M, Koulouras B, et al. Incidence, complications, and management of Meckel's diverticulum. *Arch Surg* 1995;130(2):143-6.
5. Uyemura MC. Foreign body ingestion in children. *Am Fam Physician* 2005;72(2):287-91.
6. Chen MK, Beierle EA. Gastrointestinal foreign bodies. *Pediatr Ann* 2001;30(12):736-42.
7. Goh BK, Chow PK, Quah HM, et al. Perforation of the gastrointestinal tract secondary to ingestion of foreign bodies. *World J Surg* 2006;30(3):372-7.
8. Rodríguez-Hermosa JI, Codina-Cazador A, Sirvent JM, et al. Surgically treated perforations of the gastrointestinal tract caused by ingested foreign bodies. *Colorectal Dis* 2008;10(7):701-7.
9. Groebli Y, Bertin D, Morel P. Meckel's diverticulum in adults: retrospective analysis of 119 cases and historical review. *Eur J Surg* 2001;167(7):518-24.
10. Yagci G, Cetiner S, Tufan T. Perforation of Meckel's diverticulum by a chicken bone, a rare complication: report of a case. *Surg Today* 2004;34(7):606-8.
11. Wong JH, Suhaili DN, Kok KY. Fish bone perforation of Meckel's diverticulum: a rare event? *Asian J Surg* 2005;28(4):295-6.
12. Karaman A, Karaman I, Erdoğan D, et al. Perforation of Meckel's diverticulum by a button battery: report of a case. *Surg Today* 2007;37(12):1115-6.
13. Willis GA, Ho WC. Perforation of Meckel's diverticulum by an alkaline hearing aid battery. *Can Med Assoc J* 1982;126(5):497-8.
14. Stokes DW Jr, Gregorie HB Jr. Perforation of Meckel's diverticulum by foreign body. *J S C Med Assoc* 1987;83(5):254-6.
15. Gregorie HB Jr, Herbert KH. Foreign body perforation of Meckel's diverticulum. *Am Surg* 1967;33(3):231-3.
Lin OS, Brandabur JJ, Schembre DB, et al. Acute symptomatic small bowel obstruction due to capsule impaction. *Gastrointest Endosc* 2007;65(4):725-8.