

Acanthosis Nigricans, Abnormal Facial Appearance and Dentition in an Insulin Resistance Syndrome

Ahya Zaridoust¹, MD; Ali Rabbani^{1,2}, MD; Fatemeh Sayarifard¹, MD; Christian T. Thiel³; Nima Rezaei^{1,4,5}, MD, PhD

1. Pediatrics Center of Excellence, Children's Medical Center, Tehran University of Medical Sciences, Tehran, Iran
2. Growth and Development Research Center, Tehran University of Medical Sciences, Tehran, Iran
3. Institute of Human Genetics, Friedrich-Alexander University Erlangen-Nuremberg, Germany
4. Molecular Immunology Research Center and Department of Immunology, Tehran University of Medical Sciences, Tehran, Iran
5. Research Center for Immunodeficiencies, Children's Medical Center, Tehran University of Medical Sciences, Tehran, Iran

Received: Apr 14, 2012; Accepted: Feb 23, 2013; Online Available: May 27, 2013

Abstract

Background: Insulin resistance syndromes are a heterogeneous group of disorders with variable clinical phenotypes, associated with increased blood glucose and insulin levels.

Case Presentation: Herein, a 10-year old girl with abnormal face and dentition is presented. She has suffered from diabetes mellitus type I since she was 6 years old. Hyperglycemia did not respond to age appropriate insulin dosage; therefore, insulin dosage was increased, but did not lead to appropriate glycemic control. Twenty two exons of insulin receptor gene (INSR), on short arm of chromosome 19, were sequenced, but no identifiable disease causing mutation was detected.

Conclusion: Although a rare mutation within the intronic or promoter region has not been excluded in this case, further molecular studies on patients with insulin resistance syndromes associated with certain features are needed.

Iranian Journal of Pediatrics, Volume 23 (Number 3), Jun 2013, Pages: 363-365

Key Words: Insulin Resistance Syndrome; Hyperglycemia; Gene; Mutation; Genetic Polymorphism

Introduction

Insulin resistance syndromes are a group of disorders with variable clinical spectrum, including extreme high insulin levels, glucose intolerance, and diabetes mellitus. Various endocrine and metabolic conditions have been reported in these syndromes, with distinct phenotypic characteristics in some cases^[1]. Syndromes associated with insulin resistant state, are Leprechaunism or Donohue's syndrome (abnormal facial appearance, early life growth retardation), Rabson-Mendenhall syndrome

(dental and nail abnormalities, skin lesions), Werner syndrome (features of premature aging), and Alstrom syndrome (childhood blindness, impaired hearing)^[2].

Abnormal facial appearance and dentition in association with insulin resistance resembles Rabson-Mendenhall syndrome (RMS) (OMIM #262190), an autosomal recessive disorder caused by mutation in the insulin receptor gene (INSR, OMIM*147670)^[3]. Growth and developmental delay, coarse facies, prognathism, gingival hypoplasia, premature and dysplastic dentition, enlarged genitalia, acanthosis nigricans,

* Corresponding Author;

Address: Children's Medical Center Hospital, Dr. Qarib St, Keshavarz Blvd, Tehran 14194, Iran

E-mail: rezaei_nima@tums.ac.ir

© 2013 by Pediatrics Center of Excellence, Children's Medical Center, Tehran University of Medical Sciences, All rights reserved.

www.SID.ir

lichenified skin, onychia, and hypertrichosis are some of the clinical manifestations observed in these patients^[1-4].

Herein, we present a patient with insulin resistance syndrome with the clinical diagnosis of RMS; however, molecular analysis of the INSR gene did not show any mutation.

Case Presentation

A 10-year old girl was referred to the Children's Medical Center, the pediatrics center of excellence in Iran, with history of poor-controlled diabetes mellitus since six years of age. The parents of this patient were first consanguine; the father is a 42-year old man with height of 175cm. Her mother is a 35-year old female with height of 152 cm. The patient has a 12-year old healthy brother. There was no history of diabetes mellitus or insulin resistance.

The patient had a history of low birth weight (2200 g); developed irritability at 22 days of age; the work-up performed at that time, showed hyperammonemia. Sodium benzoate was started, but no specific metabolic disease was diagnosed. Left renal cystectomy through laparotomy was performed at two months of age. She developed progressive abdominal protrusion; hepatomegaly and bilateral renal microlithiasis were revealed at one year of age, based on clinical and radiological evaluation, respectively. Hyperammonemia resolved, while benzoate therapy was stopped at six years of age. At that time, she suffered from polyuria, polydipsia, and dental decays. All of her

deciduous teeth were extracted after showing severe dental caries before the school age. Fasting blood sugar (FBS) was more than 350 mg/dl in repeated tests. The diagnosis of diabetes mellitus was made; consequently insulin treatment was started, but glycemic response was poor; so, insulin dosage was increased gradually, without salient effect on blood glucose level. She has been under insulin therapy (105-110 units) and metformin (1000 milligram per day) since 6 years, and 8 years old, respectively. In spite of such treatment, her FBS was always more than 350 mg/dl. The results of recent laboratory tests were as follow: Insulin >500 mU/L (normal range: 7-24 mU/L), Ca in 24 hrs urine: 92 mg (normal >4 mg/kg), oxalate: 54 mg (normal up to 35 mg/kg), HbA1c: 10.5 (normal up to 5.5).

The height was 115.5 cm (<3rd percentile) and the weight 20 kg (<3rd percentile) at the time of admission. Her blood pressure was 105/65 mmHg (50th-75th percentile) at that time. She had triangular face with prognathism, abnormal teeth formation, deep fissured large tongue and hair dandruff, posterior cervical and axillary acanthosis nigricans, shield chest and normal heart sounds (Fig 1). The liver border was palpable 4 cm below costal margin and spleen was just palpable. Sparse pubic hair was present without clitoromegaly. She had convex nails. There was no evidence of hearing loss. Except a delay in starting walking age (at two years old), her psychomotor development was normal. Only her growth was delayed in relation to chronologic age, but there was no evidence of muscular hypertrophy.

Abdominal magnetic resonance imaging (MRI) revealed large liver with increased signal density.

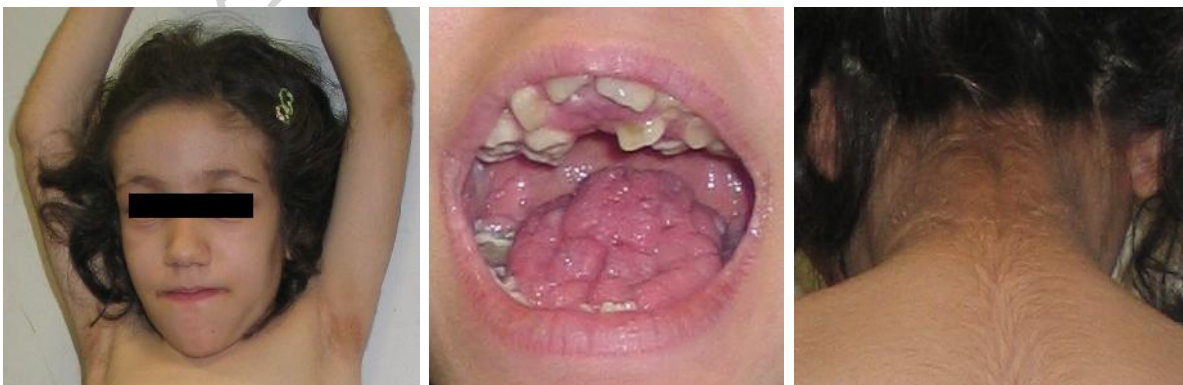


Fig. 1: Triangular face with prognathism, abnormal teeth, deep fissured large tongue and posterior cervical acanthosis nigricans

The head circumference was 51 cm. Brain MRI excluded pineal enlargement. Heart echocardiography showed tricuspid regurgitation, atrial septal defect and a hypertrophic right ventricle with appropriate systolic function. Insulin level was above 500 U/ml. Anti-insulin antibodies were negative. Liver function test was normal. Fasting blood sugar (FBS) was above 350 mg/dl. There were hyperoxaluria and hypercalciuria in 24 hours urine analysis. Glycosylated hemoglobin A1 (HbA_{1c}) was 10.5%.

Under the clinical hypothesis of RMS, 22 exons of insulin receptor (INSR) gene were sequenced. However, only 3 homozygous single nucleotide polymorphisms (SNPs) (c.5C>G, c.1230G>T and c.1650G>A), but no disease causing mutation was detected. Indeed being suspect to pigmented hypertrichosis with insulin dependent diabetes (PHID), the SLC29A3 [Solute Carrier Family 29 (Nucleoside Transporter), Member 3] gene was also sequenced which did not come up with any disease causing mutation.

Discussion

Rabson-Mendenhall syndrome is a rare insulin resistance disorder, which was first reported by Rabson and Mendenhall in 1956 in three siblings, who presented with cutaneous and skin abnormalities as well as phallic enlargement. Diabetes refractory to large doses of insulin, acanthosis nigricans and abnormal dentition are some other features of this syndrome^[4]. As RMS is the only insulin resistance syndrome with dental manifestations, this clinical diagnosis was most likely for our patient. Other insulin resistance syndromes, including Donohue's syndrome, Werner syndrome, and Alstrom syndrome, have different clinical phenotypes which were not compatible with this presented case.

She had coarse facial appearance from birth and dysplastic, late erupting teeth, extracted before school age. Hyperglycemia manifested at six years of age, when diabetes mellitus was diagnosed. She did not respond to age appropriate insulin dosage and therefore the diagnosis of an insulin resistance syndrome was confirmed. However, she did not have clitoromegaly, hypertrichosis, and

further molecular studies did not show INSR exons mutations, therefore not further substantiating the diagnosis of RMS. It should be noted that mutations in the INSR gene are not limited to the RMS; and mutations within this gene are usually associated with a spectrum of inherited insulin-resistance syndromes ranging from severe leprechaunism (Donohue syndrome) to type A insulin resistance^[1,5].

Analysis of 22 exons of INSR gene in our patient did not show any disease causing mutation and only 3 homozygous SNPs (c.5C>G, c.1230G>T and c.1650G>A) were identified. Although it might be possible that a very rare mutation is located within the intronic or promoter region, a new syndromic insulin resistance disorder could also be considered. Indeed, it seems that such dysmorphic phenotype is not always a valid parameter for predicting INSR mutations in insulin resistance condition^[5]. Although RMS seems to be the most likely clinical diagnosis for this case, it could be considered as an unusual and possibly even hitherto not yet described entity, or with RMS but not caused by INSR mutations.

Acknowledgement

This study was supported by grant no. 89-04-80-11945 from Tehran University of Medical Sciences and Health Services.

References

1. Parveen BA, Sindhuja R. Rabson-Mendenhall syndrome. *Int J Dermatol* 2008;47(8):839-41.
2. Moller DE, Flier JS. Insulin resistance--mechanisms, syndromes, and implications. *N Engl J Med* 1991; 325(13):938-48.
3. Bathi RJ, Parveen S, Mutalik S, et al. Rabson-Mendenhall syndrome: two case reports and a brief review of the literature. *Odontology* 2010;98(1):89-96.
4. Rabson-Mendenhall syndrome. No 262190: pineal hyperplasia, insulin-resistant diabetes mellitus and somatic abnormalities. Online Mendelian Inheritance in Man (OMM). Johns Hopkins University. Victor A Mckusick. <http://www.ncbi.nlm.nih.gov/entrez/dispomim.cgi?id=262190>. Access date: Apr 06, 1986.
5. Thiel CT, Knebel B, Knerr I, et al. Two novel mutations in the insulin binding subunit of the insulin receptor gene without insulin binding impairment in a patient with Rabson-Mendenhall syndrome. *Mol Genet Metab* 2008; 94(3): 356-62.